620

ANNALS OF SURGERY

Vol. 202 December 1985 No. 6

★ ★ ★ ★ ★ Centennial Contribution

Combined Transplantation of the Heart and Liver

BYERS W. SHAW, JR., M.D., HENRY T. BAHNSON, M.D., ROBERT L. HARDESTY, M.D., BARTLEY P. GRIFFITH, M.D., THOMAS E. STARZL, M.D.

From the Department of Surgery, University of Pittsburgh School of Medicine, Pittsburgh, Pennsylvania

The technique of combined transplantation of the heart and liver is described and illustrated, emphasizing modifications that were used in a successful case. Two other unsuccessful attempts are reported, and the importance of relative size of donor and recipient is discussed. There may be an immunological advantage to transplanting two organs in combination from the same donor.

CARDIAC TRANSPLANTATION and hepatic transplantation have each become established as therapeutic procedures, and the techniques of each operation have been nearly standardized and widely practiced.[1-3] The occasion arose recently to combine these two procedures on the same patient. In this report, we describe details of the operation and the modifications required when the two procedures are combined.

The patient was a 6¾ year old girl who had been extensively studied at the University of Texas, Southwestern Medical School, in Dallas. She suffered from homozygous familial hypercholesterolemia, the first evidence of which had been progressive development of xanthomas on the contact areas of her buttocks and extremities at the age of 3 months. Her disease progressed rapidly after her first admission for studies in Dallas in September 1983. In October, she developed angina pectoris, suffered an apical myocardial infarct followed by pulmonary edema, and required prolonged ventilatory support. Arteriography demonstrated stenosis of the left main coronary artery, which was treated in Dallas by a double coronary artery bypass. She subsequently had a persistent murmur of mitral regurgitation suggestive of papillary muscle dysfunction. Consideration was given to the possibility of hepatic transplantation with the belief that the hypercholesterolemia was secondary to a paucity of low density lipoprotein receptors in the patient's liver that might be corrected by a normal liver.

In the meantime, angina pectoris recurred, and repeat coronary arteriography showed the bypass to the circumflex artery to be occluded. A repeat bypass was done to this artery, and when she could not be weaned from cardiopulmonary bypass, the mitral valve was replaced. Recurrence of angina pectoris several weeks later led to the conclusion that the only realistic option required replacement of both liver and heart, and the patient was transferred to Children's Hospital and the University Health Center of Pittsburgh where operation was performed on February 13 and 14, 1984.

Donor Procedure

The donor, aged 4½ years, weighed 3 kg less (at 16.5 kg) than the recipient and was blood type O. The recipient was type A. There was a mismatch at HLA A, B, and D_2 loci. Techniques for the combined procurement of mul-

Reprint requests: Henry T. Bahnson, M.D., Chairman, Department of Surgery, University of Pittsburgh School of Medicine, 1084 Scaife Hall, Pittsburgh, PA 15261.

Submitted for publication: May 20, 1985.

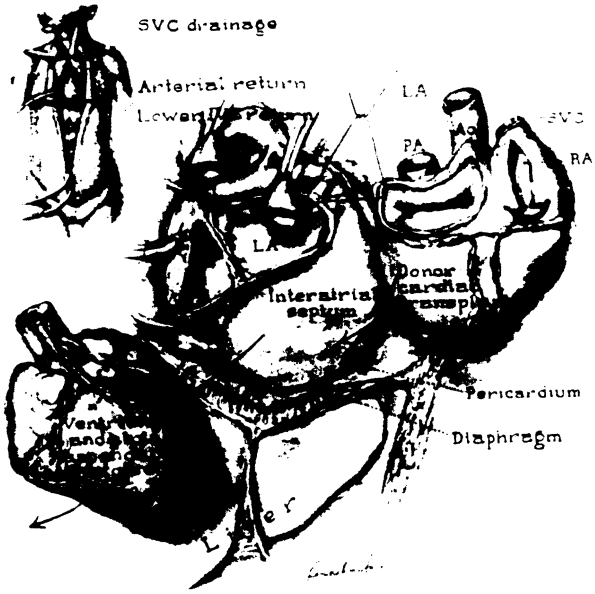

FIG. 1. Beginning of cardiac implantation. Note cannulation of iliac veins and artery for cardiopulmonary bypass.

tiple organs from the same donor have been extensively outlined in previous reports.[4-6] Dissection of the liver and kidneys was performed first, followed by dissection of the heart and great vessels. After this was completed, cannulas were inserted into the donor's splenic vein, distal abdominal vena cava, and aorta. Precooling of the liver was then begun by infusion of cold Ringer's lactate solution through the splenic vein cannula. As this was begun, the distal ascending aorta was clamped, and a cold cardioplegic solution of electrolytes was infused through a cannula in the ascending aorta. Almost simultaneously, cold (4 C) EuroCollins solution was infused through the abdominal aortic cannula, and the inferior vena caval cannula was opened and blood allowed to drain into a container placed on the floor. The heart was removed, followed by the liver and then the kidneys. The heart and liver were promptly immersed in iced Ringer's lactate solution containing crushed ice and transported to Children's Hospital of Pittsburgh, arriving there 90 minutes after the aorta had been clamped.

Recipient Procedure

The beginning of the recipient procedure was timed in such a way that all of the necessary dissection in preparation for removal of the recipient's heart and liver could be accomplished before the arrival of the donor organs. A relatively easy hepatectomy was anticipated in the absence of a previous abdominal operation or of portal hypertension. Removal of the heart, on the other hand, was correctly predicted to be more tedious because of the child's multiple previous operations. The hepatic and cardiac portions of the operation were done by the respective surgical teams.

Approximately 3 hours before the estimated time of arrival of the donor team, the abdomen was opened through a midline incision extending from the xyphoid nearly to the pubis. The hilar dissection of the liver was followed by complete division of the supporting ligaments of the liver as well as mobilization of the entire retrohepatic vena cava. The recipient had a large right hepatic artery arising from the superior mesenteric artery and coursing posterior to the portal vein. The celiac axis provided a large branch to the left lobe of the liver.

After completion of the abdominal dissection, the chest was opened through a midline sternotomy. Many diffuse adhesions were present. The right common iliac artery was selected as the site of cannulation for arterial return from the pump oxygenator because the ascending aorta had been cannulated twice previously and had two coronary artery bypass grafts arising from it. The iliac artery was severely atheromatous and sclerotic; the ascending aorta was later seen to be greatly thickened with soft atheroma. Venous cannulation was through the sinus venosus to the superior vena cava with a second cannula inserted through the left common iliac vein to the inferior vena cava. The patient was cooled to 28 C on cardiopulmonary bypass as the remaining adhesions were divided. When the donor team arrived, the recipient's heart was removed by excising the ventricles and atrial appendages. The ascending aorta was divided, and the venous bypass grafts were trimmed. The pulmonary artery was divided just distal to the valve.

The back wall of the donor left atrium was removed by incisions joining the pulmonary veins (Fig. 1). The left atria, right atria, and aortas of the donor and recipient were then serially anastomosed with continuous sutures or Prolene® (Fig. 2). Cold blood cardioplegia was instilled after completion of the left atrial and after the right atrial anastomoses, and iced saline was frequently flushed over the heart. Flow was restored to the heart approximately 150 minutes after the donor aorta had been clamped. The left ventricle was vented through the left atrial appendage, and the pulmonary arteries were then anastomosed (Fig. 3). The patient was then rewarmed, and cardiac action returned gradually. Once function of the new heart was satisfactory, but with the patient still on bypass, the cardiac team withdrew and the liver transplantation was begun.

The patient's liver was removed by sequentially clamping and dividing the hepatic artery, portal vein, and inferior vena cava above and below the liver. A cannula was placed in the portal vein, and venous drainage was siphoned to the pump oxygenator (Fig. 4). In the usual sequence, the suprahepatic vena caval anastomosis was followed by that of the infrahepatic vena cava (Fig. 5).

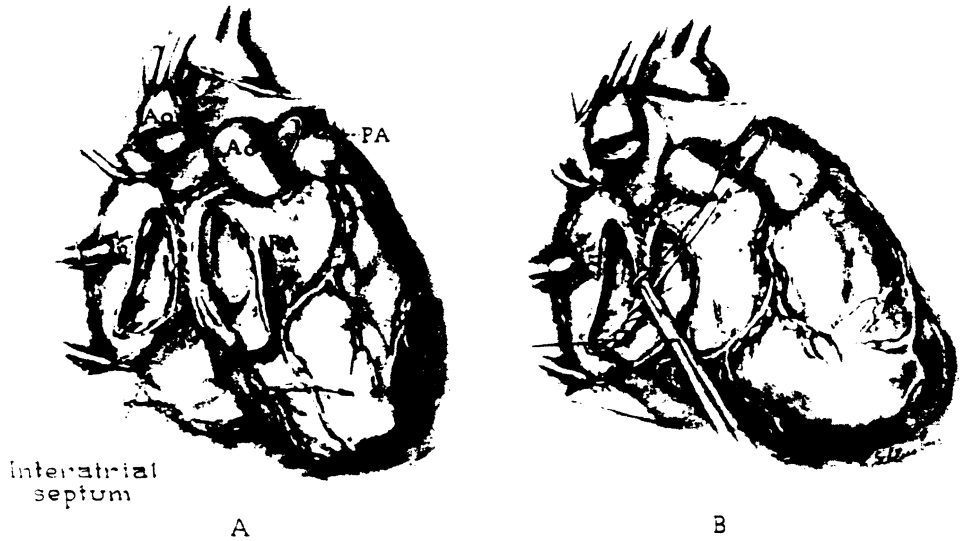

FIGS. 2A and B. Completion of left (*A*) and then right (*B*) atrial anastomoses. Cardioplegic solution was infused on completion of each anastomosis. The heart was frequently bathed with iced saline.

The liver was flushed with approximately 200 milliliters of cold lactated Ringer's solution through the portal vein cannula to remove potassium from the liver and to evacuate air from the intrahepatic vena cava. This flush solution was allowed to exit through the open infrahepatic vena cava just prior to completion of that anastomosis. The hepatic arterial anastomosis was made next between the end of the celiac axis of the donor just at its origin from the aorta and the end of the celiac axis of the recipient just proximal to the takeoff of the splenic and left gastric arteries (Fig. 6). The portal bypass was then discontinued and the portal vein was anastomosed end-to-end. Cardiopulmonary bypass offered the special advantage of drainage and decompression of the portal vein during completion of the first three vascular anastomoses. Arterial and portal flow were simultaneously restored to the liver following completion of the portal venous anastomosis approximately 3½ hours after devascularization of the liver in the donor. After hemostasis in the various anastomoses of the liver was complete, cardiopulmonary bypass was discontinued. Its duration was 135 minutes.

The coagulopathy attending the addition of heparin for cardiopulmonary bypass in continuation with liver transplantation required several hours to reverse. During this

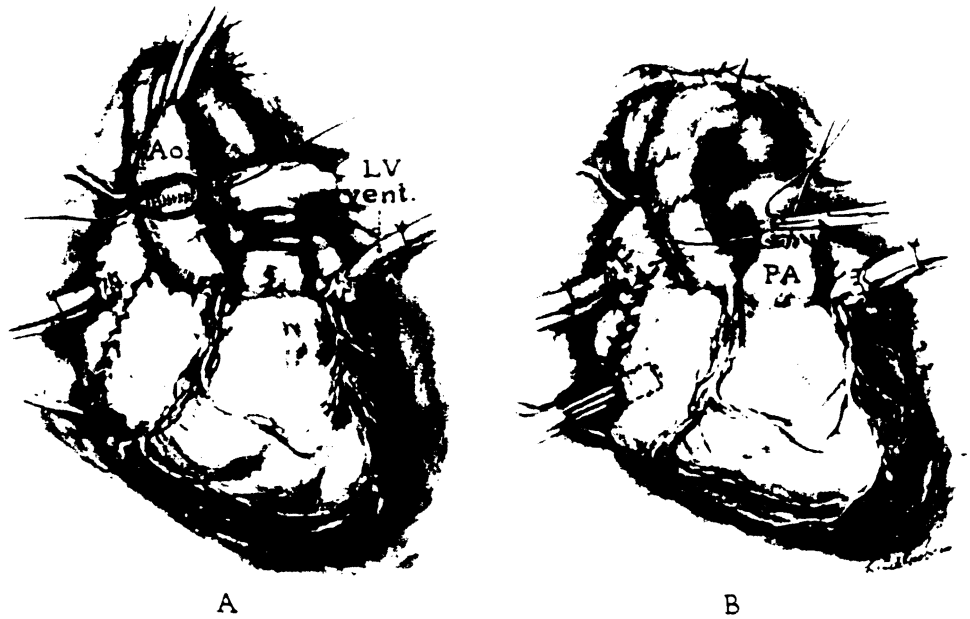

FIGS. 3A and B. *A*. Completion of aortic anastomosis following which arterial flow was restored and then the pulmonary arteries were anastomosed. *B*. Venting the right atrium facilitated the pulmonary anastomosis.

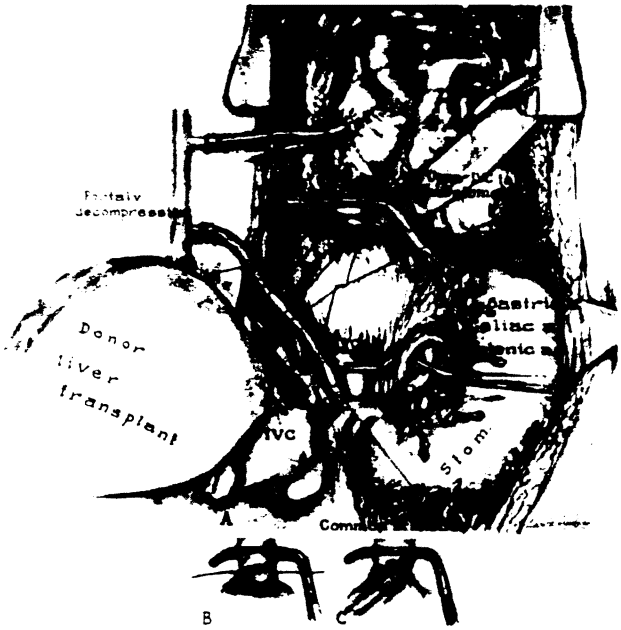

FIG. 4. Inferior vena caval anastomosis and implantation of the liver while cardiopulmonary bypass continued and the portal vein was drained.

interval, most attempts at surgical correction of bleeding were minimally helpful, but eventually coagulation returned to normal. At this time, because of what appeared to be a slight stricture of the arterial anastomosis, it was taken down and redone.

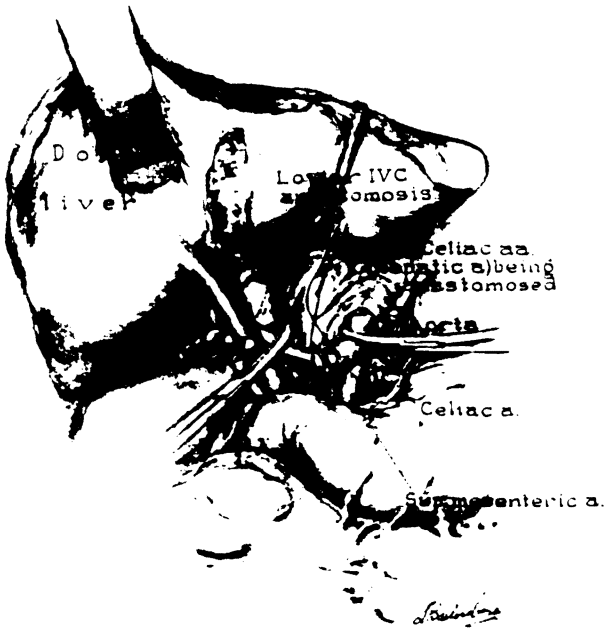

FIG. 5. Anastomosis of celiac arteries while portal vein was drained to the machine. Portal vein drainage was then stopped, and portal anastomosis was done.

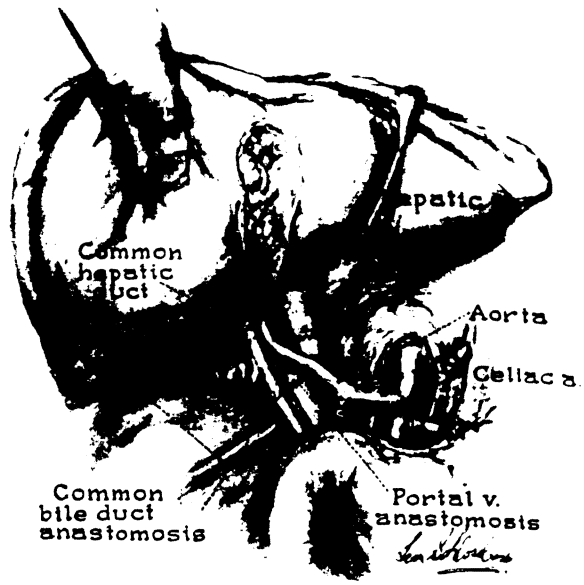

FIG. 6. Completion of common duct anastomosis with T-tube drainage.

Finally, the bile duct was reconstructed with an end-to-end anastomosis between the two common ducts (Fig. 6). A number 8 F T-tube was used as a stent, with the long end of the tube being brought out through a stab wound in the anterolateral aspect of the recipient's common bile duct. An operative T-tube cholangiogram was normal.

The total operating time was approximately 15 hours. At the end of the operation, cardiac and hepatic functions were thought to be quite good by both surgical teams. The patient required minimal inotropic support. The liver was making large quantities of good quality bile, and the patient's coagulation had returned to normal.

Hospital Course

She was exquisitely dependent on catecholamines early after operation. The initial doses of 5 μg/kg of dopamine and 7.5 μg/kg of dobutamine per minute were supplemented with a calcium chloride drip at 1.5 mg/min, which she seemed to need. The need for inotropic drugs diminished rapidly, and these were discontinued by 48 hours after surgery. Cardiac pacing was intermittently used for 48 hours before sinus rhythm became persistent.

Cyclosporine and steroids were used for immunosuppression. Figure 7 shows the schedule of these drugs and blood cyclosporine levels following transplantation. The patient had been pretreated with oral cyclosporine at a dose of 175 mg/day (11.3 mg/kg) starting on January 9, 1984. Intravenous cyclosporine, 6 mg/kg daily in two divided doses, was started on the day of operation, and the dose was adjusted thereafter to obtain a 12 hours. whole blood trough level of around 1000 ng/ml as mea-

sured by radioimmunoassay. Oral cyclosporine was reinstituted three days after operation, when ileus had resolved, at a dose of 15 mg/kg daily. During surgery, 500 mg of methylprednisolone succinate was given intravenously at the time circulation was restored to the donor heart. Thereafter, methylprednisolone succinate was given intravenously, or prednisone was given orally as soon as it was tolerated. The initial daily dose of 100 mg/d was reduced by 10 mg each day to 30 mg/d at the end of the first week, and 20 mg/d at the end of the second week (Fig. 7). Because of a rise in the serum transaminase on the second postoperative day, a bolus of 500 mg methylprednisolone succinate was given. A second bolus of 1 g hydrocortisone was given on the seventh postoperative day because of a rise in the bilirubin on two successive days.

Serum transaminase levels became normal by the eighth postoperative day, and the bilirubin fell rapidly thereafter (Figure 7). Cardiac function appeared to be normal throughout the hospital course following the initial brief stay in the intensive care unit. Endomyocardial biopsy, which is done weekly in other patients following cardiac transplantation, was performed only once in this case, on the 18th postoperative day and then because of evidence of edema on echocardiograms. This biopsy showed mild myocytolysis, a minimal round cell infiltrate with some polymorphonuclear leukocytes and extravascular red blood cells. It was interpreted as resolving rejection. Hepatic function was otherwise used to monitor rejection, and, in the absence of clinical or laboratory signs of rejection of the hepatic allograft, aggressive treatment of rejection was not undertaken. Cardiac index at the time of biopsy was 3.5 and 4.0 L/min · M^2 and pulmonary artery pressure was 28/18 mmHg with a pulmonary wedge pressure of 12 to 15 mmHg.

The patient was discharged from the hospital on the 28th day following transplantation. She has remained well with no clinically or chemically evident episodes of rejection or other signs of deterioration of function of either graft for over 12 months. Maintenance immunosuppression presently consists of 7.5 mg of prednisone and 300 mg of cyclosporine per day. She has continued to gain weight and grow.

Improvement in the patient's cholesterol and triglyceride levels are the subject of another report.[7] Before transplantation, the average plasma cholesterol concentration was more than 1000 mg/dl (normal <195 mg/dl). Her total plasma triglycerides were less dramatically elevated in the 230 mg/dl range (normal <150 mg/dl). These values were obtained while the child was on an isocaloric diet consisting partly of formula and partly of solid food containing less than 40% of the calories as fat and less than 300 mg of cholesterol daily. Following replacement of the liver, cholesterol levels fell immediately to less than

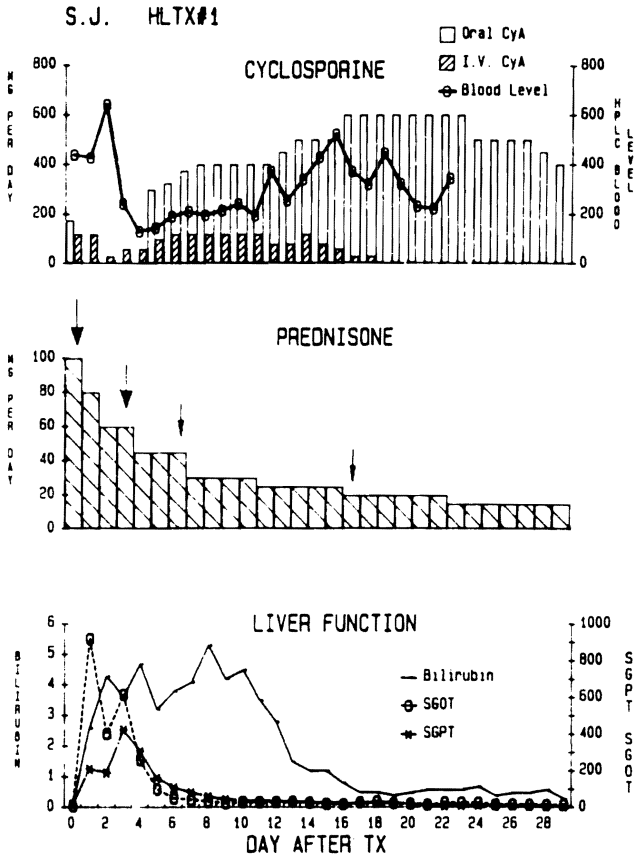

FIG. 7. Clinical course following heart and liver transplantation. Large arrows indicate methylprednisolone succinate 500 mg I.V. boluses, small arrows 1000 mg hydrocortisone I.V. boluses.

200 mg/dl, but then gradually increased as the patient began to eat an unrestricted diet. Plasma cholesterol levels eventually leveled off around 250–275 mg/dl and total triglycerides have remained in the low 200 mg/dl range. Multiple tendinocutaneous xanthomas that were visible on the skin have undergone frank regression, having become flattened and turning from yellow to pink.

A similar procedure was performed unsuccessfully on two subsequent occasions. One involved a 2 year old girl weighing 7.2 kg with end stage cardiomyopathy and biliary hypoplasia. The procedure was similar to that described above except that, because of her small size, it was more difficult, and instead of the iliac vein, the inferior vena cava was cannulated near the bifurcation. She was kept cold until the liver was implanted. The donor was younger but weighed 7.2 kg. The patient's condition immediately after operation was satisfactory, but she soon showed evidence of low cardiac output and acidosis in spite of inotropic drugs and use of an intra-aortic balloon pump. Retransplantation of the heart was performed 24 hours later from a donor weighing 18 kg. There appeared to be necrosis of the dome of the liver. She improved initially but died soon afterwards.

The other procedure was on a 17 year old girl with familial hypercholesterolemia who previously had undergone portacaval shunt in 1974. In 1976, the aortic valve was replaced, the adjacent aorta was patched with Dacron®, two coronary artery bypass grafts were sewn to the patch, and the mitral valve was replaced. In 1978, she developed bacterial endocarditis for which she was treated and later had a periprosthetic leak repaired. The prosthetic valve was replaced with a larger one in 1981. All of the cardiac operations had been done at Fort Worth Children's Hospital. Angina had recurred, and she was severely limited in activity. She weighed 54.5 kg; the donor weighed 78.2 kg. The donor heart was slightly smaller than the dilated heart of the recipient. The liver did not appear large for the recipient. After surgery, the chest was reopened twice when there seemed to be compression of the heart; there was transient improvement each time. At the second re-exploration, the sternum was left open, and only the skin was closed. Serial electrocardiograms showed evidence of an inferior wall infarction. Because the liver had swelled and seemed to be contributing to the compression, the left lobe of the liver was resected. There was central lobular necrosis in the specimen, and, when another donor became available, decision was made to retransplant. This was done, but she could not be removed from cardiopulmonary bypass. Lymphocytes from the first donor and recipient serum did not match, the crossmatch being done during implantation. Histological examination of the first donor heart when it was removed at retransplantation showed focal necrosis characteristic of ischemia without evidence of rejection.

In complex cases such as these, it is difficult to pinpoint the causes of failure, but the size of donor organs appeared significant. In the 2 year old girl, the initial donor heart seemed small for the load. The donor was younger but weighed the same as the recipient. When retransplant of the heart was performed, the patient's condition had deteriorated too much. Discrepancy in size was more clearly detrimental after operation in the last case. Although size of the organs seemed appropriate at the time of implantation, with subsequent swelling and with a modicum of pericardial clot, the heart was clearly compressed, which in turn caused further damage and swelling of the liver.

When the two organs are individually transplanted, one would desire a donor heart slightly larger than the recipient's but a liver slightly smaller. When the procedures are combined, a compromise must be made, usually accepting a larger donor than recipient.

Discussion

Techniques for transplantation of either the liver or the heart have become relatively standard. The transplantation of both of these organs from one donor into a single recipient was accomplished by simple combination of these methods. The patient was placed on cardiopulmonary bypass, and the cardiac transplantation was carried out first. The hepatic transplantation was not undertaken until the cardiac team was satisfied with cardiac action and appearance. Hepatic replacement was done with the patient still on bypass and with the added advantage of portal vein decompression. Hepatic transplantation in the present case was undertaken to correct a metabolic disorder and not to replace a failing liver. The patient had not had previous abdominal surgery and did not have portal hypertension. Consequently, the abdominal dissection was done rapidly and with little blood loss.

Previous work in animals has shown that transplantation of either the liver or the spleen from the same donor provides an advantage of less severe and less frequent episodes of rejection.[8,9] In addition, when rejection does occur, it might be expected to occur simultaneously in both organs, each organ thus providing clues for the diagnosis of rejection. In the present case, this latter expectation justified avoidance of frequent endomyocardial biopsies, a technique widely used to monitor for rejection following cardiac transplantation. Except for delay in the fall of the bilirubin and a transient rise in serum transaminase levels during the first 10 days following transplantation, the patient showed no other signs of frank rejection of the liver. Despite the fact that the endomyocardial biopsy taken 18 days after operation showed signs of rejection, it was not aggressively treated in the absence of clinical signs of rejection of the liver. In this case, this approach proved successful.

References

1. Starzl TE, Iwatsuki S, Shaw BW Jr. Transplantation of human liver. *In* Schwartz SI, Ellis H, eds. Maingot's Abdominal Operations. Norwalk, CT: Appleton-Century-Crofts, 1985; 1687–1722.
2. Starzl TE, Iwatsuki S, Shaw BW Jr. Technique of liver transplantation. *In* Blumgart LH, ed. Surgery of the Liver and Biliary Tract. Edinburgh: Churchill Livingston, 1985 (in press).
3. Baumgartner WA, Reitz BA, Oyer PE, et al. Cardiac homotransplantation. Curr Probl Surg 1979; 16:51.
4. Shaw BW Jr, Hakala T, Rosenthal JT, et al. Combination donor hepatectomy and nephrectomy and early functional results of allografts. Surg Gynecol Obstet 1982; 155:321–325.
5. Shaw BW Jr, Rosenthal JT, Griffith BP, et al. Techniques for combined procurement of heart and kidneys with satisfactory early function of renal allografts. Surg Gynecol Obstet 1983; 157:261–264.
6. Starzl TE, Hakala TR, Shaw BW Jr, et al. A flexible procedure for multiple cadaveric organ procurement. Surg Gynecol Obstet 1984; 158:223–230.
7. Starzl TE, Bilheimer DW, Bahnson HT, et al. Heart-liver transplantation in a patient with familial hypercholesterolemia. Lancet 1984; 1:1382–1383.
8. Calne RY, Sells RA, Pena JR, et al. Induction of immunological tolerance by porcine liver allografts. Nature 1969; 223:472.
9. Rosner BJ, Kamada N, Zimmerman F, et al. Immunosuppressive effect of experimental liver allografts. *In* Calne RY, ed. Liver Transplantation. London: Grune and Stratton, 1983; 35–54.