

# Orthotopic Liver Transplantation for Primary Sclerosing Cholangitis

829

J. WALLIS MARSH, JR., M.D., SHUNZABURO IWATSUKI, M.D., LEONARD MAKOWKA, M.D., PH.D., CARLOS O. ESQUIVEL, M.D., PH.D., ROBERT D. GORDON, M.D., SATORU TODO, M.D., ANDREAS TZAKIS, M.D., CHARLES MILLER, M.D., DAVID VAN THIEL, M.D., and THOMAS E. STARZL, M.D., PH.D.

The incidence or diagnostic rate of sclerosing cholangitis is increasing. Because of the lack of effective medical or surgical therapy for patients with end-stage liver disease and sclerosing cholangitis, results with orthotopic liver transplantation were examined. The results of 55 consecutive liver replacements for this disease were reviewed. The 1- and 2-year actuarial survival rates are 71% and 57%, respectively. Orthotopic liver transplantation for end-stage liver disease from sclerosing cholangitis has emerged as the most effective therapy.

From the Department of Surgery, University Health Center of Pittsburgh, University of Pittsburgh, and the Veterans Administration Medical Center, Pittsburgh, Pennsylvania

**S**CLEROSING CHOLANGITIS is an enigmatic disease usually found in men younger than 50 years and, more often than not, is associated with inflammatory bowel disease, particularly ulcerative colitis. The treatment modalities used for this disease have been as varied as the descriptions of the disease itself and illustrate the dissatisfaction with the currently available medical/surgical therapies. Although the histologic course of sclerosing cholangitis is considered benign, the disease most often takes an indolently malignant course and is, in fact, a pernicious disease. Importantly, there is an apparent increasing incidence, or at least an increasing diagnostic rate, of the disease in most developed countries.

We report our experience with hepatic replacement in 55 patients who had primary sclerosing cholangitis as the indication for liver transplantation. We have tried (1) to determine the applicability, success rate, and survival of orthotopic liver transplantation for patients with

primary sclerosing cholangitis, (2) to determine the recurrence rate of sclerosing cholangitis, should it occur, and (3) to assess the course of the associated inflammatory bowel disease under immunosuppression after liver transplantation.

## Case Material and Methods

Between January 1, 1980, and June 30, 1986, 604 primary orthotopic liver transplants were performed at the University of Colorado Health Science Center (through 1980), the University Health Center of Pittsburgh (since 1981), and the Pittsburgh-affiliated Baylor University Medical Center at Dallas (since 1985). All patients were treated with combination prednisone-cyclosporine therapy as has been described elsewhere.<sup>1-3</sup> Patients were considered to have "primary" sclerosing cholangitis<sup>4-7</sup> when there were (1) typical cholangiographic findings of the disease, (2) pathologic confirmation of the disease from the total hepatectomy specimen, and (3) the absence of a history or pathologic evidence consistent with secondary biliary cirrhosis from other causes.

Fifty-five patients received orthotopic liver transplantation for end-stage primary sclerosing cholangitis. Thirty-five were male (63.6%) and twenty were female (36.4%). Their ages ranged from 15 to 58 years with a median age of 36 years. Only four patients were older than 50 years.

The indications for transplantation were persistent or recurrent variceal bleeding in 27.2% (15 of 55 patients),

Supported by Research Project Grant No. AM-29961 from the National Institutes of Health, Bethesda, Maryland. L.M. is the recipient of a Centennial Fellowship from the Medical Research Council of Canada.

Reprint requests: Thomas E. Starzl, M.D., Department of Surgery, 3601 Fifth Avenue, Room 218 Falk Clinic, Pittsburgh, PA 15213.

Submitted for publication: June 8, 1987.

TABLE 1. Biliary and Intestinal Operations before Orthotopic Liver Transplantation

	No. of Patients
Hepaticojejunostomy	15
Cholecystectomy	6
T-tube drainage of the choledochus	5
Cholecystectomy and percutaneous choledochal drainage	3
Choledochoduodenostomy	1
Cholecystojejunostomy	1
Distal splenorenal shunts without prior biliary tract surgery	2
Partial or total abdominal colectomy	4
Proctocolectomy with ileostomy	3
Small bowel resection (Crohn's disease)	1

ascending cholangitis in 27.2% (15 of 55 patients), or hepatic decompensation, including encephalopathy, coagulopathy, anorexia, ascites, fatigue, pruritus, and/or 3-4+ varices, in 45.5% (25 of 55 patients). Because of the risk of cholangiocarcinoma, the timing of transplantation cannot be accurately defined. In general, however, transplantation is encouraged when the bilirubin level exceeds 10 mg/dl or is rapidly rising, when the patient's lifestyle has begun to significantly deteriorate, or with any suspicion of cholangiocarcinoma.

Thirty-six (65.4%) of 55 patients had a history of inflammatory bowel disease. Thirty-two patients had ul-

cerative colitis, and four patients had Crohn's disease. Cholangiocarcinoma was found in the hepatectomy specimen of five patients (9%). Three of 55 patients had had a carcinoma of the right colon removed by radical right colectomy, 11, 4, and 4 years, respectively, before liver transplantation without evidence of recurrence.

Thirty-one (56.3%) of 55 patients had undergone prior biliary tract surgery for diagnosis or treatment of the sclerosing cholangitis (Table 1). Fifteen patients had undergone hepaticojejunostomy, six had cholecystectomy alone, five had T-tube drainage of the choledochus, three had cholecystectomy and percutaneous choledochal drainage, one had choledochoduodenostomy, and one had cholecystojejunostomy.

Eight patients (14.5%) had undergone prior bowel surgery for either inflammatory bowel disease or for complicating carcinoma. Three patients had undergone partial or total abdominal colectomy. Two of the three patients had proctocolectomy with ileostomy, and one patient had proctocolectomy with an ileoanal pullthrough. A fourth patient had undergone a small bowel resection for Crohn's disease.

The liver disease was diagnosed 1-16 years (mean: 5.8 years) before transplantation, and the bowel disease, when present, had existed from 2 to 29 years (mean: 14.8 years). In all but five of the 36 cases with coexisting inflammatory bowel disease, the bowel disease preceded the sclerosing cholangitis.

## Results

### Survival

As of September 1, 1986, there were 37 patients living (67%) and 18 dead (33%) with a mean follow-up period of 19 months (range: 4-46 months). The actuarial survival rates at 3, 6, 9, 12, 24, and 36 months were 80%, 76%, 76%, 71%, 57%, and 57%, respectively, calculated by the life table analysis of Kaplan-Meier. (Fig. 1). The longest surviving patient who had transplantation for primary sclerosing cholangitis has been observed for 46 months.

### Cause of Death

Eleven patients died within 3 months of transplantation, all from direct complications of transplantation or the associated immunosuppression. Technical failures, primary nonfunction of the graft, infectious complications, and irreversible acute rejection were the leading causes of death. Two patients died between 3 and 6 months, one of graft failure and sepsis, and another of biliary sepsis due to recurrence of cholangiocarcinoma. Between 6 and 12 months one patient died of an unrecognized lymphoproliferative disorder. Three patients

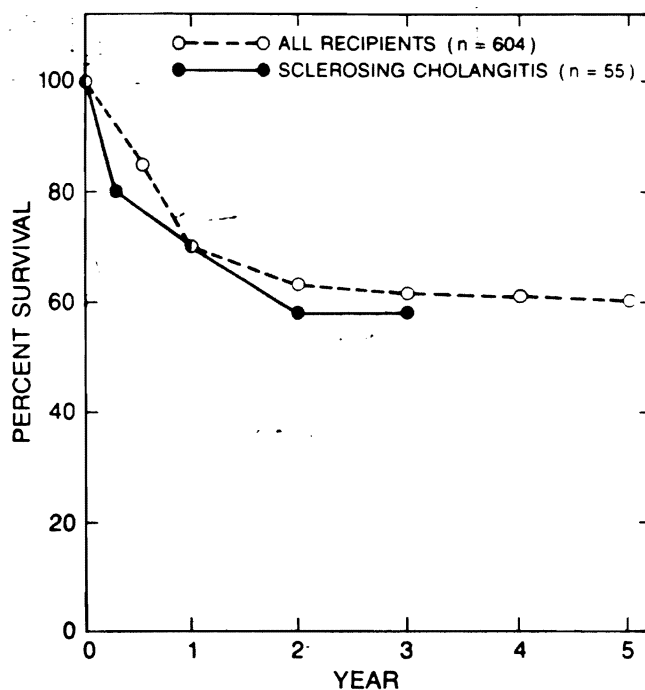


FIG. 1. Actuarial survival after orthotopic liver transplantation.

TABLE 2. Causes of Death after Orthotopic Liver Transplantation

Time of Death after Transplant	No. of Deaths	Cause of Death
0-3 months	11 patients (19 transplants)	Nine deaths related directly to graft failure: cause of graft failure (including retransplantation) primary nonfunction 7 technical failure 3 acute rejection 4
3-6 months	1 patient	Two deaths related to immunosuppression intra-abdominal abscess 1 cryptococcal meningitis 1
6-12 months	1 patient	Graft failure and sepsis
1-2 years	1 patient	Biliary sepsis and recurrent cholangiocarcinoma
2-3 years	1 patient	Unrecognized lymphoproliferative disorder
>3 years	1 patient	Recurrent cholangiocarcinoma
	1 patient	Systemic fungal infection
	1 patient	GI bleeding and liver failure from portal vein thrombosis
	No deaths	
	1 patient	Chronic rejection

died between 1 and 2 years, one of recurrent cholangiocarcinoma, one of systemic fungal infection, and the other of gastrointestinal bleeding and liver failure due to rethrombosis of the portal and superior mesenteric veins which had been opened with thrombophlebotomy at the time of transplantation. No patient died between 2 and 3 years after transplantation. One patient died of liver failure due to chronic rejection more than 3 years after transplantation (Table 2).

#### Unrecognized Cholangiocarcinoma

Previously unrecognized cholangiocarcinoma was found in the surgical specimen of five of the 55 patients. There were three women and two men with an average age of 35.4 years (range: 24-37 years). Two patients had no history of inflammatory bowel disease; three had had ulcerative colitis for 16, 20, and 29 years. The patient who had had ulcerative colitis for 16 years had undergone a right colectomy 4 years before liver transplantation for a Duke's B carcinoma of the colon with no evidence of recurrence. The clinically evident liver disease in this subset of patients had been present 1, 2, 4, 7, and 14 years, clearly illustrating that longstanding liver disease is not a prerequisite for the development of cholangiocarcinoma. Two of these patients died as a result of recurrent cholangiocarcinoma 4 and 12 months after transplantation. Three patients are alive, but the follow-up period is short. The first patient still living is 1 year post-transplantation, received adjunctive chemotherapy and radiotherapy, but has recurrence of disease. The remaining two patients are 3 months post-transplant without evidence of recurrence: both have undergone radiotherapy and one will undergo chemotherapy as well.

#### Inflammatory Bowel Disease after Liver Transplantation

During the observation period of 4 months to 4 years, nine (34.5%) of 26 patients who had had inflammatory bowel disease before transplantation and who survived more than 3 months after transplantation developed reactivation or exacerbation of the bowel disease. However, the recurrent inflammatory bowel disease was minimally symptomatic in seven of the nine patients, requiring only short-term treatment with sulfasalazine, and was moderate in two of nine patients, requiring long-term sulfasalazine therapy and increased doses of steroids.

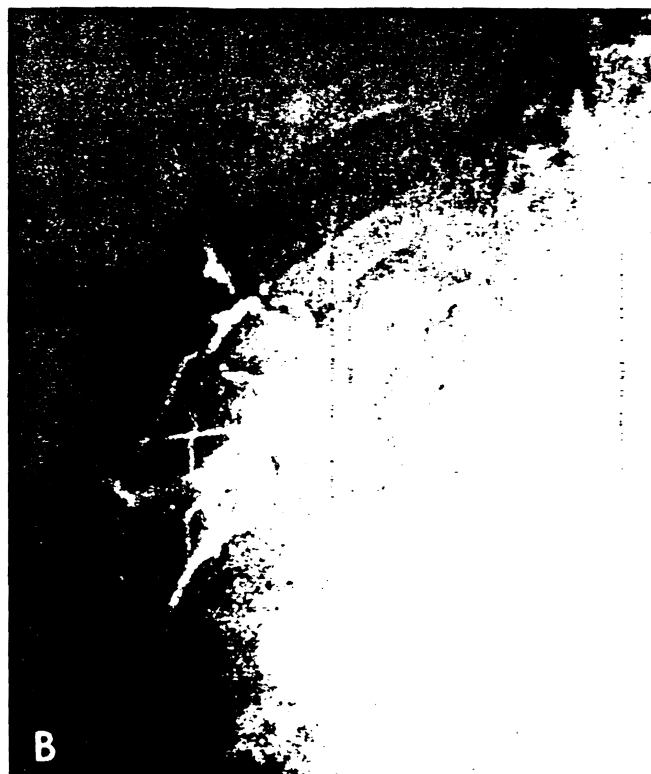Annual or semiannual colonoscopic examinations of the surviving patients have not detected any colorectal malignancy during this relatively short period of observation, but in none of the patients with pre-existing abnormalities have the colonoscopic findings become totally normal. It is also noteworthy that none of the patients without a pre-existing history of inflammatory bowel disease has developed it after transplantation.

#### Recurrence of Sclerosing Cholangitis

In one patient, chemical and radiological abnormalities developed in the graft compatible with sclerosing cholangitis 1 year after transplantation (Fig. 2A), but the abnormalities have been stable for the ensuing year. Four patients whose original liver disease was not sclerosing cholangitis also had similar abnormalities develop after histologically proven graft rejection (Fig. 2B).

#### Discussion

Primary sclerosing cholangitis remains a disease of unknown cause. It has become the third most common



FIGS. 2A and B. *A.* Cholangiogram showing changes of sclerosing cholangitis 1 year after transplantation. The original diagnosis was sclerosing cholangitis. *B.* Cholangiogram showing changes of sclerosing cholangitis in a patient with a >90% stenosis of the hepatic artery and after multiple biopsy-proven rejections. The original diagnosis was chronic active non-A, non-B hepatitis.

indication for orthotopic liver transplantation in adults, the first being postnecrotic cirrhosis and the second being primary biliary cirrhosis. Treatment has been attempted with steroids, cholestyramine, azathioprine, D. penicillamine,<sup>8</sup> choledochoenteric anastomoses,<sup>9</sup> and choledochal drainage by T-tube or Silastic® transhepatic stents.<sup>10</sup>

Wiesner and LaRusso,<sup>11</sup> have reported the largest group of patients with primary sclerosing cholangitis treated without transplantation at a single institution. Thirty-nine (78%) of their 50 patients had adequate follow-up for presentation. Thirteen (33%) of the 39 patients were dead after a mean interval of 57 months after diagnosis. At the time of reporting, 26 patients (66%) were alive, but 12 had end-stage liver disease. Thus, an unsatisfactory result had been obtained in at least 64% of the cases.

Cameron et al.,<sup>10</sup> have reported the operative placement of Silastic transhepatic stents in a group of 11 patients. Eleven of the original 22 patients were not selected for operation, and of those operated on the majority have either died or come to transplantation, including three patients treated by us. The prior performance of this type of operation has made transplantation exceptionally difficult.

The fact that a satisfactory result could be obtained in two thirds of the 55 patients herein reported after a mean follow-up of more than 1.5 years is encouraging. All patients were medical/surgical treatment failures with liver disease that preceded the transplantation by a mean of 68 months. Even though 14 patients died in less than 1 year, the 71% actuarial 1-year survival and the 57% 2-year survival rates are not significantly different than that of the overall group of 604 patients of our total series.

Cholangiocarcinoma was found at pathologic examination of the removed liver specimen in five (9.9%) of 55 patients. Two of these recipients have died and one has recurrence of disease. Although two patients are still disease free, their long-term outlook remains to be determined since the follow-up period has been short. We currently believe that any patient undergoing stenting of the biliary tree should have brushings, cytologic examination, and/or needle biopsies obtained in an attempt to bring these patients to earlier transplantation before malignant changes occur.

This experience demonstrates the effectiveness of orthotopic liver transplantation for patients with advanced primary sclerosing cholangitis. In the future, liver replacement should not be reserved as a last minute operation for moribund patients who have undergone the gamut of palliative medical and surgical therapies that have not been shown to be effective in prolonging life or reducing morbidity. Specifically, palliative operations such as choledochoenterostomy for sclerosing

Cholangitis should be avoided since the same results can be obtained by transhepatic biliary drainage and balloon dilatation or by endoscopic procedures, particularly in those patients whose sclerosing cholangitis is limited to a narrow segment of the extrahepatic biliary tree. With a 2-year survival rate of 57%, orthotopic liver transplantation has emerged as the sole form of therapy that offers patients who had failed treatment a chance at returning to normalcy at the cost of the least number of lives.

### References

1. Starzl TE, Iwatsuki SI, Shaw BW, Gordon RD. Orthotopic liver transplantation in 1984. *Transplant Proc* 1985; 17:250-258.
2. Starzl TE, Iwatsuki SI, Van Thiel DH, et al. Evolution of liver transplantation. *Hepatology* 1982; 2:614-636.
3. Starzl TE, Iwatsuki SI, Shaw BW, et al. Factors in the development of liver transplantation. *Transplant Proc* 1985; 17:107-119.
4. Schwartz SI, Dale WA. Primary sclerosing cholangitis; review and report of six cases. *Arch Surg* 1958; 77:439-451.
5. Warren KW, Athamasiade S, Monge JI. Primary sclerosing cholangitis. A study of forty-two cases. *Am J Surg* 1966; 111:23-38.
6. Schaffner F. Sclerosing cholangitis. In Berk JE, Haubrich WS, Kalser MH, Roth JLA, Schaffner F, eds. *Bockus Gastroenterology*. Philadelphia: W.B. Saunders, 1985; 3177-3188.
7. Thompson HH, Pitt HA, Tompkins RK, Longmire WP. Primary sclerosing cholangitis. A heterogenous disease. *Ann Surg* 1982; 196:127-136.
8. LaRusso NF, Wiesner RH, Ludwig J, MacCarthy RL. Primary sclerosing cholangitis. *N Eng J Med* 1984; 310:899-903.
9. Thompson HH, Pitt HA, Tompkins RK, Longmire WP. Primary sclerosing cholangitis: results of an aggressive surgical approach. *Ann Surg* 1982; 196:259-268.
10. Cameron JL, Gayles BW, Herlong HF, Maddrey WC. Sclerosing cholangitis; biliary reconstruction with Silastic transhepatic stents. *Surgery* 1983; 94:324-440.
11. Wiesner RH, LaRusso NF. Clinicopathologic features of the syndrome of primary sclerosing cholangitis. *Gastroenterology* 1980; 79:200-206.