

Transplant Int (1989) 2: 121

The anterior route for arterial graft conduits in liver transplantation*A. Tzakis¹, S. Todo¹ and T. E. Starzl^{1, 2}¹ Department of Surgery, University Health Center of Pittsburgh, University of Pittsburgh, 3601 Fifth Avenue, Falk Clinic 4 West, Pittsburgh, PA 15213, USA² The Veterans Administration Medical Center, University Drive C, Pittsburgh, PA, USA

The so-called conduit techniques for arterialization of orthotopic liver homografts were first developed in the laboratory [2] and later applied in the clinic [1, 3, 4]. With most of these procedures, the arterial grafts have been tunneled posterior to the duodenum, passing either to the right or to the left of the superior mesenteric artery, in a plane just anterior to the inferior vena cava and left renal vein [4].

Although these routes are usually satisfactory and the shortest possible in terms of length, the tunnels are created blindly, and occasionally collateral veins may be ruptured in the process. Furthermore, the grafts are so thoroughly covered that it may be difficult or impossible to see them if they have bleeding points or to excise them later if there is reason to do so.

An alternative option, and the one that is preferable in many instances, is to pass the graft from the same starting point on the aorta through a hole in the transverse mesocolon, behind the pylorus, and into the subhepatic region (Fig. 1). This way the entire extent of the graft can be examined for hemostasis, and the other disadvantages of the retroperitoneal graft are avoided.

This technique has been used on several occasions when the retroperitoneal route was either inconvenient or impossible, at times in patients who had had previous conduits and who were undergoing retransplantation. The arterial grafts can also be placed in parallel with venous jump grafts from the superior mesenteric vein to the hepatic hilum [5].

These arterial and/or venous jump grafts enable transplant surgeons today to effectively revascularize livers in the orthotopic location with a minimum of hilar dissection. Thus far, no complications have been encountered from this approach which, for the creation of arterial conduits, may largely replace the "deep" techniques employed in the past.

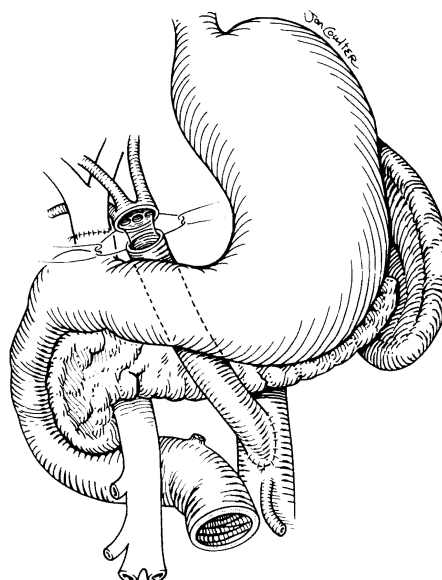


Fig. 1. The route of free graft of donor iliac artery from the recipient aorta to the hilar area of an orthotopic liver graft. Note the donor arterial anomaly in which the right, middle, and left hepatic arteries originate separately from the aorta. This was more easily handled by having such open exposure of the conduit graft

References

1. Starzl TE, Putnam CW (1969) Experience in hepatic transplantation. Saunders, Philadelphia, pp 129-133
2. Starzl TE, Kaupp HA Jr, Brock DR, Lazarus RE, Johnson RV (1960) Reconstructive problems in canine liver homograft transplantation with special reference to the postoperative role of hepatic venous flow. *Surg Gynecol Obstet* 111: 733-743
3. Shaw BW Jr, Iwatsuki S, Starzl TE (1984) Alternative methods of arterialization of the hepatic graft. *Surg Gynecol Obstet* 159: 490-493
4. Todo S, Makowka L, Tzakis AG, Marsh JW Jr, Karrer FM, Armany M, Miller C, Tallent MB, Esquivel CO, Gordon RD, Iwatsuki S, Starzl TE (1987) Hepatic artery in liver transplantation. *Transplant Proc* 19: 2406-2411
5. Tzakis A, Todo S, Stieber A, Starzl TE (1989) Venous jump grafts for liver transplantation in patients with portal vein thrombosis. Transplantation, in press

* Supported by research grants from the Veterans Administration and by grant no. DK 29961 from the National Institutes of Health, Bethesda, Maryland

Offprint requests to: T. E. Starzl, Department of Surgery, 3601 Fifth Avenue, Falk Clinic 4 West, Pittsburgh, PA 15213, USA