1357

Chapter 10

LIVER TRANSPLANTATION

Carlos O. Esquivel, M.D., Ph.D.
Thomas E. Starzl, M.D., Ph.D.

The consequences of end-stage liver disease in children are devastating. Children with such diseases suffer from the problems associated with portal hypertension and the effects of malabsorption, particularly those children with chronic cholestatic liver disease. A typical example is the growth failure and rickets in children with biliary atresia, even those with successful portoenterostomies.[6]

Liver disease in children may be classified in three broad categories for didactic purposes: (1) chronic cholestatic liver disease, which accounts for approximately 75 percent of the diseases treated with transplantation; (2) inborn errors of metabolism, constituting approximately 20 percent of the indications; and (3) post-hepatic cirrhosis. Primary liver malignancy is an unusual indication for liver transplantation in children.[10]

Liver transplantation is becoming a routine surgical intervention in many centers in North America and Europe, in spite of the fact that it was considered to be an experimental operation just a few years ago.[31] The experience with pediatric liver transplantation at the University of Pittsburgh during the cyclosporine era is discussed here in more detail.

SURGICAL ASPECTS

The Donor

A significant problem in pediatric transplantation is the scarcity of small donors. In the United States, organs are retrieved from only approximately 15 to 20 percent of potential donors, owing to resistance from the medical profession and from people in general. Although organ donation in the United States is voluntary, a "required request" law—which compels hospitals to approach the families of potential donors—has recently been passed in many states in an attempt to increase the donor supply.

The donor should be selected expeditiously and carefully. Information must be obtained about the cause of death and about prior infections, including exposure to hepatitis or HIV (human immunodeficiency virus) infection, and any history of malignancy.[3, 28, 32]

The following laboratory tests ought to be performed: hepatic transaminase levels (alanine aminotransaminase, aspartate aminotransaminase), total and direct bilirubin, and prothrombin time. Serology tests for HIV, hepatitis B, and cytomegalovirus (CMV) should also be performed. The latter is very important in children, because many have never been exposed to CMV and the risk of transmission is very high.

The donor should receive whatever is necessary, such as blood transfusions, oxygen, and vasopressors, in order to maintain hemodynamic stability. Hepatic congestion must be prevented by the judicious administration of fluids and careful monitoring of central venous pressure.

It is difficult to predict graft function. In a previous investigation the oxygenation of the donor had an important correlation with graft function, but other factors studied, such as bilirubin values, transaminase values, and administration of vasoactive substances, had little or no bearing on graft outcome.[7]

To minimize graft dysfunction the technique of harvesting has been modified.[39, 42] As performed currently in Pittsburgh, the harvesting is based on rapid flushing of the organs followed by removal en bloc.[42] Undoubtedly, the most important principle is rapid cooling of the organs. The primary graft dysfunction in some patients may represent a form of accelerated rejection, as some data indicate.[2]

The progress in the development of new solutions for preservation has been slow since the introduction into clinical practice of Collins' solution. Nevertheless, Belzer's group from the University of Wisconsin recently reported their successful experience with a new solution for the preservation of the liver for up to 24 hours.[21] This has been confirmed experimentally at our institution.

The Recipient

Liver transplantation is offered when a child develops manifestations of portal hypertension such as variceal bleeding, ascites, or hypersplenism. It should also be considered when the child's growth and development stop as the result of end-stage liver disease. For obvious reasons, liver replacement should not be deferred until the patient is moribund, nor should the patient be subjected to an unnecessary operation that may jeopardize a future transplant, such as revision of portoenterostomy or mesocaval or portacaval shunt.[14, 25, 33] The distal splenorenal shunt is safer because the dissection is not in the hepatic hilum; however, it may still predispose to shrinkage or even thrombosis of the portal vein, limiting the opportunity for a liver transplant.[11]

Venous Bypass

The techniques of hepatic transplantation have been reported in detail elsewhere.[39] There are, however, some subtle differences between pediatric and adult liver transplantation. One is the use of venous bypass during the anhepatic phase.[36] Unlike adults, many children tolerate the anhepatic stage very well. This does not mean that the venous bypass is superfluous in children. In fact, the renal and intestinal insult, as well as the fibrinolysis triggered by prolonged clamping of the portal vein, is significantly minimized when the venous bypass is used.[36]

Venous bypass may be used safely in children who weigh more than 15 kg; the size of the veins is the limiting factor in smaller children. In our experience the size of the venous cannulae should be at least No. 12 French for the axillary and femoral veins and No. 16 French for the portal vein. If

the axillary vein is too small to allow passage of the cannula, the alternative is to use the junction of the external jugular vein and the subclavian vein, which is exposed through a small incision placed between the insertion of the heads of the sternocleidomastoid muscle. Flows greater than 1000/ml per minute are ideal, although transplants have been performed safely with lesser flows.[23] Obviously, low flow may predispose to thrombosis and fatal embolism.

Arterial Reconstruction

Arterial reconstruction in children calls for a perfect vascular technique. Any technical error inevitably leads to thrombosis, one of the most feared complications in transplantation.[46] Technical complications may not be the only factors implicated in hepatic artery thrombosis. Other potential contributing conditions are rejection causing an outflow resistance, as has been demonstrated angiographically; vascular anomalies; vascular grafts in difficult reconstructions; and overmanipulation of the coagulation system with clot-promoting substances.[29, 38, 45, 48, 50] The best results are obtained with an end-to-end anastomosis between the donor celiac axis and the recipient's common hepatic artery or celiac axis.[30]

It is also important to prevent a state of hypercoagulation during the immediate postoperative period. Fresh-frozen plasma and platelets are not administered during surgery unless the patient has a life-threatening hemorrhage. Furthermore, at the end of the procedure the patient is given Dextran 40 for 5 days, aspirin, and dipyridamole (Persantine). In certain cases full heparinization may be necessary.

Portal Vein Reconstruction

Troubling reconstructions of the portal vein usually occur in patients with extrahepatic biliary atresia who have had numerous operations in the hepatic hilum, such as multiple revisions of portoenterostomies or portosystemic shunts or both. The reconstruction of the portal vein may also be difficult in retransplantation, particularly in the presence of peritonitis.

A significant number of patients with biliary atresia do have hypoplastic portal veins, and often patients already have portal vein thrombosis by the time they are referred to us for transplantation.

Hypoplastic or thrombosed portal veins are not suitable vessels for reconstruction; thus, the anastomosis in such cases is performed at the junction of the superior mesenteric vein (SMV) and splenic vein (SV) after removing the entire diseased portal vein. Interposition venous grafts using donor iliac veins are necessary when the donor liver is small and the length of the portal vein does not reach the junction of SMV and SV.[35] In these cases the venous graft should be anastomosed to the junction of the SMV and SV before the hepatectomy is performed, especially when venous bypass is not used. If the sequence of steps is changed and the hepatectomy is performed first, the anastomosis of the venous graft with the junction of SMV and SV may be difficult and hazardous because of inadequate exposure due to tissue edema from prolonged clamping of the vena cava and portal vein.

BILIARY TRACT RECONSTRUCTION

The most common type of reconstruction used in children is the choledochojejunostomy into a Roux-en-Y limb because of the absence (due to biliary atresia) or small size of the common bile duct.[40, 42] A primary end-to-end reconstruction with a small common bile duct is cumbersome because of the lack of appropriate-sized T tubes. The smallest commercially available T tube is No. 5 French. In older children with normal recipient common bile duct the reconstruction may be done end-to-end using a T tube, which is removed 2 to 3 months following transplantation. The anastomosis is performed with interrupted absorbable 6–0 sutures (e.g., Maxon or Vicryl). The vertical limb of the T tube is carried through the native bile duct as far as possible from the anastomosis and then brought out of the abdomen through a separate stab wound. The T tube is then connected to a bag. Inspection of the bile may help in the diagnosis of graft dysfunction, including rejection.

The choledochojejunostomy is made end-to-side with interrupted absorbable 6–0 stitches. A stent 3 to 5 cm long

is used for this anastomosis and is secured in place with a single stitch of 6–0 chromic suture. The diameter of the stent should be the largest that slides with ease into the common bile duct. Forcing larger stents into the common bile duct may create pressure necrosis, which is followed by a bile leak and peritonitis.

The stent is made by cutting the distal 3- to 5-cm segment of a Salem nasogastric tube. A few holes are then made on the side to facilitate bile drainage, and the radiopacity of the Salem nasogastric tube facilitates its location with a plain film of the abdomen. The stents usually are dislodged and eliminated in the stool 2 to 4 weeks after the operation.

IMMUNOSUPPRESSION

The regimen of immunosuppression used at the University of Pittsburgh consists of cyclosporine and small doses of corticosteroids.[10, 41] Triple-drug therapy, which includes the addition of azathioprine, or quadruple-drug therapy (azathioprine, antilymphocytic globulin, cyclosporine, and corticosteroid) is used frequently in other institutions.[21, 44]

Cyclosporine

The introduction of cyclosporine (Sandimmune) to clinical practice dramatically changed the outcome of liver transplantation, and the survival rate has more than doubled. The initial dose of cyclosporine is 6 mg/kg per day (IV) divided in three doses, but children often require much higher doses in order to reach the trough level of at least 1000 ng/ml that is considered in the therapeutic range. Likewise, the initial dose of oral cyclosporine is 20 mg/kg per day divided in two doses, but more often higher doses are required to achieve adequate trough levels.[4] The reason is that children metabolize cyclosporine faster than adults and frequently have transient malabsorption following transplantation.[5] Moreover, some children take phenobarbital or dilantin for seizure control, and such drugs are known to lower the cyclosporine level. Children tolerate high doses of cyclosporine well since they usually have excellent renal function.

Intravenous cyclosporine is discontinued when adequate

levels can be maintained with oral administration. This is a gradual process that takes 1 to 6 weeks.

Corticosteroids

Postoperatively, corticosteroids are administered intravenously until the paralytic ileus is resolved. The initial dose of methylprednisolone sodium succinate (Solu-Medrol) is 100 mg divided into four doses. Subsequently, the dose is tapered by 20 mg daily, to end with a maintenance dose between 5 and 20 mg per day, depending on the weight of the patient (this is called a recycle of steroids in our institution). The methylprednisolone is changed to prednisone when the patient tolerates oral feedings.[10] The eventual maintenance dose is approximately 0.2 mg/kg per day to allow normal linear growth in children.[17]

Corticosteroids also are used in the treatment of acute rejection; the dosage depends on the severity of the rejection and the weight of the patient. Mild rejection may be brought under control by a single intravenous pulse of hydrocortisone sodium succinate (Solu-Cortef), 0.5 mg. A full recycle of corticosteroids should be given in the presence of severe rejection.

Monoclonal Antibodies

Recently, the monoclonal antibody OKT3 (Orthoclone) has been added to the immunosuppressive armamentarium.[16] OKT3 has been found to be effective in reversing cell-mediated rejection in liver transplantation in almost 90 percent of patients. It has improved early survival and has decreased the incidence of retransplantation.[9, 28] This monoclonal antibody also has been used more than once in a given patient; this is possible provided that murine antibodies are not detected in the serum.

The recommended dose in children is 2.5 ml intravenously daily for 2 weeks. Although the side effects usually are mild it is advisable to premedicate patients with 0.5 g hydrocortisone (IV) for the first two doses, and acetaminophen and diphenhydramine hydrochloride (Benadryl) for the entire length of the treatment. OKT3 is the

treatment of choice for steroid-resistant acute rejection.[9, 16, 27]

INDICATIONS AND RESULTS

In the cyclosporine era, 334 pediatric patients underwent liver transplantation between March 1980 and July 1987 at the University of Pittsburgh Health Centers. The most common diagnostic indications were biliary atresia (both extra- and intrahepatic types), inborn metabolic errors such as α_1-antitrypsin deficiency, tyrosinemia, Wilson's disease, and posthepatic cirrhosis. Other less frequent indications are listed in Table 10–1.

Survival According to Diagnosis

The overall actuarial survival rates for the entire group were 72 and 66 percent at 1 and 5 years, respectively. The survival of 168 children with extrahepatic biliary atresia was 70 percent at 1 year and 65 percent at 5 years. In contrast, survival in the group with intrahepatic biliary atresia (Alagille's syndrome) was 54 and 44 percent at 1 and 5 years, respectively. Three children with Alagille's syndrome died during the immediate postoperative period of complications of pulmonary hypertension with cardiovascular collapse.

Survival for patients with inborn errors of metabolism is

Table 10–1. DIAGNOSTIC INDICATIONS FOR LIVER TRANSPLANTATION BEFORE AGE 18 YEARS

Indication	No.	Percent
Biliary atresia	178	53.3
Inborn errors of metabolism	63	18.9
Postnecrotic cirrhosis	40	12.0
Familial cholestasis	15	4.5
Fulminant hepatitis	13	3.9
Congenital fibrosis	7	2.1
Secondary biliary cirrhosis	7	2.1
Primary hepatic tumors	4	1.2
Budd-Chiari syndrome	2	0.6
Neonatal hepatitis	2	0.6
Trauma	1	0.3
Pseudoinflammatory tumor	1	0.3
Sclerosing cholangitis	1	0.3

somewhat better than for those with biliary atresia. At 1 and 5 years, the actuarial survival rates were 80 and 75 percent, respectively. The most common diagnostic indication in this group was α_1-antitrypsin deficiency, and the long-term survival rate exceeds 80 percent.

The prognosis in patients with postnecrotic cirrhosis is very good: actuarial survival is 81 percent at 1 year and 77 percent at 5 years (Fig. 10–1).

Survival According to Age

The age of the patient at the time of transplantation has little bearing on the long-term outcome, perhaps with the exception of children younger than 1 year of age. In the latter group, the survival rate is 66 percent at 6 months and 65 percent at 1 year; however, it is 37 percent at 5 years, with only one patient at risk. The actuarial survival rate after 3 years is difficult to assess: because there are so few patients at risk (two), a single death would have significant impact on the survival curve. On the other hand, the survival at 1 year is no different from that of older patients (Fig. 10–2).

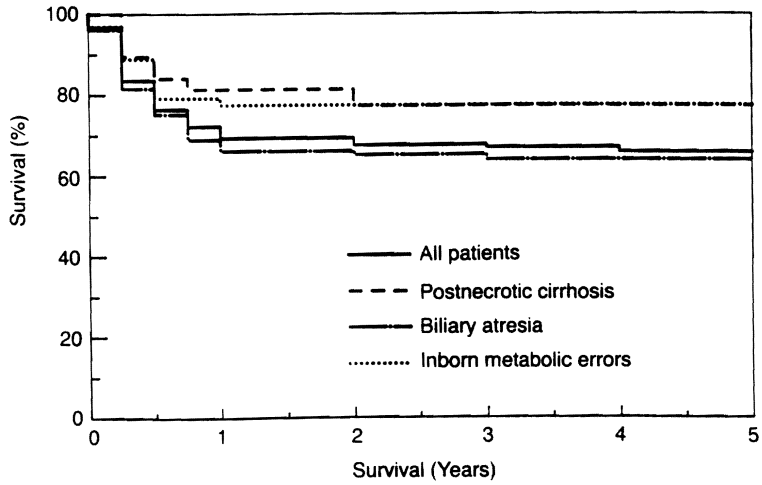

Figure 10–1. Effect of underlying liver disease on actuarial survival rate after hepatic transplantation. The difference is not statistically significant.

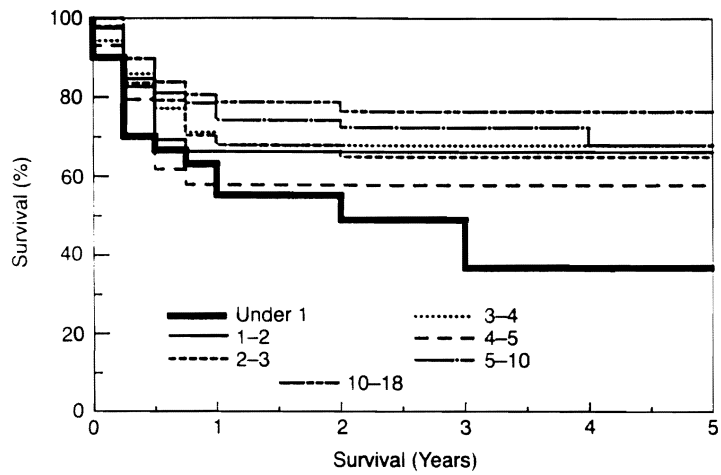

Figure 10–2. Impact of age at the time of hepatic transplantation on actuarial survival rate. Up to age 1 year there is no significant difference; thereafter, the survival rate is decreased among infants.

Retransplantation

Almost one out of four children eventually requires retransplantation. The indications are rejection in 43.3 percent, technical complications in 43.3 percent, and primary graft nonfunction in 13.4 percent.[10] Arterial thrombosis accounts for most of the technical complications requiring retransplantation. The survival depends on the indication or on the number of transplants. Retransplantation for primary graft nonfunction is associated with the poorest survival rate, approximately 10 percent. For the other two indications the survival rate approaches 50 percent when the indication was technical complications and 79 percent when the reason for retransplantation was rejection. Likewise, survival in patients with primary transplants is 75 percent; with secondary and tertiary transplants it is approximately 50 percent and 35 percent, respectively.

Quality of Life

Quality of life for transplant recipients has been the subject of several reports.[14, 20, 49] The social and vocational

reintegration of liver transplant recipients is good. It is remarkable to observe the changes soon after transplantation as the children become interested in their environment and their appetite gradually improves. Debilitated children who did not have enough strength before transplantation begin to walk soon afterward. Certainly, some children with major sequelae from the ravages of the underlying disease require rehabilitation.

Urbach and coworkers reported the impact of liver transplantation on the linear growth of children.[47] Roughly 74 percent of the patients had good linear growth following transplantation, and several crossed percentiles in an upward direction. The common denominator in the majority of children whose growth was poor was high doses of steroids for repeated bouts of rejection.

COMMENTS

Chronic cholestatic liver disease accounts for almost two thirds of the indications for liver transplantation in children. The hepatic lesion in this group of diseases is characterized by a bile duct injury with impairment of bile excretion, often leading to cirrhosis. Biliary atresia is the most common disease among this group, representing 53 percent of all indications for pediatric liver transplantation. Complications after liver transplantation for biliary atresia are significant owing to previous operations in the hepatic hilum (e.g., extrahepatic biliary atresia) or to associated medical problems such as pulmonary hypertension in the Alagille's syndrome patients.[7, 13] Previous abdominal operations definitely increase the postoperative morbidity rate, particularly in patients with portoenterostomies. These patients often suffer frequent bouts of cholangitis, which lead to further deterioration of the clinical condition. Some are left with stomas in an attempt to minimize the problems of cholangitis, but such stomas also are associated with significant complications, such as bleeding and contamination during the transplant operation. More importantly, they may not prevent the episodes of cholangitis. While stable patients are waiting for liver transplantation stomas should be taken down.

The inborn metabolic or genetic disorders fall into three

different categories: (1) those based in the liver that are associated with a hepatocyte injury (e.g., α_1-antitrypsin deficiency, tyrosinemia, and others),[13,34,43] (2) extrahepatic-based disorders with associated liver injury, such as cystic fibrosis,[37] and (3) those based in the liver that are not associated with hepatic injury, such as the defects of the urea cycle. Most of the metabolic disorders treated with hepatic transplantation belong to the first group.[1] The long-term outcome is excellent, and the hepatic replacement cures the underlying metabolic defect.[19] Very few patients with cystic fibrosis and other rare disorders and with associated end-stage liver disease have undergone transplantation successfully. One of these patients with the syndrome of Neville did develop a recurrence of the underlying disease.[17]

As results improve with the introduction of new immunosuppressive and preservation agents, liver transplantation will be offered to patients with metabolic disorders based in the liver before the onset of systemic complications, even in the absence of hepatic disease. Several diseases fall into this category, such as defects of the urea cycle, some of the lipidoses, and others.

Postnecrotic and posthepatic cirrhosis are less common indications for pediatric liver transplantation. Most are secondary to non-A or non-B hepatitis, and the overall results are very good. Hepatitis B as an indication is extremely rare in children.[20]

Liver transplantation in infants is associated with significant morbidity.[12] The main complications are primary graft nonfunction, vascular thrombosis, and intestinal perforation. Many of these infants are in very poor medical condition at the time of transplantation, and the urgency may not allow them to wait for optimal grafts since the shortage of small organs is a serious problem. To alleviate this problem, many centers are reducing the size of the liver by doing partial resections before implantation.[18]

Most deaths after pediatric transplantation occur within the first 6 months.[22] If the patients survive this critical period, the long-term outlook is excellent. The majority of patients are restored to a normal life style, which is more than enough incentive to continue with the demanding task of caring for children with end-stage liver disease before and during the critical posttransplantation period.

SUMMARY

The survival rate after liver transplantation increased remarkably following the introduction of cyclosporine in 1980 and with improvements in surgical techniques and management during the perioperative period. Most pediatric liver transplant candidates suffer from chronic cholestatic disease or from liver-based metabolic disorders with associated cirrhosis. In the latter group, liver transplantation cures the underlying metabolic defect by conferring the phenotype of the donor. The rehabilitation of pediatric patients after successful liver transplantation is excellent, and most enjoy life styles similar to those of normal children.

References

1. Balisteri WF, Schubert WK: Liver disease in infancy and childhood. In Schiff L, Schiff ER (eds): Diseases of the Liver, 6th Ed. Philadelphia, JB Lippincott, 1987.
2. Brantley SG, Jaffe R, Esquivel CO: Acute humoral rejection of an ABO-unmatched liver allograft in a pediatric recipient. Pediatr Pathol 8:467–475, 1988.
3. Bronster O, Makowka L, Jaffe R, et al.: The occurrence of cytomegalovirus hepatis in liver transplant patients. J Med Virol 24:423–434, 1988.
4. Burckart GJ, Starzl TE, Venkataramanan R, et al.: Cyclosporine absorption following orthotopic liver transplantation. J Clin Pharmacol 26:647–651, 1986.
5. Burckart GJ, Starzl TE, Williams L, et al.: Cyclosporine monitoring and pharmacokinetics in pediatric liver transplant patients. Transplant Proc 17:1171–1175, 1985.
6. Burgess DB, Martin HP, Lilly JR: The development status of children undergoing the Kasai procedure for biliary atresia. Pediatrics 70:624–629, 1982.
7. ChapChap P, Esquivel CO, Iwatsuki S, et al.: Liver transplantation for arteriohepatic dysplasia (Alagille's syndrome). Submitted for publication.
8. Esquivel CO, Starzl TE: Liver transplantation for biliary atresia. In Glassman J (ed): Biliary Surgery. New York, McGraw-Hill, 1987.
9. Esquivel CO, Fung JJ, Markus B, et al.: OKT3 in the reversal of acute hepatic allograft rejection. Transplant Proc 19:2443–2446, 1987.
10. Esquivel CO, Iwatsuki S, Gordon RD, et al.: Indications for pediatric liver transplantation. J Pediatrics 3:1039–1045, 1987.
11. Esquivel CO, Klintmalm G, Iwatsuki S, et al.: Liver transplantation in patients with patent splenorenal shunts. Surgery 101:430–432, 1987.
12. Esquivel CO, Koneru B, Karrer F, et al.: Liver transplantation under one year of age. J Pediatrics 110:545–548, 1987.
13. Esquivel CO, Marino IR, Fioravanti V, et al.: Liver transplantation for metabolic liver disease. Clin Gastroenterol 17:167–175, 1988.
14. Esquivel CO, Marino IR, Iwatsuki S, et al.: Long-term results of hepatic transplantation during the cyclosporine era. The Pittsburgh experience. Vol IX. Excerpta Medica, Amsterdam, The Netherlands, Elsevier Science Publishers, 1987, pp. 185–196.

15. Esquivel CO, Vincente E, Van Thiel D, et al.: Orthotopic liver transplantation for α_1-antitrypsin deficiency: An experience in 29 children and 10 adults. Transplant Proc 19:3798–3802, 1987.
16. Fung JJ, Demetris AJ, Porter KA, et al.: Use of OKT3 with cyclosporine and steroids for reversal of acute kidney and allograft rejection. Nephron 96:19–33, 1987.
17. Gartner JC Jr, Bergman I, Malatack JJ, et al.: Progression of neurovisceral storage disease with supranuclear ophthalmoplegia following orthotopic liver transplantation. Pediatrics 77:104–106, 1986.
18. Hemptinne BD, Salizzoni M, Tan KC, et al.: The technique of liver size reduction in orthotopic transplantation. Transplant Proc 20:508–511, 1988.
19. Hood JM, Koep LJ, Peters RL, et al.: Liver transplantation for advanced liver disease with α_1-antitrypsin deficiency N Engl J Med 302:272–275, 1980.
20. Iwatsuki S, Starzl TE, Todo S, et al.: Experience in 1,000 liver transplants under cyclosporine-steroid therapy. A survival report. Transplant Proc 20:498–504, 1988.
21. Jamieson NV, Sundberg R, Lindell S, et al.: Successful 24- to 30-hour liver preservation: A preliminary report. Transplant Proc 20:945–947, 1987.
22. Kahn D, Esquivel CO, Madrigal-Torres M, et al.: An analysis of the causes of death after pediatric liver transplantation. Transplant Proc 20:613–615, 1988.
23. Kam I, Lynch S, Todo S, et al.: Low-flow venovenous bypasses in small dogs and pediatric patients undergoing replacement of the liver. Surg Gynecol Obstet 163:33–36, 1986.
24. Kalayouglu M, Hoffman R, Sollinger HW, et al.: Quadruple immunosuppressive therapy for liver transplantation. Transplant Proc 20:524–529, 1988.
25. Lerut J, Tzakis AG, Bron K, et al.: Complications of venous reconstruction in human orthotopic liver transplantation. Ann Surg 205:404–414, 1987.
26. Makowka L, Gordon RD, Todo S, et al.: Analysis of donor criteria for the prediction of outcome in clinical liver transplantation. Transplant Proc 19:2378–2382, 1987.
27. Markus BH, Fung JJ, Gordon RD, et al.: Effect of OKT3 on survival and rate of transplantation. Transplant Proc 19:61–62, 1987.
28. Marsh JW, Esquivel CO, Makowka L, et al.: Accidental transplantation of malignant tumor from a donor to multiple recipitents. Transplantation 44:449–450, 1987.
29. Marsh JW Jr, Makowka L, Gordon RD, et al.: Vascular homografts in hepatic transplantation. J Vasc Surg, submitted for publication.
30. Mazaferro V, Esquivel CO, Makowka L, et al.: Factors responsible for hepatic artery thrombosis after pediatric liver transplantation. Transplant Proc 21:2466–2467, 1989.
31. National Institutes of Health Consensus Development Conference Statement: Liver transplantation. Hepatology 4(suppl):1975, 1984.
32. Rubin RH, Jenkins RL, Shaw BW Jr, et al.: The acquired immunodeficiency syndrome and transplantation. Transplantation 44:1–4, 1987.
33. Scantlebury VP, Zajko AB, Esquivel CO, et al.: Successful reconstruction of late portal vein stenosis after hepatic transplantation. Arch Surg 124:503–505, 1989.
34. Sharp HL, Bridges RA, Krivit W, et al.: Cirrhosis associated with α_1-antitrypsin deficiency: A previously unrecognized inherited disorder. J Lab Clin Med 73:934–939, 1969.

35. Shaw BW Jr, Iwatsuki S, Bron K, et al.: Portal vein grafts in hepatic transplantation. Surg Gynecol Obstet 161:66–68, 1985.
36. Shaw BW Jr, Martin DJ, Marquez JM, et al.: Venous bypass in clinical liver transplantation. Ann Surg 200:524–534, 1984.
37. Shier KJ, Horn RC Jr: The pathology of liver cirrhosis in patients with cystic fibrosis of the pancreas. Can Med Ass J 89:645, 1963.
38. Starzl TE (with the assistance of CW Putnam): Experience in Hepatic Transplantation. Philadelphia, WB Saunders, 1969.
39. Starzl TE, Iwatsuki S, Esquivel CO, et al.: Refinements in the surgical technique of liver transplantation. Semin Liver Dis 5:349–356, 1985.
40. Starzl TE, Iwatsuki S, Shaw BW Jr, et al.: Immunosuppression and other nonsurgical factors in the improved results of liver transplantation. Semin Liver Dis 5:334–343, 1985.
41. Starzl TE, Iwatsuki S, Van Thiel DH, et al.: Evolution of liver transplantation. Hepatology 2:614–636, 1982.
42. Starzl TE, Miller C, Broznick B, et al.: An improved technique for multiple organ harvesting. Surg Gynecol Obstet 165:343–348, 1987.
43. Starzl TE, Zitelli BJ, Shaw BW Jr, et al.: Changing concepts: Liver replacement for hereditary tyrosinemia and hepatoma. J Pediatrics 106:604–606, 1985.
44. StCyr JA, Elick B, Freese D, et al.: Use of triple therapy and percutaneous needle biopsy to minimize graft failure following liver transplantation. Transplant Proc 19:2451–2453, 1987.
45. Todo S, Makowka L, Tzakis AG, et al.: Hepatic artery in liver transplantation. Transplant Proc 19:2406–2111, 1987.
46. Tzakis AG, Gordon RD, Shaw BW Jr, et al.: Clinical presentation of hepatic artery thrombosis after liver transplantation in the cyclosporine era. Transplantation 40:667–671, 1986.
47. Urbach AH, Gartner JC Jr, Malatack JJ, et al.: Linear growth following pediatric liver transplantation. Am J Dis Child 141:547–549, 1987.
48. Zajko AB, Bron KM, Starzl TE, et al.: Angiography of liver transplantation patients. Radiology 157:305–311, 1985.
49. Zitelli BJ, Miller JW, Gartner JC, et al.: Changes in lifestyles after liver transplantation. Pediatrics 82:173–180, 1988.