

Intestinal Transplantation in Composite Visceral Grafts or Alone

SATORU TODO, M.D.,*†‡ ANDREAS G. TZAKIS, M.D.,*†‡ KAREEM ABU-ELMAGD, M.D.,*† JORGE REYES, M.D.,*† KENJIRO NAKAMURA, M.D.,*† ADRIAN CASAVILLA, M.D.,*† RICK SELBY, M.D.,* BAKR M. NOUR, M.D.,*† HARLAN WRIGHT, M.D.,*† JOHN J. FUNG, MD, PH.D.,*†‡ ANTHONY J. DEMETRIS, M.D.,†§ DAVID H. VAN THIEL, M.D.,*† and THOMAS E. STARZL, M.D., PH.D.*†‡

Under FK 506-based immunosuppression, the entire cadaver small bowel except for a few proximal and distal centimeters was transplanted to 17 randomly matched patients, of whom two had anti-graft cytotoxic antibodies (positive cross-match). Eight patients received the intestine only, eight had intestine in continuity with the liver, and one received a full multivisceral graft that included the liver, stomach, and pancreas. One liver-intestine recipient died after an intestinal anastomotic leak, sepsis, and graft-versus-host disease. The other 16 patients are alive after 1 to 23 months, in one case after chronic rejection, graft removal, and retransplantation. Twelve of the patients have been liberated from total parenteral nutrition, including all whose transplantation was 2 months or longer ago. The grafts have supported good nutrition, and in children, have allowed growth and weight gain. Management of these patients has been difficult and often complicated, but the end result has been satisfactory in most cases, justifying further clinical trials. The convalescence of the eight patients receiving intestine only has been faster and more trouble free than after liver-intestine or multivisceral transplantation, with no greater difficulty in the control of rejection.

THE INTESTINE was one of the first organs to be transplanted experimentally,^{1,2} but the last to be grafted successfully in humans. In spite of numerous attempts between 1964 and 1987,³ there were no clinical examples of a functioning intestinal graft until November 1987. Then, a 3-year-old girl began a 6-month period of enterally supported survival after receiving a multivisceral abdominal graft that contained all of the hollow abdominal organs plus the liver and pancreas.⁴ In a similar operation 1 year later, Grant et al.⁵ transplanted the small bowel in continuity with the liver to a recipient

From the Departments of Surgery and Pathology,§ University of Pittsburgh School of Medicine,† and the Veterans Administration Medical Center,‡ Pittsburgh, Pennsylvania*

who is still alive and eating along with a handful of other patients treated with variations of the multivisceral procedure.^{6,7} In contrast, there have been only two examples of long survival and function of cadaveric intestinal grafts when these were transplanted alone.^{6,8}

The prospects for progress in this difficult field were improved with the demonstration in rat intestinal and multivisceral transplant models of the superior therapeutic index of the new immunosuppressive drug FK 506.⁹⁻¹² We report here our experience using this drug for one recipient of the originally described full multivisceral graft, eight recipients of liver-intestine grafts, and eight patients who were given small intestine only. Sixteen of these 17 patients are alive after 1 to 23 months, and most of them are eating. This experience has opened up new options for the treatment of end-stage intestinal disease with or without liver involvement and seems certain to greatly influence the future development and practice of gastroenterology.

Methods

Case Material

Recipients. The intestinal diagnosis in 15 of the 17 patients was short-gut syndrome in which the intestine had been resected for a variety of reasons; the intestine in the other two recipients had uncorrectable disease (Table 1). All of the patients were on total parenteral nutrition (TPN) before transplantation for 1 to 132 (40.9 ± 41.9 [standard deviation]) months (Table 1) and all had experienced more than one episode of sepsis, liver damage, or other TPN-related complications.

Presented at the 112th Annual Meeting of the American Surgical Association, April 6-8, 1992, Palm Desert, California.

Supported by Research Grants from the Veterans Administration and Project grant No. DK 29961 from the National Institutes of Health, Bethesda, Maryland.

Address reprint requests to Thomas E. Starzl, M.D., Ph.D., Department of Surgery, 3601 Fifth Avenue, Falk Clinic 5C, Pittsburgh, PA 15213.

Accepted for publication April 10, 1992.

TABLE 1. Clinical Features of the Recipients

Patient No.	Age (yr)	Sex	Indication	Duration of TPN (mo)	Liver Failure (T. Bil) (mg/dL)	Trans-plantation		Latest Immunosuppression				Current Status			Comments
						Graft	CIT (hr)	FK506 (mg/day)	Steroid (mg/day)	Imuran (mg/day)	Survival (mo)	TPN	Location		
1	31.1	M	Gunshot wound	6	1.1	SB	10.5	5 (IV)	20	—	—	>23.0	Total	ICU	Kidney transplantation at 20 mo; SB retransplantation at 22.5 mo
2	3.2	F	Necrotizing enterocolitis	38	14.1	SB/L	8.9	2	—	—	—	>20.2	Free	Home	Femoral arterial graft
3	26.7	F	SMA thrombosis	30	18.1	SB/L	7.7	3	10	150	—	>19.9	Free	Home	—
4	4.3	M	Gastroschisis	52	16.4	SB/L	2.9	4	—	—	—	>16.2	Free	Home	Spinal cord injury
5	2.8	M	Intestinal atresia	33	44.1	SB/L	10.6	12	10	—	—	>12.3	Free	Home	Long-term ventilation
6	0.6	F	Intestinal atresia	6	6.3	SB/L	4.9	0.1 (IV)	—	—	—	23 days	—	—	support for paralysis of right diaphragm
7	1.1	F	Volvulus	12	15.2	SB/L	7.5	6	5	—	—	>7.7	Free	Home	Died of sepsis and GVH disease
8	1.7	F	Volvulus	18	50.5	SB/L	7.6	16	—	—	—	>7.6	Free	Home	—
9	21	M	Traffic accident	12	9.2	SB/L	8.2	4	10	100	—	>7.3	Free	Home	Pancreatitis, transient renal failure
10	32	M	SMA & CA Thrombosis	36	0.5	MV	9.5	6	5	100	—	>5.6	Free	Surgical ward	Long-term ICU stay; transient renal failure
11	2.5	F	Protein S deficiency Microvillus inclusion disease	29	0.4	SB	2.8	20	—	—	—	>5.0	Free	Surgical ward	—
12	1.3	M	Intestinal atresia	15	0.4	SB	6.8	6	5	—	—	>3.2	Free	Home	—
13	50	F	Crohn's disease	120	1.0	SB	8.3	12	10	—	—	>3.1	Free	Home	—
14	34	F	Gardner's syndrome	1	1.1	SB	5.3	24	20	100	—	>2.0	Free	Home	—
15	38	M	Desmoid tumor	120	1.8	SB	6.3	24	20	100	—	>0.9	Partial	Surgical ward	—
16	10.2	F	Chronic intestinal Pseudo-obstruction	132	0.6	SB	6.3	4 (IV)	20	—	—	>0.8	Partial	Surgical ward	—
17	23	F	Crohn's disease	36	0.9	SB	5.5	5 (IV)	20	—	—	>0.7	Partial	Surgical ward	—

SMA, superior mesenteric artery; CA, celiac axis; SB, isolated small bowel; SB/L, small bowel + liver; MV, multivisceral graft; CIT, cold ischemia time; TPN, total parenteral nutrition; total, totally dependent; partial, partially dependent; free, independent.

Eight of the 17 patients were 21- to 50-year-old adults (mean age, 31.9 ± 9), and nine were children who were 0.6 to 4.3 years of age (Table 1). The full multivisceral procedure was in a 32-year-old man with protein S deficiency whose clotting abnormality had caused thrombosis of his superior mesenteric artery and celiac axis, with consequent intestinal gangrene. Because the liver is the source of protein S,¹³ its inclusion in the graft was obligatory even though hepatic failure was not present. All eight patients undergoing liver-intestine transplantation (two adults, six children) had advanced hepatic disease with serum total bilirubin concentration from 6.3 to 50 mg/dL. The eight patients (five adults, three children) given isolated small bowel grafts were jaundice free, although most had minor liver function abnormalities.

Transplantation Procedures

Donors. Cadaveric donors of similar or smaller size were selected, all being ABO blood group identical with the respective recipients. Human leukocyte antigen matching was random and uniformly poor. The lymphocytotoxic cross-match was positive in two patients.

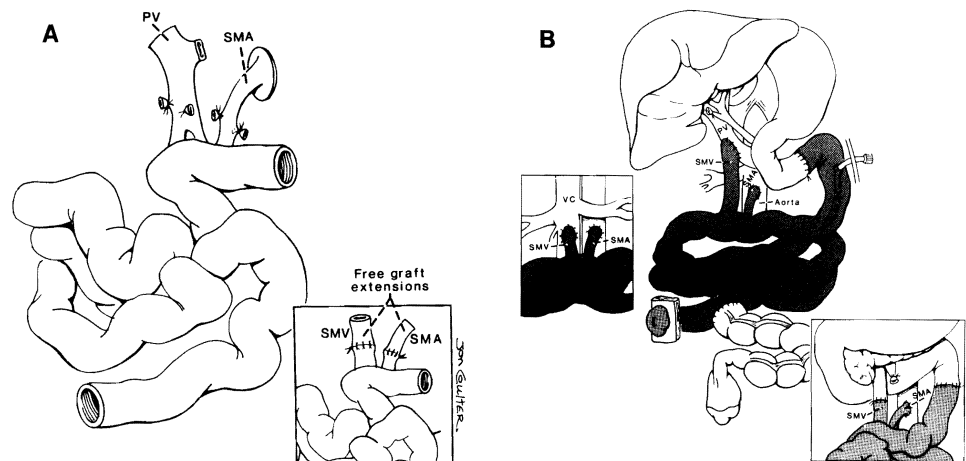
The principles¹⁴ as well as details¹⁵ of the donor operations have been described elsewhere and included an effort at selective bacterial and fungal decontamination. The contents of the intestinal lumen were not mechanically washed during the donor operation or afterward. Instead, the proximal and distal ends of the intestine were sealed with a stapling machine, carrying and transplanting the succus entericus to the recipient. Initial cooling of the graft was by infusion with cold University of Wisconsin (UW) solution, the volume of which was limited to 1 L in adult donors to prevent infusion injury.¹⁵ Cold ischemia times were 2.8 to 10.6 hours (Table 1). For reasons discussed elsewhere,¹⁴ no effort was made to alter the lymphoreticular (immunologic) component of the graft with antilymphoid agents, irradiation, or other means.

Recipients. The small intestinal graft with or without the liver included its entire length except for discarded short segments of proximal jejunum and distal ileum. When transplanted alone, the small bowel graft was based on a vascular pedicle of superior mesenteric (or skeletonized portal) vein and the superior mesenteric artery with or without an aortic Carrel patch (Fig. 1A). The exact method of revascular reconstruction and the difficulty of its accomplishment depended on the findings in the recipient, which were distorted in most cases by multiple previous intra-abdominal operations. Various options used for vascular reconstruction are shown in Figure 1B. The superior mesenteric venous return was directed into the recipients portal or superior mesenteric vein so that it perfused the native liver in all isolated small bowel engraftments except for the intestinal retransplantation in patient 1, where it was necessary to anastomose the superior mesenteric vein of the graft to the inferior vena cava (Fig. 1B insert).

The vascular reconstructions for the liver-intestine and multivisceral procedures were performed as shown in Figures 2 and 3 with the venous drainage into the graft retrohepatic inferior vena cava. This segment of graft vena cava was used to replace retrohepatic vena caval segment of the host if this was excised during the recipient hepatectomy (Fig. 3B) or it was anastomosed piggy-back to the skeletonized recipient vena cava if the segment could be preserved.¹⁴

Reconstruction of the gastrointestinal tract was with conventional techniques. In the first five cases, both ends of the intestinal graft were exteriorized by the "chimney" method, anastomosing the recipient intestines to the side of the graft nearby the chimney enterostomy. In the later cases, a tube jejunostomy was used proximally instead of a chimney (Figs. 1B, 2B). When the recipients were able to maintain nutrition orally or with tube feedings, the enterostomy or enterostomies were taken down with an extraperitoneal technique. Biliary reconstruction was

FIG. 1. Isolated small bowel transplantation. (A) Donor operation; full-length vascular pedicle of the SMA (with Carrel patch) and the SMV. If both vessels are divided more distally, they can be lengthened on the back table with arterial and venous grafts (insert). (B) Recipient operations. Anastomosis of full-length SMA to the aorta and the angled end of the SMV to the portal vein. Alternative method with which the SMV is anastomosed to the recipient SMV inferior to the pancreas. (Lower insert) Option of SMV drainage into the inferior vena cava (upper insert).



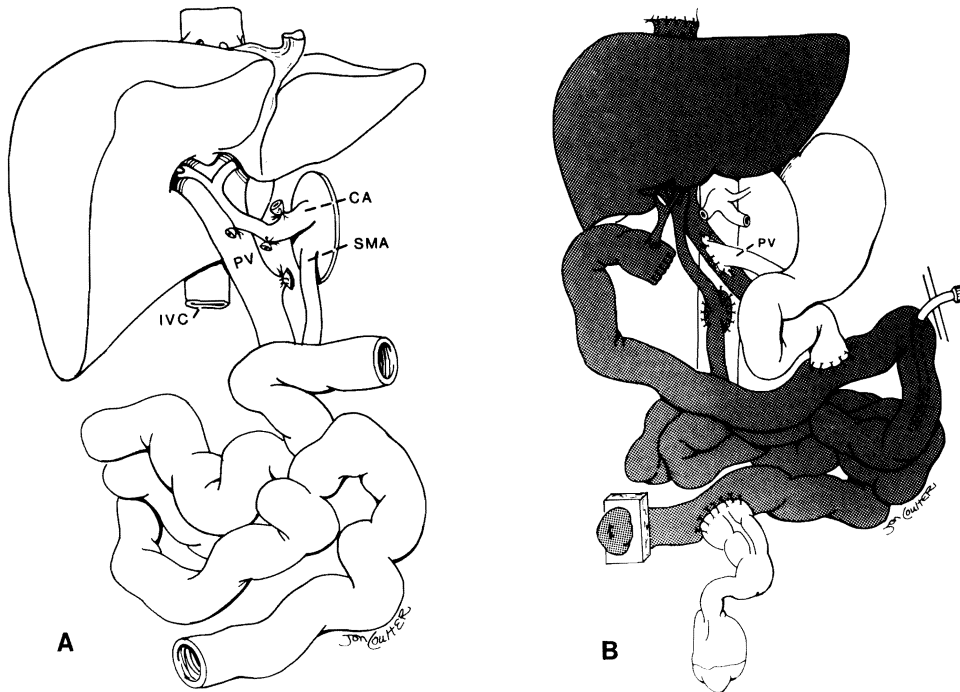


FIG. 2. (A) Small bowel-liver allograft. Note the continuity of donor portal vein. (B) Recipient operation. Carrel patch containing the origin of the SMA and the celiac axis is anastomosed to the aorta. Ideally, the venous return from residual splanchnic viscera of the recipient is routed by vascular anastomosis into the graft portal vein. Numerous options of graft rearterialization and venous drainage have been described elsewhere.¹⁴

performed by Roux-en-y choledochojejunostomy in the liver-intestine recipients (Fig. 2B). Cholecystectomy was carried out in all native (Fig. 1) or allograft livers (Figs. 2 and 3).

Management

Immunosuppression. FK 506 (0.1 to 0.15 mg/kg/day) by continuous intravenous infusion was begun immediately after graft revascularization. When enteral feeding was started, FK 506 was switched to a twice-daily oral formulation with several days of overlap. Plasma levels of FK 506 (trough target, 1 ng/mL) were measured daily during the hospital stay, 2 or 3 times/week for the first 3 months, and at longer intervals thereafter.

Methylprednisolone also was started intraoperatively (first dose of 200-mg bolus) and rapidly weaned by decrements of 40 mg/day over the next 5 days to 20 mg/day. Prostaglandin E₁ (prostin) at 0.6 to 0.8 μ g/kg/hour, was begun intraoperatively in the last nine patients and continued for 7 to 14 days. The FK 506-prednisone-prostaglandin cocktail has given superior results in liver transplant patients, including those with positive cytotoxic cross-matches.¹⁶

Rejection was treated with an upward dose adjustment of FK 506 when this was possible without nephrotoxicity, augmentation of steroids, and OKT3 when necessary.¹⁷

Infection. The same kind of selective decontamination used in the donor was begun before operation in the recipient and continued for 4 weeks after transplantation. Systemic antibiotics were given for the first 5 days ac-

ording to the results of frequent cultures of the blood, stool, urine, sputum, wound exudate, and peritoneal discharge. Chronic virus and protozoal prophylaxis was with acyclovir (for cytomegalovirus) and Bactrim (Roche Laboratories, Nutley, NJ; for *Pneumocystis carinii*).

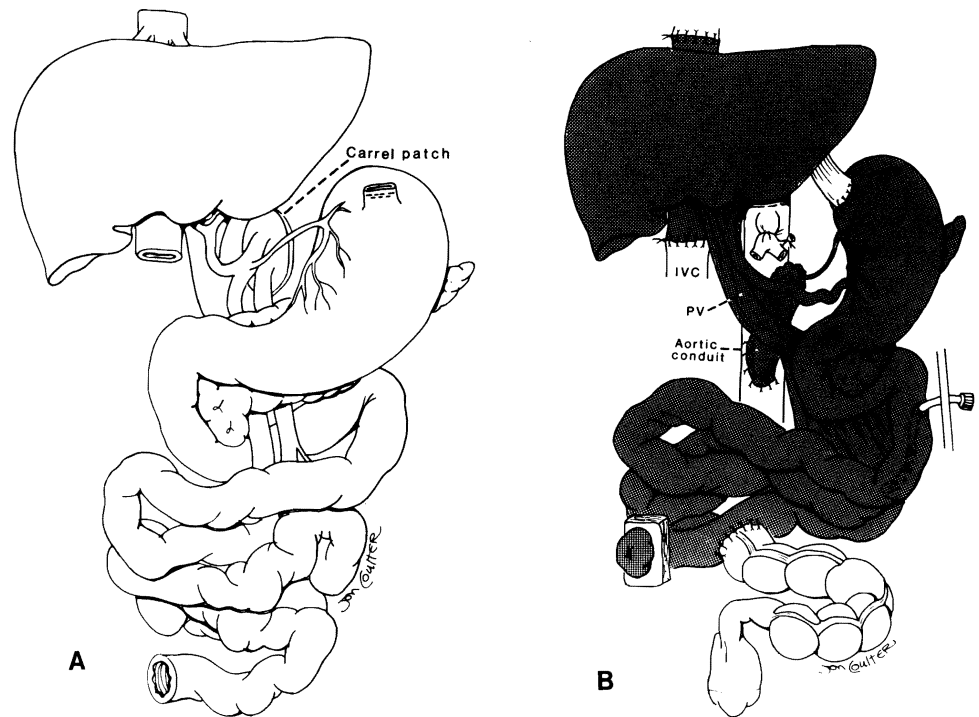
Nutrition. Total parenteral nutrition was tapered gradually when enteral feeding with a jejunal tube was commenced with Peptamen (Clintec Nutrition Co., Deerfield, IL), an isotonic elemental diet that contains peptide-based protein, medium-chain triglycerides, and glutamine. Later, Peptamen was converted in children to Compleat (Sandoz, East Hanover, NJ), a lactose- and gluten-free diet that contains dietary fibers to promote normalization of intestinal motility function.

Monitoring

Rejection. When the diagnosis was suspected clinically, endoscopy was performed and mucosal biopsies were obtained for histopathologic analysis. Adjustments in immunosuppression were dependent mainly on the biopsy findings in a decision-making process summarized in Table 2.

Graft Function. Standard liver and pancreas function tests were used to follow the function of these solid organs. The transplanted and host hollow viscera were studied with repeated endoscopy. Upper gastrointestinal series with barium meal were performed periodically to determine changes of mucosal foldings and the duration of gastric emptying and intestinal transit time. Absorption of d-xylose and fat was measured with the methods of Breiter et al.¹⁸ and Amenta,¹⁹ respectively. Body weight

FIG. 3. Multivisceral allograft (A) before and (B) after transplantation. Splenectomy is performed on the back table. In this case the Carrel patch with the superior mesenteric artery and celiac axis origins has been used to cap a free graft of donor thoracic aorta that has been used as a conduit. This is only one of several options that the operator should be prepared to exercise.¹⁴



as well as serum concentrations of protein, albumin, vitamins, minerals, and trace elements were measured frequently.

Histopathologic Studies

Specimens taken at serial endoscopies, exploratory laparotomy, stomal closure, or at the time of graft removal were fixed with buffered formalin and stained with he-

matoxylin-eosin. The histopathologic diagnosis of acute rejection was made when one or more findings listed in Table 2 and shown in Figure 4 were demonstrated. The diagnosis of chronic rejection (Fig. 5) could be made with certainty only with full-thickness sections of the resected graft. Donor-derived lymphocytes in frozen skin tissues were detected in case 6 with the Y-probe karyotyping methods.

TABLE 2. Monitoring of Intestinal Graft Rejection and Treatment

Rejection	Clinical Findings	Endoscopic Findings	Mucosal Biopsy Findings	Treatment
Acute				
Mild to moderate	Fever Abdominal pain Vomiting Increase of stomal output Watery diarrhea Ileus	Ischemic/dusky mucosa Mucosal edema Hyperema Loss of fine mucosal pattern Decrease of peristalsis	Cell infiltration Villus blunting Cryptitis Epithelial cell damage and regeneration Mucus/paneth cell reduction	Increase of FK506 dose Bolus of steroids Recycle
Severe	Severe diarrhea Abdominal pain Abdominal distension Metabolic acidosis Positive blood culture ARDS	Ulceration Mucosal sluffing Bleeding Loss of peristalsis	Mucosal hemorrhage Mucosal sluffing Micro abscess	Increase of FK506 dose Recycle of steroids OKT3
Chronic	Chronic diarrhea Malabsorption Progressive weight loss	Pseudomembrane Hypoperistalsis Loss of mucosal fold Oily intestinal contents	Less inflammatory cells Evident cryptitis Regenerative epithelium Submucosal fibrosis (suggestive but not conclusive)*	Retransplantation

* Histologic diagnosis of chronic rejection was made with the resected graft, which showed arteritis obliterance and mucosal abscess.

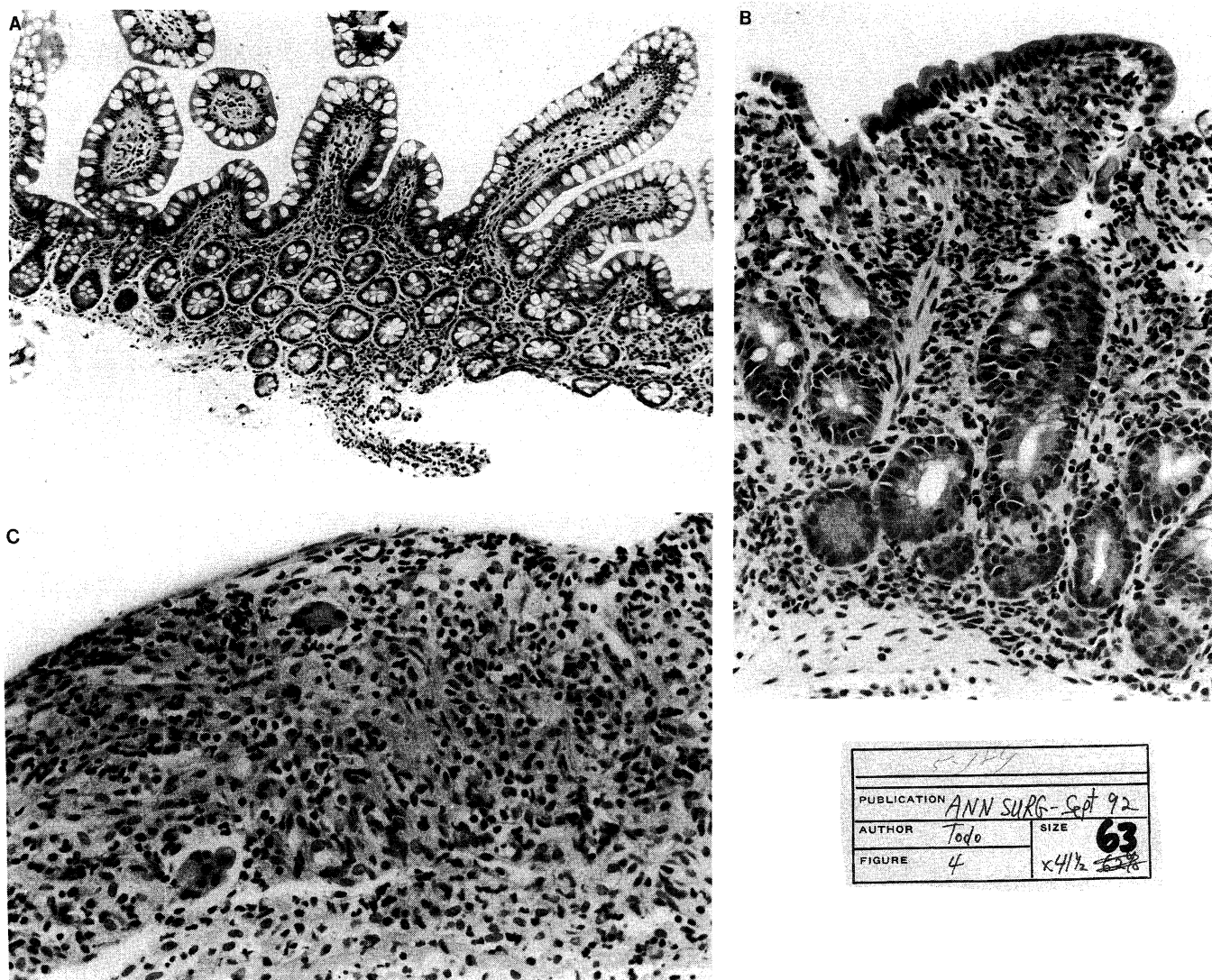


FIG. 4. Histopathology of mucosal biopsy of the intestinal graft. (A) No rejection (H&E, original magnification $\times 192$). (B) Mild rejection (H&E, original magnification $\times 480$). (C) Severe rejection with massive epithelial slough (H&E, original magnification $\times 480$).

Statistics

Data are expressed as the mean and standard deviation. Group comparisons were made by Student's *t* test and chi square analysis.

Results

Survival of Patients

All eight isolated small bowel recipients are alive after 1 to 23 months (Table 1). Three are at home, four are still hospitalized in surgical wards, and one (patient 1), who lost his graft to chronic rejection at 22 months and recently underwent retransplantation, is in the intensive care unit. Four of the eight patients have been liberated from TPN for 1 to 4 months.

Seven of the eight small bowel-liver recipients are well

7 to 21 months after operation. All are TPN free and living at home. Patient 7, a 7-month-old girl, died of sepsis and multiple organ failure after 23 days. She had developed *Pneumocystis carinii* pneumonia on day 2 after operation and an intestinal anastomotic leak on day 4. These complications necessitated a reduction of immunosuppression. Sixteen days after operation, a skin rash appeared on her lower abdomen. Biopsy of the rash had nonspecific histopathologic findings 4 days before her death, but 1 day premortum, repeat biopsy showed classical findings of graft-versus-host disease. There was single keratinocyte necrosis (apoptosis) and infiltration of the skin with lymphocytes of donor phenotype. Graft rejection was never demonstrated in life. Autopsy was not performed.

The multivisceral graft recipient (case 10) is ready to

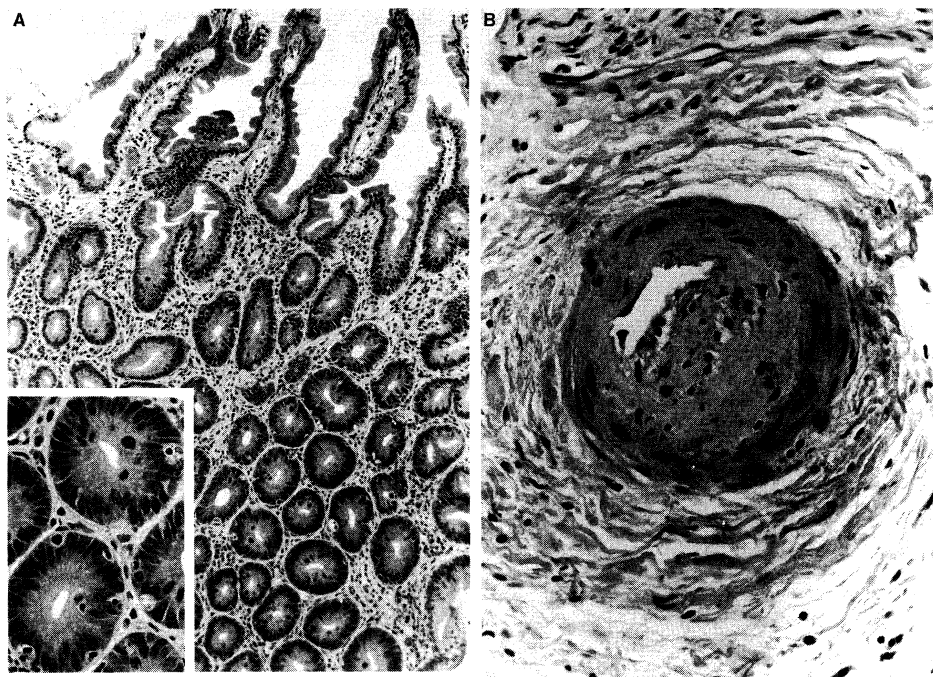


FIG. 5. Histopathology of chronic rejection of the removed intestinal graft. (A) Apoptosis of crypt cells (insert, H&E, original magnification $\times 480$) with sparse inflammatory cell infiltration (H&E, original magnification $\times 192$). (B) Arteritis obliteration seen at the subserosal layer (H&E, $\times 480$).

be discharged on full oral nutrition after staying in the intensive care unit for 2 months because of postoperative pulmonary insufficiency requiring ventilation.

Survival of Grafts

Fifteen of the 17 original grafts remain in place. In addition to the liver-intestinal transplant lost by death (case 6), an isolated intestinal graft was resected after 22 months (case 1) and replaced by retransplantation 3 weeks later. Recovery from the primary transplantation was stormy, with bouts of severe rejection, sepsis, and renal failure, and several later episodes of graft rejection associated with drug noncompliance. Serial intestinal biopsies showed apoptoses of crypt cells with sparse inflammatory cell infiltration, suggesting chronic rejection of the graft (Fig. 4A). An angiogram performed at 19 months demonstrated narrowing of the peripheral mesenteric arteries, which was worse on a repeat study at 22 months, leading to the decision for graft enterectomy. The resected graft had mucosal ulceration, abscesses, and arteritis obliteration (Fig. 4B).

Nongastrointestinal Morbidity

The early convalescence of most of the recipients was prolonged and complicated. Irreversible renal failure developed in patient 1, necessitating cadaver renal transplantation 19 months later, and in patient 10, whose protein S deficiency already had been responsible for renal artery thrombosis and loss of one kidney. A third patient (case 9), who had undergone earlier nephrectomy after a

traffic accident, required temporary hemodialysis after transplantation.

Because of paralysis of the right hemidiaphragm, an intestine-liver recipient (patient 5) required respiratory support for 300 days. Another child (case 4) with the same operation became permanently paraplegic after a lumbar puncture. An adult (patient 3) underwent femoral arterial grafting for treatment of a pseudoaneurysm caused by a femoral arterial puncture.

Gastrointestinal Morbidity

Rejection. Three patients (cases 6, 7, and 12) had no histopathologic evidence of rejection during their follow-up of 23, 234, and 97 days. In the other 14, some evidence of acute rejection was first demonstrated with mucosal biopsy at a mean postoperative time of 15.5 ± 7.8 days (range, 7 to 55). This usually was mild or moderate. Nearly total denudation of the mucosa by severe graft rejection, however, developed on four occasions in three patients (case 1, days 14 and 167; case 4, day 74; case 5, day 137). This was reversed with complete healing within 1 to 2 weeks after a management adjustment. Two courses of OKT3 were given each to patients 1 and 10.

Unexpectedly, the incidence of graft rejection in the first 2 months after isolated small bowel transplantation was lower than after combined liver-intestine or multiorgan transplantation (Table 3). In six of the nine grafts containing liver and intestine (eight liver-intestine and one multivisceral), the incidence of rejection was similar in both organs. Rejection was more prevalent in the liver

TABLE 3. Comparison of Early Postoperative Course* in Recipients After Small Bowel Versus Small Bowel/Liver Transplantation

Graft	Small Bowel	Small Bowel/Liver
Case†	5	7
Pediatric	3	5
Adult	2	2
ICU stay (days)	7.6 (5–14)	63 (3–300)
Hospital stay (mo)	3.9 (1–12)	5.2 (3–10)
Immunosuppression‡		
FK506 (mg/kg/day)		
IV dose	0.09 (0.06–0.12)	0.07 (0.05–0.13)
Oral dose	0.4 (0.2–0.70)	0.2 (0.1–0.5)
Plasma level (ng/ml)	3.0 (1.7–6.2)	1.9 (1.5–2.6)
Steroid (mg/kg/day)		
IV dose	0.6 (0.3–1.0)	0.4 (0–1.0)
Oral dose	0.2 (0–0.3)	0.3 (0–1.2)
Imurane (mg/kg/day)	1.0 (0–0.3)	0.2 (0–1.3)
PGE ₁	4 patients	1 patient
No. of patients requiring adjuvant therapy		
Steroid		
Bolus	4 (80%)	7 (100%)
Recycle	4 (80%)	1 (14%)
OKT3	1 (20%)	0 (0%)
Small bowel rejection		
No. of biopsies	30	29
Histologic rejection		
None	26 (87%)	17 (59%)
Mild to moderate	3 (10%)	12 (41%)
Severe	1 (3%)	0 (0%)
Nutrition		
Enteral feeding, started (days)§	8.8 (5–14)	27.7 (11–37)
TPN, stopped§	30.5 (14–49)	123.1 (45–210)
Infectious episodes		
Viral	1	4
Bacterial (translocation)	3 (2)	7 (3)
Fungal (translocation)	2 (1)	2

* Findings within 2 months after transplantation.

† Includes only patients with data for longer than 2 months (small bowel cases 1, 11, 12, 13, and 14; small bowel–liver cases 2, 3, 4, 5, 7, 8, and 9).

‡ Mean value (range).

§ Statistically significant ($p < 0.05$).

|| Number of episodes in each group of patients.

than in the intestine in the other three patients, however (case 2, 83% versus 27%; case 4, 53% versus 21%; case 5, 85% versus 57%). On the 38 occasions on which both liver and small bowel biopsies were taken simultaneously or closely together, 16 (42%) of the dual specimens had no sign of rejection in either organs, nine (24%) had rejection in both, nine (23%) had rejection only in the liver, and four (11%) had rejection in the intestine only.

Infection. Microorganisms were detected in the blood in eight patients at 21 occasions: *Candida albicans* (one example), enterococcus fecium/fecalis (six examples), coagulase-negative Streptococcus (four), cytomegalovirus (three), influenza hemophilus (one), and gram-positive cocci (six). Bacterial translocation was proven in four patients on six occasions, half of which were associated with rejection: case 1 at day 57; case 2 at days 18 and 30; case 4 at days 7 and 21, and case 11 at day 15. Recipients of isolated small bowel were neither more nor less prone to infectious complications than the recipients of the complex grafts (Table 3).

Small Bowel Function

Nutrition. Total parenteral nutrition was discontinued after 14 to 210 days (89.5 ± 69.7), the average period being much shorter in isolated small bowel recipients than in those with organ combinations (Table 3). All nine pediatric patients had failed to learn (or had forgotten) to eat. Oral feeding had to be taught, and patients 5 and 7 still prefer tube feeding to eating in spite of intensive rehabilitation.

Except for patient 6 (who died) or patients 1, 15, 16, and 17, who were operated on recently, the other 12 recipients are supported nutritionally solely with their functioning grafts. All recipients followed for more than 3 months have maintained or gained body weight after 3 months, with the exception of patient 1, who eventually came to retransplantation (Fig. 6).

Gastrointestinal motility. Gastric emptying in the early postoperative period was delayed from 3 to 12 hours in half of the recipients studied (7/14), but recovered spon-

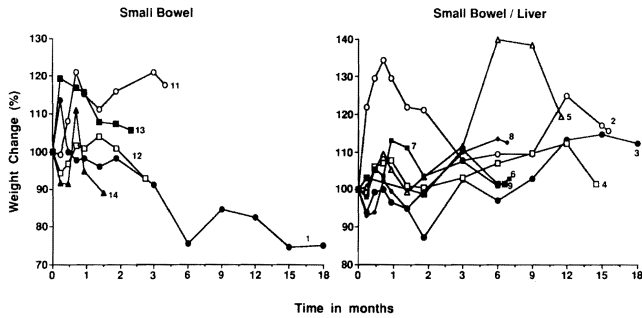


FIG. 6. Body weight changes of the recipients after small bowel transplantation. Numbers indicate cases listed in Table 1. The seemingly poorer weight gain in the isolated small bowel recipients reflects the more recent case accrual and consequent shorter follow-ups. Weight gain in either the isolated small bowel or bowel–liver patients did not start until 2 or 3 months.

taneously after 4 to 6 months. Ten of these recipients had an abnormality of the intestinal graft transit time, which was markedly accelerated (less than 1 hour) in seven or prolonged (more than 3 hours) in the other three. When studied later, these abnormalities were improved.

Absorption. D-xylose absorption tests performed with 12 patients 1 to 22 months after operation were normal in six, slightly abnormal in five, and poor in one (Fig. 7). The amount of the total fecal lipids was usually high at early postoperative period, and fat absorption is still abnormal in some patients as long as a year after transplantation (Fig. 8).

Discussion

There are metabolic and immunologic considerations in planning the transplantation of the intra-abdominal organs. At one time, it was suspected that rejection would

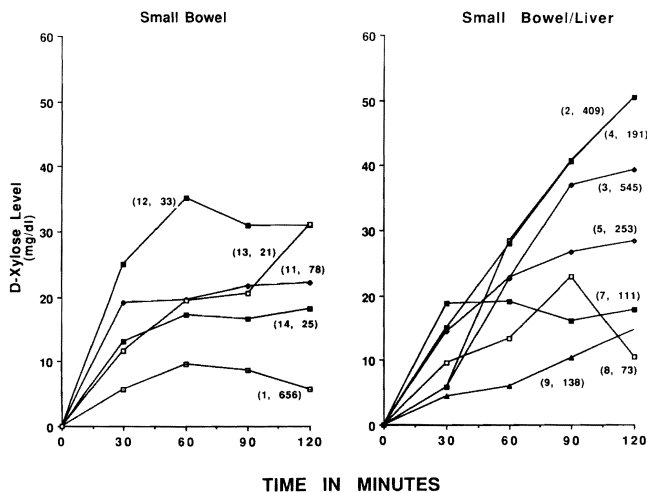


FIG. 7. D-Xylose absorption test in the recipients after small bowel transplantation. Most recent data are shown (case, postoperative days of the study).

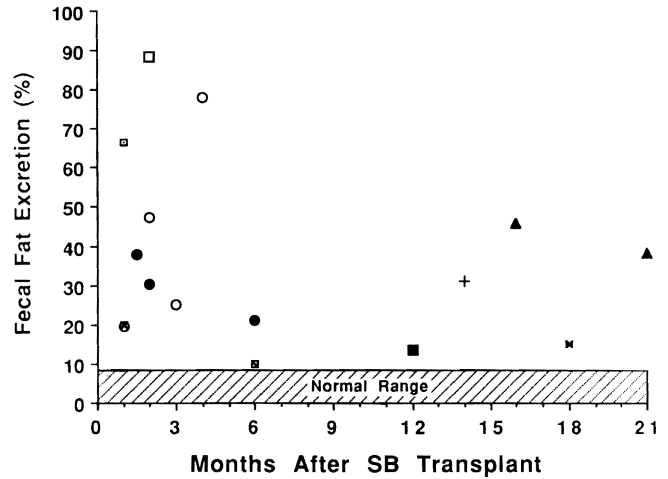


FIG. 8. Fecal fat excretion of the recipients after small bowel transplantation. Multiplication symbols indicate data from the same patient.

be ameliorated with primary delivery of a graft’s venous return through the liver through the portal vein.²⁰ Evidence supporting this hypothesis as it applies to the intestine, however, has not been obtained by direct testing in rats.^{21–23} Thus, efforts to drain the transplanted intestine transportally for immunologic reasons have little justification.

There are significant metabolic reasons, however, to try to have transportal venous drainage. Either the native or the transplanted liver is subject to adverse Eck fistula (portaprival) effects to the extent that the so-called hepatotropic factors in the venous effluent from the pancreas (principally insulin) and intestine (nutrients and enteric hormones) are diverted from it.^{24–26} Consequently, the ability to use techniques that drain the intestinal venous return transportally was noteworthy. In cases in which the intestine was transplanted alone, it was routinely possible to route its venous return through the native liver instead of resorting to the technically more expedient option of mesocaval drainage.²⁷ Similarly, when the intestine and liver were transplanted together, the metabolic objective was systematically met of draining the venous return from the recipient’s pancreas and other residual splanchnic organs, through the transplanted liver.

An important additional question of basic immunologic as well as practical surgical interest is how protective (tolerogenic) a concomitantly transplanted liver is of other organ allografts from the same donor.^{10,28,29} Hepatic tolerogenicity has been confirmed in numerous experimental models and could be used as an argument to replace the liver as an “expediter” for the intestine even though it is normal.^{5,7} The persuasiveness of this proposition has been enhanced by the rejection in the past of almost all reported isolated cadaveric small bowel transplants in humans.

Our experience suggests on the contrary that the less draconian procedure of isolated small bowel transplantation is the procedure of choice if the only need is for the intestine. This would reserve the multivisceral or liver-intestinal operations, as has been our policy, for specific indications such as coexisting liver failure or a hepatic inborn error (exemplified by the protein S deficiency in our case 10). Although in no way interdicting the hepatic tolerogenicity concept, our results indicate that the immunologic advantage of a coexisting liver graft is not an obligatory condition for successful intestinal transplantation. In fact, the greater ease, lower expense, and above all greater safety of the isolated intestinal procedure emerged clearly from our series, which is the first that has become available for such analysis. Realization of the practicality of isolated intestinal transplantation should be an incentive to intervene earlier in selected cases before the advent of the poorly understood secondary hepatic injury that is associated with TPN.

The list of indications for isolated intestinal transplantation in addition to the short gut syndrome already is emerging and so far in our series has included inflammatory bowel (Crohn's) disease, microvillus inclusion disease, intestinal pseudo-obstruction, and a nonresectable desmoid tumor in a patient with Gardner's syndrome. It is too early to predict how good the function will be of the chronically tolerated intestinal graft, whether it is transplanted alone or as part of an organ complex. Nearly normal intestinal allograft function, however, has been described in rats¹⁰ and pigs.³⁰ Dogs had the subnormal fat and d-xylose absorption detected in some of our patients,³¹ but in spite of the imperfect laboratory tests, most of the human recipients have had satisfactory nutrition, which improved with time.

The ability to move forward with intestinal transplantation has been facilitated by FK 506, not only because this drug has been shown by direct testing to provide more potent immunosuppression than cyclosporine for protection of the intestinal graft,⁹⁻¹² but also because its absorption characteristics after oral administration are less influenced by the presence or absence of bile, bile acids³² and by the motility and function of the intestine itself. The oral doses of FK 506 in long-surviving patients necessary to maintain adequate plasma levels were very little different (Table 3) from that in recipients of livers, hearts, or kidney.

As these and previous trials proceeded, some of the assumptions have come into question on which earlier clinical trials of intestinal transplantation were based. For one thing, the monitoring of rejection has proven to be a straightforward exercise, depending on clinical judgment and biopsy studies rather than on any kind of special test. Our procurement procedures also have evolved toward simplicity. Past practices that were omitted included ex-

tensive infusion of cold preservation fluids during procurement, cleaning the lumen of its contents, and maneuvers to weaken the immunologic reactivity of the bowel's large lymphoreticular cell population. This last policy has not resulted in a high incidence of graft-versus-host disease, as some had predicted.

Study of the intestinal graft may help to better understand graft-versus-host disease and its prevention. In rat survivors of intestinal or multivisceral transplantation under FK 506, it was shown that the lymphoid and dendritic cells of the graft were rapidly replaced with similar recipient cells,¹⁰ whereas the donor cells migrated to and nested in recipient lymphoid and other tissues.³³ Apparently these cells are nonreactive in their new locations to the alien tissues in which they reside, and cause neither rejection nor graft-versus-host disease, providing there is effective immunosuppression. The same kind of cell traffic and repopulation has been documented in our human intestinal and multivisceral recipients^{6,34} and probably is a generic phenomenon with the successful allotransplantation and xenotransplantation of all tissues and organs.³⁵ If this latter concept is validated, it will change many concepts and dogmas of transplantation immunology.

References

- Lillehei RC, Goott B, Miller FA. The physiologic response of the small bowel of the dog to ischemia including prolonged in vitro preservation of the bowel with successful replacement and survival. *Ann Surg* 1959; 150:543.
- Starzl TE, Kaupp HA Jr. Mass homotransplantation of abdominal organs in dogs. *Surg Forum* 1960; 11:28-30.
- Grant D. Intestinal transplantation: current status. *Transplant Proc* 1989; 21:2869-2871.
- Starzl TE, Rowe M, Todo S, et al. Transplantation of multiple abdominal viscera. *JAMA* 1989; 261:1449-1457.
- Grant D, Wall W, Mimeault R, et al. Successful small-bowel/liver transplantation. *Lancet* 1990; 335:181-184.
- Todo S, Tzakis AG, Abu-Elmagd K, et al. Cadaveric small bowel and small bowel-liver transplantation in humans. *Transplantation* 1992; 53:369-376.
- McAlister V, Wall W, Ghent C, et al. Successful small intestine transplantation. *Transplant Proc* 1992; 24:1236-1237.
- Goulet O, Revillon Y, Brousse N, et al. Successful small bowel transplantation in an infant. *Transplantation* 1992; 53:940-943.
- Murase N, Kim D, Todo S, et al. Induction of liver, heart, and multivisceral graft acceptance with a short course of FK 506. *Transplant Proc* 1990; 22:74-75.
- Murase N, Demetris Aj, Matsuzaki T, et al. Long survival in rats after multivisceral versus isolated small bowel allotransplantation under FK 506. *Surgery* 1991; 110:87-98.
- Hoffman AL, Makowka L, Banner B, et al. The use of FK 506 for small intestine allotransplantation: inhibition of acute rejection and prevention of fatal graft versus host disease. *Transplantation* 1990; 49:483-490.
- Lee K, Stangl MJ, Todo S, et al. Successful orthotopic small bowel transplantation with short term FK 506 immunosuppressive therapy. *Transplant Proc* 1990; 22:78-79.
- Stern DM, Brett J, Harris K, Nawroth PP. Participation of endothelial cells in the protein C-protein S anticoagulant pathway: the synthesis and release of protein S. *J Cell Biol* 1986; 102:1971-1978.
- Starzl TE, Todo S, Tzakis A, et al. The many faces of multivisceral transplantation. *Surg Gynecol Obstet* 1991; 172:335-344.

15. Casavilla A, Selby R, Abu-Elmagd K, et al. Logistics and technique for combined hepatic-intestinal retrieval. *Ann Surg* (in press).
16. Takaya S, Iwaki Y, Starzl TE. Liver transplantation in positive cytotoxic crossmatch cases using FK 506, high dose steroids, and prostaglandin E₁. *Transplantation* (in press).
17. Todo S, Fung JJ, Starzl TE, et al. Liver, kidney, and thoracic organ transplantation under FK 506. *Ann Surg* 1990; 212:295.
18. Breiter HC, Craig RM, Levee G, Atkinson AJ: Use of kinetic methods to evaluate d-xylose malabsorption in patients. *J Lab Clin Med* 1988; 112:533.
19. Amenta JS. Lipiodol absorption and urinary iodide excretion as a screening test for steatorrhea. *Clin Chem* 1969; 15(4):295-306.
20. Mazzoni G, Benichou J, Porter KA, Starzl TE. Renal homotransplantation with venous outflow or infusion of antigen into the portal vein of dogs or pigs. *Transplantation* 1977; 24:268-273.
21. Murase N, Demetris AJ, Furuya T, Todo S, Fung JJ, Starzl TE. Comparison of the small intestine after multivisceral transplantation with the small intestine transplanted with portal or caval drainage. *Transplant Proc* 1992; 24:1143-1144.
22. Gorczynski RM, Cohen Z, Levy G, Koh I. Comparison of functional activity in host and graft mesenteric lymphoid tissue of rats receiving syngeneic heterotopic small bowel allografts with portal or systemic drainage. *Transplant Proc* 1992; 24:1133-1144.
23. Shaffer D, Diflo T, Love W, et al. Immunologic and metabolic effects of caval versus portal venous drainage in small-bowel transplantation. *Surgery* 1988; 104:518-524.
24. Starzl TE, Porter KA, Francavilla A. The Eck fistula in animals and humans. *Curr Probl Surg* 1982; 20:687-752.
25. Koltun WA, Kirkman RL. Nutritional and metabolic aspects of total small bowel transplantation in inbred rats. *Transplant Proc* 1987; 19:1120-1122.
26. Schraut WH, Abraham VS, Lee KW. Portal versus caval venous drainage of small bowel allografts: technical and metabolic consequences. *Surgery* 1986; 99:193-198.
27. Tzakis AG, Todo S, Reyes J, et al. Piggyback orthotopic intestinal transplantation. *Surg Gynecol Obstet* (in press).
28. Calne RY, Sells RA, Pena JR, et al. Induction of immunological tolerance by porcine liver allografts. *Nature* 1969; 223:472-476.
29. Kamada N. The immunology of experimental liver transplantation in the rat. *Immunology* 1985; 55:369-389.
30. Grant D, Duff J, Zhong R, et al. Successful intestinal transplantation in pigs treated with cyclosporine. *Transplantation* 1988; 45:279-284.
31. Diliz-Perez HS, McClure J, Bedetti C, et al. Successful small bowel allotransplantation in dogs with cyclosporine and prednisone. *Transplantation* 1984; 37:126-129.
32. Furukawa H, Imventarza O, Venkataraman R, et al. The effect of bile duct ligation and bile diversion on FK 506 pharmacokinetics in dogs. *Transplantation* 1992; 53:722-725.
33. Murase N, Demetris AJ, Woo J, et al. Lymphocyte traffic and graft-versus-host disease after fully allogeneic small bowel transplantation. *Transplant Proc* 1991; 23:3246-3247.
34. Iwaki Y, Starzl TE, Yagihashi A, et al. Replacement of donor lymphoid tissue in human small transplant under FK 506 immunosuppression. *Lancet* 1991; 337:818-820.
35. Starzl TE, Demetris AJ, Murase N, et al. Cell migration, chimerism, and graft acceptance. *Lancet* 1992; 339:1579-1582.

DISCUSSION

DR. RONALD W. BUSUTTIL (Los Angeles, California): This presentation represents a major advance in small intestinal transplantation and affirms the pioneering position in transplantation of Dr. Starzl and his colleagues.

We also have been interested in small intestinal transplantation at UCLA and initiated a program in July of 1991. Our first case that I would like to share with you has many similarities to the series reported here. Our recipient was a 19-year-old man with a short gut syndrome secondary to a stab wound to the superior mesenteric artery. A combined liver-small bowel transplant using an ABO-matched, HLA-mismatched allograft was performed under quadruple immunosuppression including OKT-3, cyclosporine, low-dose Imuran, and steroids.

The graft was placed orthotopically with portal drainage of the recipient directed into the donor's portal vein. Severe rejection of both the liver and the intestine occurred on postoperative day 26. Within 24 hours, severe mucosal ulcerations developed that went on to sloughing of the entire mucosa.

[Slide] This shows you the upper gastrointestinal tract during the bout of severe rejection. And you can see there is loss of the feathered edge of the mucosa with a pseudomembrane formation. The episode was refractory to steroids and anti-lymphocyte preparations but reversed with FK506.

His recovery after this episode of rejection was uneventful and he was discharged after 2½ months on total oral feedings and is now under the care of our recorder, Dr. Clyde Barker.

In the interim, we found it very useful to have a jejunal feeding tube as was described by Dr. Todo and his colleagues and also to place a gastrostomy tube. We encountered a very difficult 2-month period of unexplained and refractory gastric paresis, which was also seen, I believe, by the Pittsburgh group. This fortunately subsequently resolved. The J-tubes and the G-tubes, however, were invaluable during this critical period for enteral feedings to bypass the stomach.

Dr. Todo, I would like to ask you three questions. We have also used prostaglandin E₁ in our liver patients, the benefits of which may be achieved from its vasodilatory properties, smooth muscle relaxation, and mild immunosuppressive properties. Could you expand on how the

FK506 prostaglandin cocktail has given superior results and if this specifically applies only to small bowel grafts?

Secondly, there are numerous experimental studies confirming the difficulty of diagnosing small intestinal rejection given the segmental nature of the rejection process. Could you comment on the adequacy of mucosal biopsies in your series for diagnosing small intestinal rejection, and did you find any instances of clinical rejection in the presence of normal biopsies?

Third, what is your explanation of the gastric paresis that you saw in your patients, and was it related to abnormalities in the jejunal pace-makers?

And finally, it is generally acknowledged that the liver provides an immunologically favorable environment for other organs transplanted from the same donor. In your paper, however, you note that the incidence of graft rejection in the first 2 months was lower in isolated intestinal grafts versus multivisceral transplants and combined liver-small intestinal grafts. Additionally, in three of the nine liver-small bowel grafts, the rejection was more severe in the liver than it was in the small intestine. Do you have any theory to explain this, and do you think that it is probably related to the use of FK506?

DR. FELIX T. RAPAPORT (Long Island, New York): President Thompson, members, and guests: I enjoyed both papers, and I want to congratulate Dr. Todo on his outstanding presentation of what may well be an historic paper.

Until recently, cluster and intestinal transplants were considered relatively futile. In fact, I remember many years ago, when Tom Starzl first presented his cluster procedures here, one of our great leaders, Dr. Longmire, arose to question why he bothered. Why did he not just wheel the patient from the donor room to the recipient room, and then trade places? Well, we have now come full swing around. With the advent of new immunosuppressants, we have gradually seen the so-called "forbidden organs" come into the fold and within the range of clinical transplantation. This applies to the cluster procedures, to small intestinal transplants, and to many other procedures to come. To a large extent, this is due to explosive development in our understanding of the immunologic reaction at the efferent and afferent arcs, and to the use of increasingly specific

immunosuppressive agents to control these elements. FK506 is the new prototype; I am sure that many others are still to come.

I wanted to ask Dr. Todo about something far more basic than this. And that is, Dr. Murase in your laboratory has published some fascinating data on the traffic of cells between intestinal transplants, in the rats and the host, with an almost instantaneous exchange of various cells, especially dendritic cells, between donor tissues and the host. I wonder whether you have done any similar studies, in humans, in this series of patients.

I also note that you have now greater success with small intestinal transplants done alone. Have you looked for donor source Kupffer cells in the host, for example? What are your overall thoughts on the induction of unresponsiveness as a result of such traffic, following the lines of Dr. Barker's studies, for example, with the thymus?

DR. LUIS O. VASCONEZ (Birmingham, Alabama): I would like to know the interval of time between warm ischemia and revascularization. In autotransplantation of the intestine, we find that the warm ischemia interval is an important factor in preventing at least mucosal necrosis.

DR. JAMES C. THOMPSON (Galveston, Texas): In line with the last question, I would like to ask, what are the two oldest, longest functioning grafts, and how are they functioning?

DR. BYERS W. SHAW, JR. (Omaha, Nebraska): I congratulate Dr. Todo. I had the pleasure of making rounds with him about a month ago. We should recognize that this is a true clinical series, whereas the rest of us have sort of been dabbling with isolated cases in this field. It is amazing what progress has been made. It is the first time that true progress has been made in this field.

The matter that concerns all of us, which is obvious from the presentation, is that we do not know what the long-term results are going to be. I would like to ask Dr. Todo specifically what his fears are regarding the development of chronic rejection and what strategies he might have in mind to prevent it.

DR. S. TODO (Closing discussion): Dr. Busuttil, thank you very much for your comments and for showing us your interesting case. I believe that the positive results of our intestinal transplantation trial depend primarily on the use of FK506 for post-transplant immunosuppression. I also believe, however, that prostaglandin E₁ administration during the immediate postoperative period has played an important role. Prostaglandin E₁ (PGE₁) has been shown to possess immunosuppressive qualities as well as the ability to protect the kidney from untoward insults. Takaya et al. (Transplantation, in press) found that the patients who were cross-match positive and treated with PGE₁, after liver transplantation, had better patient/graft survival and renal function than those who had a positive cross-match but did not receive PGE₁. Encouraged by these findings, we started to give this agent to intestinal recipients from August 1991. Administration of PGE₁ has made immunosuppressive management rather easy, by decreasing the threat of renal dysfunction caused by FK506. Incidentally, two of our successfully treated patients had positive cytotoxic antibody cross-matches with their donors.

A second crucial improvement, in our experience, is the establishment of guidelines for monitoring and treating graft rejection. As you pointed out, it has been said that intestinal graft rejection occurs segmentally, thereby leading to the frequently expressed opinion that histopathologic diagnosis with biopsy samples is unreliable. To overcome this problem,

we used endoscope-guided biopsies, thus enabling us to identify regions that showed significant abnormality. Even with this method, 30% of the samples had a false-negative finding when the rejection was mild. Therefore, we usually take at least three to five biopsies during each endoscopic procedure.

Regarding the question of delayed gastric emptying in intestinal recipients, we have no idea why it occurs. What we do know is that it is identified between 1 and 4 months after transplantation, at the time efforts at oral feeding are made, and that it disappears spontaneously at around 6 postoperative months. We are now conducting experiments in dogs measuring gastrointestinal motility, intestinal transit time, gastric emptying time, and neuropeptide hormones to try to establish the causative factors.

Concerning the last question by Dr. Busuttil, the finding that the isolated graft recipients had fewer episodes of intestinal graft rejection and a better postoperative course than the combined intestine and liver patients was completely unexpected, because the opposite has been shown experimentally. Of course, we have to observe our patients carefully for a much longer period to determine if the hepatic graft has a tolerogenic effect, but we believe that improved immunosuppressive management of our patients has contributed to this unexpected result. The first patient of our series who had a stormy course after isolated intestinal transplantation 22 months ago is doing much better this time after intestinal retransplantation.

Thank you very much, Dr. Rapaport, for your kind comment and question on the cell traffic phenomenon after intestinal transplantation. Unfortunately, we did not study this phenomenon in all of our patients, but the analysis with the initial four cases and sporadic further cases demonstrated that there is exchange of lymphocytes between the graft and the recipient (Iwaki et al. Lancet 1991; 337:818). Donor cells migrated from the graft into systemic circulation of the recipient after transplantation, representing 5% to 10% of total lymphocytes in the peripheral venous blood. At the same time, it was shown that lymphocytes in the graft were gradually replaced by those of recipient origin. This phenomenon, initially demonstrated by Arnaud-Battandier et al. (Transplant Proc 1985; 17:1440) and thoroughly studied by Murase et al. (Surgery 1991; 110:87), has now been shown not to be unique to the intestinal graft, but common to every solid organ transplantation. Cell traffic is a generic phenomenon.

Regarding Dr. Vasconez's question, intestinal preservation is an important key for successful transplantation. Although the intestine is very sensitive to ischemia, the duration of warm ischemia necessary to perform the vascular anastomoses does not seem crucial. The time span from when the graft is brought up to the operating table to the time of graft revascularization is brief, usually 30 minutes or less. We believe that the duration of graft preservation as well as the warm ischemic time are critical factors. The grafts that were preserved for more than 7 hours in the University of Wisconsin solution tended to show more preservation injury by histologic study of postreperfusion mucosal biopsies.

Regarding the question by Dr. Shaw, the prevention of chronic intestinal rejection is one of the objectives currently being pursued in our experimental transplantation laboratory. Although the new immunosuppressive agent, FK506, has made it feasible to perform clinical intestinal transplantation, I believe that we have to bring in a third drug to refine our immunosuppressive regimen, partly for that purpose. We are now doing experiments to control chronic or humoral rejection, by combining FK506 with other newly developed agents that suppress both T- and B-cell proliferation by inhibiting DNA synthesis.

Dr. Thompson, the longest graft survival in our series is 22 months after isolated intestinal transplantation and 20 months after intestine and liver transplantation.