

1507

# Disturbance of Microcirculation Associated With Prolonged Preservation of Dog Livers Under University of Wisconsin Solution

H. Furukawa, Y.M. Wu, Y. Zhu, M. Suzuki, S. Todo, and T.E. Starzl

RECENTLY we reported that, in human liver transplantation, a preservation period of greater than 20 hours caused the rate of graft failure to increase nonlinearly.<sup>1</sup> Even with University of Wisconsin (UW) solution, there is a finite limit to the permissible time of cold storage of livers. In this study, we investigated whether microcirculatory disturbance during and after preservation is correlated to cold ischemia and graft outcome.

## MATERIALS AND METHODS

Orthotopic liver transplantation in dogs was performed by the method described previously,<sup>2</sup> but with minor modification. Inbred female beagle dogs weighing 9 to 13 kg were used for recipients, and 7- to 10-kg dogs were used for donors. The donor liver was perfused in situ with 2 L of UW solution before orthotopic transplantation, with the preservation period of 0 hours: immediate transplantation (group 1, n = 7), 24 hours (group 2, n = 7), or 48 hours (group 3, n = 7). Two-week animal survival was determined.

In separate acute experiments, hepatic blood flow, microcirculation, and histology were studied at the end of preservation and shortly after graft reperfusion for preservation periods of 0 hours: immediate transplantation (group 1, n = 9), 24 hours (group 2, n = 9), and 48 hours (group 3, n = 9). The measurement of hepatic artery and portal vein flow was done with an Ultrasonic Blood Flowmeter (Model T-201, Transonic Systems Inc, Ithaca, NY). Measurements were performed at 1 and 2 hours after graft revascularization and results were expressed as mL/min/g of wet graft weight. The microcirculation was studied anatomically with the Microfil technique. After the hepatectomy, 20 mL of the red Microfil silicon rubber compound (Flow Tek, Inc, Boulder, Colo) was slowly infused through the hepatic artery. White Microfil (100 mL) was manually infused through the portal cannula, followed by 30 mL yellow Microfil compound.<sup>3</sup> The liver was stored in 25% alcohol for 1 day, and then processed every other day with 50%, 75%, 95%, and 100% alcohol. A 1-mm width of the liver was sliced and cleared with methylsalicylate for an additional 24 to 48 hours. The slice was examined under a stereoscopic dissecting microscope. A piece of the left lobe was excised for histologic study. Tissues were fixed with 10% formalin and stained with hematoxylin-eosin. Student *t* test and analysis of variance were used for the comparison of groups, and a *P* value less than .05 was considered significant.

## RESULTS

In groups 1 and 2, 6 out of 7 dogs survived for 14 days (86%). One dog in group 1 died 7 days posttransplant of intussusception and the dog in group 2 died 1 day posttransplant due to pulmonary edema. In group 3, all dogs died within 2 days, with pulmonary edema being the main cause of death (bloody ascites was seen in 2 dogs). Groups 1 and 2 showed significantly better survival than group 3

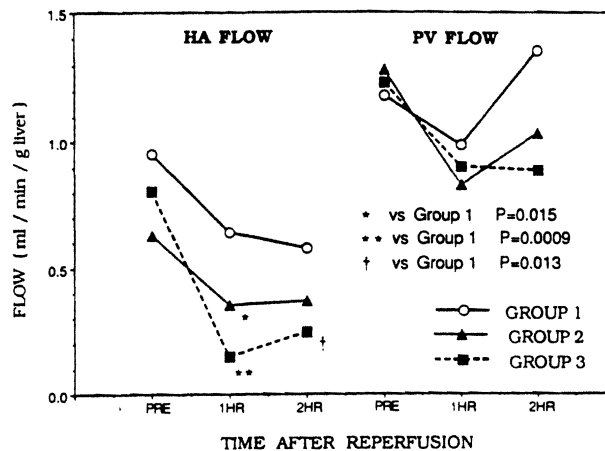


Fig 1. Hepatic arterial and portal vein blood flow before cross-clamping the donor (PRE), and 1 hour (1HR) and 2 hours (2HR) after reperfusion of the recipient.

(*P* < .0001). In the blood flow study, a significant reduction of the hepatic arterial flow was observed in groups 2 and 3 at 1 hour, and in group 3 at 2 hours after reperfusion (Fig 1). In the Microfil study, at the end of preservation, group 1 showed normal sinusoid, and groups 2 and 3 showed spots of dilated sinusoidal area scattered through 30% and 50% of the entire field, respectively, with filling of periportal space. After reperfusion, group 1 sinusoid was well preserved except in 2 cases, which showed scattered irregular spots with lymph vessels and periportal stain. Half of the area of group 2 sinusoid showed significant dilatation, fusion, and disruption, although the rest of the sinusoid was preserved with no remarkable change. In group 3, most of the sinusoid showed prominent dilatation, fusion, and disruption. The periportal area, in group 2 and group 3, showed cylindrical filling in most of the middle or small portal tract. The percentage of irregular area of sinusoid for groups 1, 2, and 3 were  $5.8\% \pm 9.3\%$ ,  $47.5\% \pm 21.2\%$ , and  $88.3\% \pm 13.7\%$  respectively. There were statistical differences among the three groups (1 vs 2: *P* = .0007; 2 vs 3: *P* = .0008; 1 vs 3: *P* = .00001).

From the Pittsburgh Transplant Institute, University of Pittsburgh, Pittsburgh, Pennsylvania.

Supported by research grants from the Veterans Administration and Project Grant No. DK 29961 from the National Institutes of Health, Bethesda, Maryland.

Address reprint requests to Thomas E. Starzl, MD, PhD, 5C Falk Clinic, 3601 Fifth Avenue, Pittsburgh, PA 15213.

© 1993 by Appleton & Lange  
0041-1345/93/\$3.00/+0

Groups 2 and 3 had high uptake into the periportal area in the medium and small portal veins compared with group 1. The hepatic artery and bile plexus were well visualized in the portal triad of each group, without statistical differences. Histologically, no morphologic difference could be detected between the groups prior to revascularization. After revascularization, no morphologic change was seen in group 1 except for slight swelling of sinusoid lining cells and minimal vacuola in hepatocytes. However, groups 2 and 3 showed mild to moderate damage of the sinusoid lining cells after revascularization. Group 2 also showed pyknotic nuclei and vacuola in hepatocytes in half of the cases, although necrosis of hepatocytes was rare. In group 3, vacuola in hepatocytes were detected in all cases, and necrosis of hepatocytes in central areas was prominent compared with group 2.

#### DISCUSSION

There was a marked reduction of animal survival after transplantation of liver grafts preserved for a prolonged

period. However, no significant changes, except for some patchy dilatation of sinusoids, were found in groups 2 and 3 by Microfil analysis at the end of the preservation period. After reperfusion, a steep decline of hepatic arterial flow and structural disturbance of the microcirculation were observed. The severity of these changes was correlated with preservation time. These results suggests that, as with kidney preservation,<sup>4</sup> protection from microcirculatory disturbance appears to be an important factor for improved liver preservation.

#### REFERENCES

1. Furukawa H, Todo S, Imventarza O, et al: *Transplantation* 51:1000, 1991
2. Todo S, Kam I, Lynch S, et al: *Semin Liver Dis* 5:309, 1985
3. Lien WM, Ackerman NB: *Surgery* 68:334, 1970
4. Ueda Y, Todo S, Imventarza O, et al: *Transplantation* 46:913, 1989