

1685

The Latest Advances In Liver Transplantation At The Pittsburgh Transplantation Institute:

Evolution Of FK506, Liver-Intestinal Transplantation, Clinical Xenotransplantation, And The Induction Of Graft Acceptance

IGNAZIO ROBERTO MARINO, M.D., HOWARD R. DOYLE, M.D.

KAREEM ABU-ELMAGD, M.D., CARLO L. SCOTTI-FOGLIENI, M.D.

RAFAEL MAÑEZ, M.D., ANDREAS G. TZAKIS, M.D.

SATORU TODO, M.D., JOHN J. FUNG, M.D., PH.D.

THOMAS E. STARZL, M.D., PH.D.

PITTSBURGH TRANSPLANTATION INSTITUTE, UNIVERSITY OF PITTSBURGH MEDICAL CENTER AND THE VETERANS ADMINISTRATION MEDICAL CENTER, PITTSBURGH, PA

During the past 30 years orthotopic liver transplantation (OLT_x) has become a highly successful form of therapy,¹⁻⁷ and as of this writing it is being performed at more than 100 institutions in the U.S., and a similar number in Europe. This is testimony to the great advances achieved in this field since the 1960s and 1970s, when there were essentially only two places actively engaged in liver transplantation.^{3,8}

Essential to its success have been the technical refinements introduced during the last three decades,^{7,9} which have allowed many surgeons around the world to be able to do the procedure safely. Liver transplantation is still considered as one of the most complex operations, and therefore the margin of error is small and attention to technical detail is crucial to a satisfactory outcome. This is magnified in importance since OLT_x, unlike kidney, heart, pancreas and intestinal transplantation, lacks a back-up system, such as dialysis, ventricular assist device, insulin or total parenteral nutrition. Thus, the smallest mistake in the surgical management of the patient may prove fatal.

In this chapter we will describe four major clinical advances in the field of liver transplantation, achieved between 1989 and 1994 at the Pittsburgh Transplantation Institute. First was the introduction of the novel immunosuppressive drug FK506, which after extensive *in vitro* and *in vivo* studies was approved by the Food and Drug Administration on April 8, 1994, and is now available for clinical use in the U.S. Second, the feasibility of combined liver-intestinal and multivisceral transplantation as a surgical treatment for patients with simultaneous liver and intestinal failure. Third, the definition of the biological basis of clinical liver xenotransplantation, as well as the strategies for future investigations. Fourth, the attempts to induce graft acceptance (donor-specific nonreactivi-

ty) by cell augmentation with simultaneous donor bone marrow infusion.

Each of these four advances will be examined and discussed separately herein. Data are presented as the mean \pm SD. Survival curves for both patients and grafts were estimated by the Kaplan-Meier method, and the comparison among the different cohorts within each population was done by a generalized Wilcoxon (Breslow) test.

FOUR YEARS EXPERIENCE WITH FK506 IN LIVER TRANSPLANTATION

FK506 (tacrolimus, Prograf®), the first baseline immunosuppressive drug to be certified by the FDA in 11 years, became available in pharmacies in the United States on June 1, 1994. Following 3 years of preclinical research in Chiba,¹⁰

¹⁵ Pittsburgh,¹⁶⁻²¹ Cambridge,²²⁻²⁴ and elsewhere, the drug was first used clinically in our center in February, 1989, to successfully treat patients who were undergoing intractable rejection of their liver allografts despite maximum cyclosporine-based therapy.²⁵ A few months later, extensive trials were begun with FK506 as the primary immunosuppressant, for recipients of all of the commonly transplanted organs.^{26,27} We report here our experience in 1,153 consecutive patients who underwent primary liver allografts under FK506 therapy. The biological effects of this agent, its pharmacokinetics, and assay methods are fully described elsewhere.^{28,32}

PATIENTS AND METHODS

From August 18, 1989, through August 1, 1993, 1,153 consecutive patients underwent primary OLTx at the Pittsburgh Transplantation Institute, and received FK506 as the primary immunosuppressive agent. Of these, 971 (84%) were adults, while 182 (16%) were children. The mean age was 51 ± 12 years (range: 18-76) for adults and 6 ± 6 years (range: 0.2-17.8) for children. Among the adults, 251 (26%) were over 60 years of age. Table 1 lists the indication for OLTx, based upon the final pathological diagnosis of the explanted liver. Retransplantation was required in 138 (12%) patients; 122 had a second transplant, 15 had a third transplant, and one had 4 grafts. The survival analyses were based on follow-up until October, 1993.

There were 612 patients transplanted between February 19, 1990 and December 21, 1991. Seventy-nine patients were part of a randomized trial that was conducted during that period, comparing cyclosporine to FK506, while the remaining 533 patients were excluded from randomization. The criteria for exclusion were: age < 18 or > 60, positive HBsAg, malignancy, multiple organ transplantation, renal failure, active infection, coma, significant heart or lung disease, previous hepatobiliary and/or portal hypertension surgery, unsatisfactory recipient operation, and liver allograft of uncertain quality.³³ The differences between the randomized and non-randomized patients are summarized in Table 2. The initial phase of the study was carried out during our early learning curve, in which the daily induction doses were two or three times greater than those currently recommended.^{30,34-36} Our present policy is to give FK506 initially as a con-

	n	(%)
Nonalcoholic cirrhosis	384	(33)
Alcoholic cirrhosis	210	(18)
Autoimmune disorders	204	(18)
-autoimmune hepatitis	38	
-primary biliary cirrhosis	92	
-primary sclerosing cholangitis	74	
Biliary atresia	93	(8)
Genetic disorders	30	(3)
Primary liver cancer	81	(7)
Fulminant Failure	34	(3)
Miscellaneous	117	(10)
TOTAL	1,153	

Table 1: Indications for primary liver transplantation with FK506 as the primary immunosuppressive agent, at the Pittsburgh Transplantation Institute.

	Nonrandomized	Randomized
	(n=533) n (%)	(n=79) n (%)
Number of patients		
Adults	429	79
Children	104	0
OLTx II	70	5
OLTx III	6	0
Number of Grafts	615	84
Liver Disease		
Nonalcoholic cirrhosis	15 (28)	27 (34)
Alcoholic cirrhosis	92 (17)	28 (35)
Autoimmune disorders	78 (15)	17 (22)
Biliary atresia	59 (11)	2 (3)
Genetic disorders	14 (3)	1 (1)
Tumor	55 (10)	0 (0)
Fulminant failure	23 (4)	0 (0)
Others	61 (12)	4 (5)

Table 2: Clinical features of the randomized and non-randomized patients who underwent primary liver transplant between February 19, 1990 and December 21, 1991 under FK506 (Tacrolimus, Prograf®).

tinuous intravenous infusion over 24 hours, at a dose of 0.05 mg/kg. The conversion from intravenous to oral therapy is usually made without any overlap, with a starting oral dose of 0.1 to 0.15 mg/kg twice a day. Dose adjustments were made in the presence of rejection, adverse drug reactions (with special emphasis on nephrotoxicity and neurotoxicity), infection, and according to the functional status of the graft,³⁴ and always with close attention to the plasma trough levels.

One gram of methylprednisolone was invariably administered intravenously immediately after graft reperfusion. Patients were then placed on 20 mg of prednisone daily and, in the absence of rejection, the dose was gradually reduced over several weeks. Quite frequently, the prednisone was eventually stopped altogether. The first 58 patients, and those who had a strong positive cytotoxic crossmatch, were given a 5-day methylprednisolone taper, starting at 200 mg/day on the first postoperative day and reaching 20 mg/day by the sixth postoperative day. Steroid doses were scaled down appropriately in children. Prostaglandin E₁ (Prostin[®]) was added to the immunosuppressive cocktail of some patients during the first postoperative week (37). Also, a low dose of azathioprine (0.5-2 mg/Kg/day) was given to about 10% of the patients at some time during the postoperative period.³⁸

If rejection was documented it was treated with an increase in the maintenance dose of FK506, and a one gram bolus of either methylprednisolone or hydrocortisone. A steroid recycle and/or, more rarely, a 5-day course of OKT3 (5-10 mg/day) was given to patients with moderate to severe rejection episodes.

RESULTS

With a mean follow-up of 22 ± 15 months (range: 3-49 months), the over-

CAUSES	n	(%)
Infections	99/1,153	(9)
Graft Failure	24/1,153	(2)
Malignancy	21/1,153	(2)
Cardiovascular	18/1,153	(1)
Others	46/1,153	(4)
Unknown	25/1,153	(2)
TOTAL	233/1,153	(20)

Table 3: Causes of death after primary liver transplantation under FK 506 (Tracolumis, Prograf[®]).

all actuarial patient survival rates were 90%, 87%, 83%, and 75% at 3, 6, 12 and 48 months, respectively (Figure 1). Out of the 1,153 OLTx recipients, 233 (20%) died for various reasons, which are listed in Table 3. The total allografts were 1,308 and 155 (13%) were replaced. However, rejection was the cause of failure for only 6 grafts. The overall graft survival was 81%, 78%, 74%, and 65% at 3, 6, 12, and 48 months, respectively (Figure 1).

As expected, the highly selected ran-

domized group had significantly better patient (p=0.006) and graft (p=0.001) survivals than the non-randomized group (Figure 2). The 2-year patient survivals were 91% and 76%, with graft survivals of 88% and 67%, for the randomized and non-randomized groups, respectively. The survival differences reflect the cumulative detrimental effects of the exclusion criteria that were used for randomization. Patients suffering from either parenchymal or cholestatic liver pathology had high long-term survival rates with our

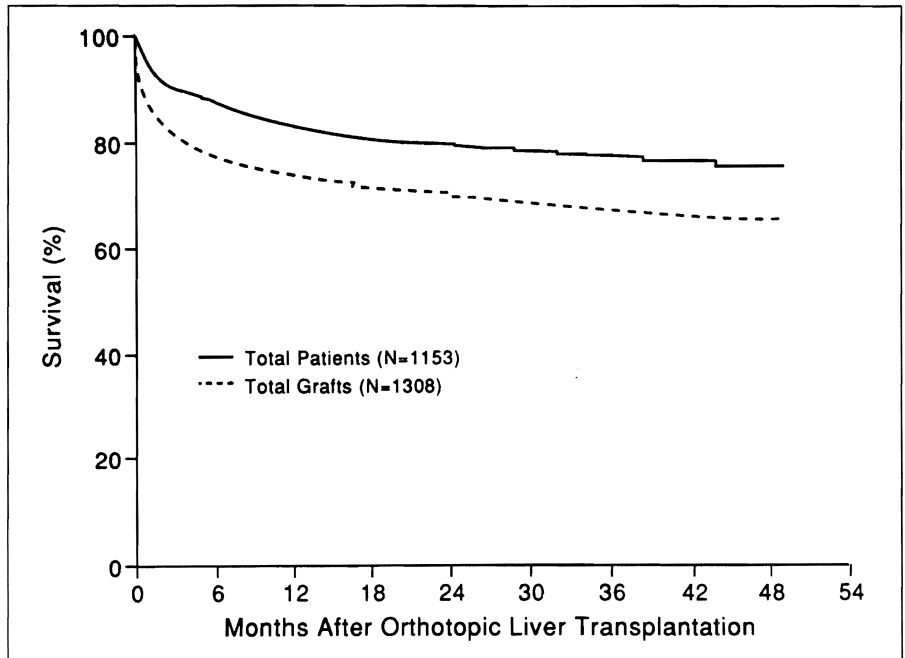


Figure 1: Kaplan-Meier actuarial patient and allograft survival for primary liver transplant recipients who received FK506 as the primary immunosuppressive agent, at the Pittsburgh Transplantation Institute, between August 8, 1989 and August 1, 1993. (From: Abu-Elmagd K, Bronsther O, Jain A, Irish W, Fung JJ, Ramos H, Marino IR, Dodson F, Selby R, Doyle H, Furukawa H, Gayowski T, Nour B, Reyes J, Pinna A, Rao A, Fontes P, Casavilla A, Jabbour N, Marsh W, Tzakis A, Todo S, Iwatsuki S, Starzl TE. Recent advances in hepatic transplantation at the University of Pittsburgh. In: "Clinical Transplants, 1993" Terasaki P.I., ed., 137-152, published by UCLA Tissue Typing Laboratory, 1000 Veterans Avenue, Los Angeles, California, 90024. Used by permission).

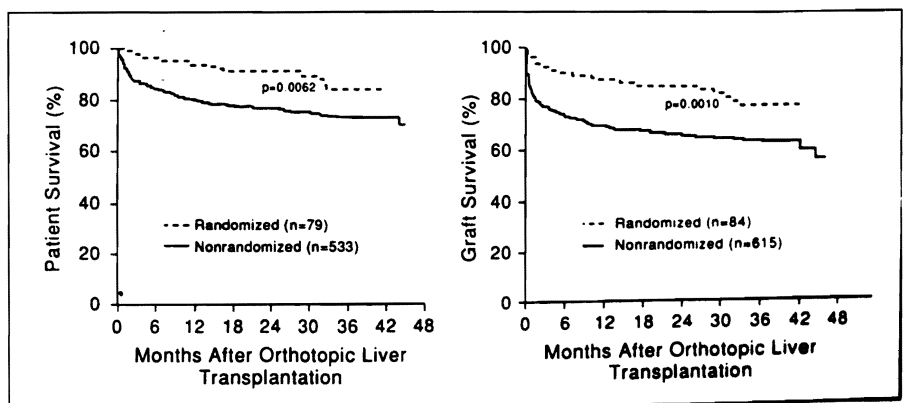


Figure 2: Kaplan-Meier actuarial patient (left) and allograft (right) survival for primary orthotopic liver transplant recipients which were transplanted during the time of the randomized study (February 1990-December 1991). (From: Abu-Elmagd K, Bronsther O, Jain A, Irish W, Fung JJ, Ramos H, Marino IR, Dodson F, Selby R, Doyle H, Furukawa H, Gayowski T, Nour B, Reyes J, Pinna A, Rao A, Fontes P, Casavilla A, Jabbour N, Marsh W, Tzakis A, Todo S, Iwatsuki S, Starzl TE. Recent advances in hepatic transplantation at the University of Pittsburgh. In: "Clinical Transplants, 1993" Terasaki P.I., ed., 137-152, published by UCLA Tissue Typing Laboratory, 1000 Veterans Avenue, Los Angeles, California, 90024. Used by permission).

immunosuppressive protocol based on FK506, as clearly shown in Figure 3. The need for retransplantation was significantly reduced, being only 12%, and the actuarial patient survival after retransplantation was 75% at 3 months and 54% and at 2 years. We attribute the high survival rate (82% at 12 months) in patients undergoing OLTx for fulminant hepatic failure to our current policy of intensive monitoring of intracerebral blood flow and intracranial pressure, with interventions aimed at maintaining intracranial pressure within normal limits, in addition to the therapeutic advantage offered by FK506 treatment.³⁹ Patients with a primary liver tumor had the lowest long-term survival, 72% at one year and 59% at 2 years, similar to that reported in both the cyclosporine era⁴⁰ and the beginning of the FK506 era.⁴¹ The most common cause of death was recurrence of the primary tumor, despite the use of adjuvant chemotherapy.

We reported elsewhere the details regarding the incidence and treatment of rejection episodes in primary OLTx patients under FK506 immunosuppression.⁴² However, it should be emphasized that the lower incidence of rejection with FK506 was in the face of overall lowered corticosteroid use (nearly half of the OLTx patients were steroid free by

the third post-transplant month). Other aspects of the Pittsburgh experience with the use of FK506 as a primary immunosuppressant, like drug toxicity, development of opportunistic infections, and drug interactions, as well as other clinical observations, are published elsewhere.⁴³⁻⁵¹

THREE YEARS EXPERIENCE WITH COMBINED LIVER-INTESTINAL AND MULTIVISCERAL TRANSPLANTATION

The first experimental intestinal and multivisceral transplantations⁵²⁻⁵⁴ were performed over three decades ago. However, for 30 years the intestine was considered to be a "forbidden organ" because of the high incidence of graft loss, either due to technical, immunological, or infectious complications.⁵⁵⁻⁵⁷ The demonstration, in clinical liver transplantation, of the great efficacy of FK506, and the definition of its role in experimental multivisceral transplantation^{58,59} justified, in 1990, a renewed interest in clinical liver-intestinal and multivisceral transplantation.^{60,61}

PATIENTS AND METHODS

Our report is based on our experience with the first consecutive series of

patients that underwent transplantation of a combined, in continuity, liver-intestinal bloc (21 patients), or of a multivisceral cluster of abdominal organs (8 patients, 2 of whom died during surgery, before the organs could be implanted). The general term "multivisceral transplantation" refers to a class of transplants involving the entire small bowel, transplanted en-bloc with or without one or more segments of the gastrointestinal tract (stomach, duodenum, or colon), and with or without one or more solid upper abdominal organs (liver or pancreas). The multivisceral transplants reported here included liver, pancreas, stomach, duodenum, and small bowel. We will limit most of our discussion to the 27 patients that survived the operation.

There were 11 adults and 16 children, transplanted between July 24, 1990, and April 15, 1993. Most patients had end-stage liver disease, with a mean preoperative serum bilirubin of 19 ± 14 mg/dl. Table IV summarizes the etiologies of the intestinal failure and the indications for combined liver-intestinal or multivisceral transplantations in this group of patients. All donors were ABO identical with the recipients, but HLA matching was totally random and uniformly poor. The lymphocytotoxic crossmatch was positive in 2 of the 21 combined liver-intestinal recipients. No attempts were made to alter the graft's immunogenicity by manipulating its lymphoreticular tissue with anti-lymphocytic immunoglobulins (ALS, ALG, OKT3), or with other immunomodulators (immunosuppressive drugs or irradiation) administered to the donor or to the graft. The details regarding surgical technique have been reported elsewhere.^{60,62} In the present series, all donors were < 50 years of age (although no age limits have been set for intestinal donors, and we evaluate every donor for possible intestinal donation).⁶³ There were no non-heart beating donors.

The extremely complex management required by this unique group of patients has been reported in detail.^{64,65} FK506 has been the basic immunosuppressant in this clinical series, along with steroids and prostaglandin E₁. Immunosuppressive therapy of ongoing acute cellular rejection of multivisceral grafts includes the same drugs used for induction and maintenance immunosuppression (FK506 and steroids), with the occasional addition of monoclonal anti-

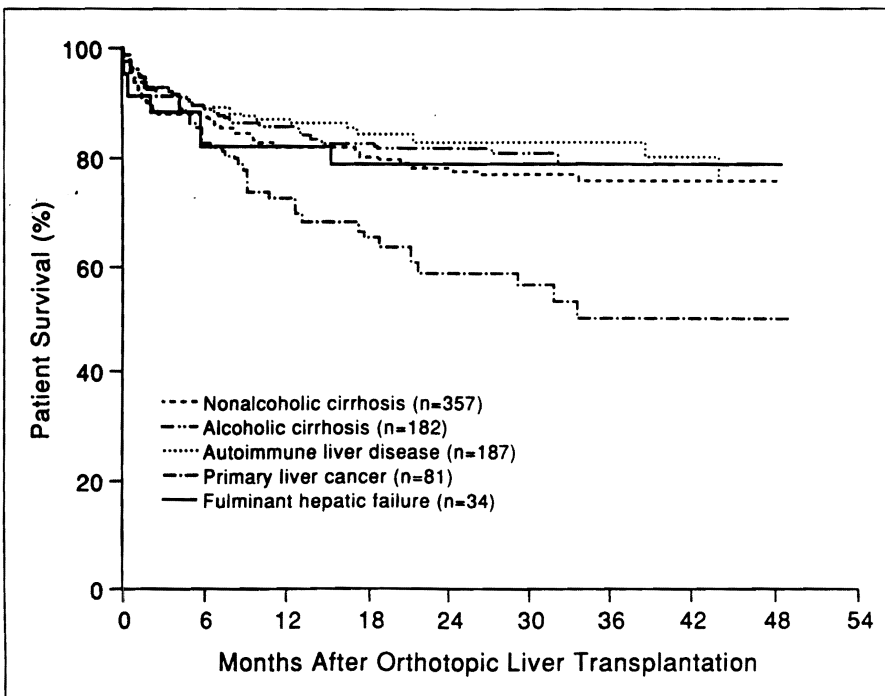


Figure 3: Kaplan-Meier actuarial patient survival for different liver transplant recipient groups, stratified according to the pathology of the primary liver disease. All patients received FK506 as the primary immunosuppressive agent. (From: Abu-Elmagd K, Bronsther O, Jain A, Irish W, Fung JJ, Ramos H, Marino IR, Dodson F, Selby R, Doyle H, Furukawa H, Gayowski T, Nour B, Reyes J, Pinna A, Rao A, Fontes P, Casavilla A, Jabbour N, Marsh W, Tzakis A, Todo S, Iwatsuki S, Starzl TE. Recent advances in hepatic transplantation at the University of Pittsburgh. In: "Clinical Transplants, 1993" Terasaki P.L., ed., 137-152, published by UCLA Tissue Typing Laboratory, 1000 Veterans Avenue, Los Angeles, California, 90024. Used by permission).

bodies (OKT3). Drug dosage and route of administration are adjusted according to the severity of the rejection, assessed mainly by a histological grading scale. Intestinal rejection can impair FK506 absorption, with resultant inadequate trough plasma levels. Consequently, optimization of FK506 trough levels, targeting 3-5 ng/ml, should be accomplished by either increasing the baseline enteral dose or by intravenous supplementation. Adequate and prompt immunosuppressive treatment of ongoing acute cellular rejection of multivisceral grafts is usually successful.

RESULTS

Patient Survival

As of June 14, 1994 (18-47 month follow-up), 14 out of the original 29 patients (48.3%) had died. Of the 12 patients that died after surviving the operation, ten had received a combined liver-intestine, while two were multivisceral recipients. The causes of death in the liver-intestine group were either technical complications (n=3), opportunistic infections (n=2), uncontrolled graft rejection (n=2), or disseminated post transplant lymphoproliferative disease (n=3). The two postoperative deaths in the multivisceral group were caused by post transplant lymphoproliferative disease, diagnosed post-mortem, and sepsis with multiple organ failure. Actuarial patient survival was 72.4%, 65.5%, and 58.6% at 6, 12, and 24 months, respectively (Figure 4).

Graft Survival

Figure 5 shows the actuarial graft survival for 29 allografts in 27 patients (2 patients underwent removal of the complete organ block and retransplantation). Graft survival was 70%, 63.3% and 56.7% at 6, 12, and 24 months, respectively. One graft was lost due to lymphoproliferative disease, another was lost to rejection (both were liver-intestine); there were two partial losses: a liver (retransplanted), and a pancreas. All other grafts were lost due to patient death.

Immunological Complications

Rejection. Monitoring of liver-intestine and multivisceral graft rejection is based on clinical, endoscopic, histopathological, radiological, and immunological criteria.^{64,66-68} Clinical criteria are the keystone for early diagnosis of acute rejection of the intestinal

graft. Unlike rejection of other isolated solid organ allografts (e.g., heart, lung, liver, kidney, pancreas), whose diagnosis is mainly made by biopsy and/or functional and laboratory tests, the diagnosis of acute intestinal rejection is primarily based on clinical criteria, which usually present first. Therefore, clinical monitoring and careful examination of the intestinal graft stoma and

its output are essential. Due to disruption of the normal intestinal mucosal barrier, bacterial and/or fungal translocation can take place, with subsequent septic complications and/or ARDS-like syndromes.

Routine endoscopic surveillance, together with multiple selective biopsies, are usually performed by terminal ileoscopy, although upper endoscopy is

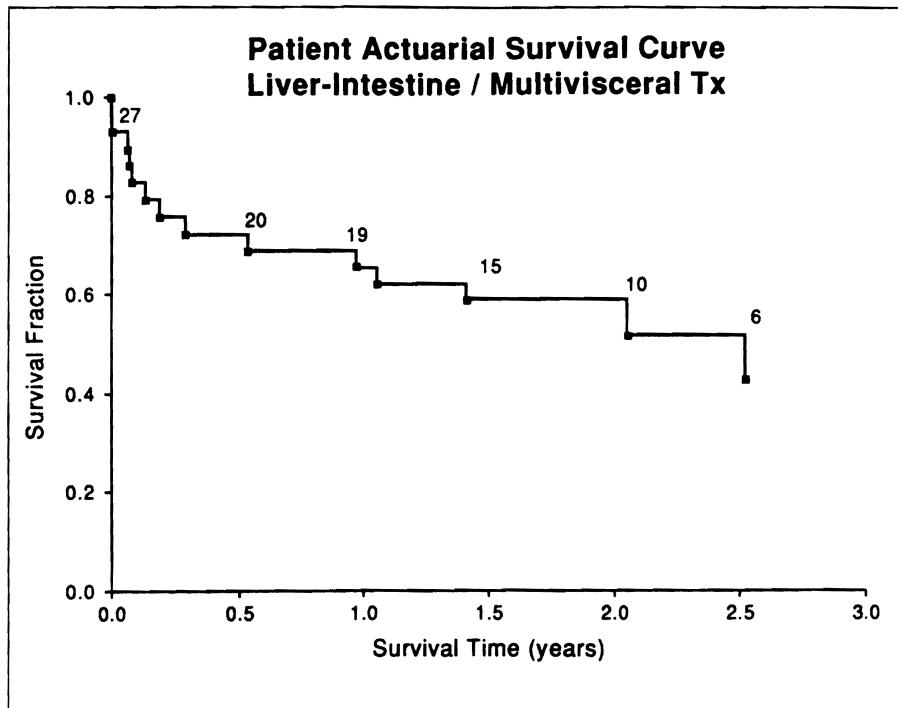


Figure 4: Kaplan-Meier actuarial patient survival for the 27 patients which received either combined liver and intestinal transplants (n=21), or a multivisceral cluster of abdominal organs (n=6).

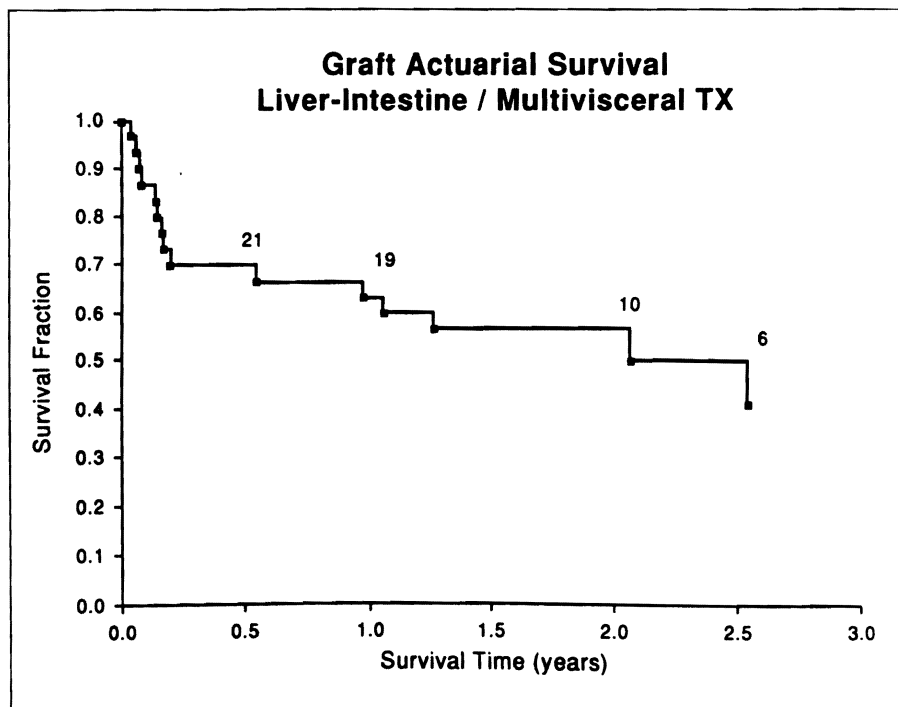


Figure 5: Kaplan-Meier actuarial graft survival for 29 allografts in 27 patients.

also sometimes done. They are done twice a week for the first month, once a week for the next two months, monthly for the next three months, and every 3-6 months, or whenever clinically indicated, thereafter.

In the present series, the incidence of intestinal allograft rejection was much higher than that of the liver allografts. In fact, whereas 16 patients did not have any rejection of the liver graft, only 2 (both recipients of combined liver-intestinal grafts) were free of clinical and histopathological signs of intestinal rejection. The mean postoperative time to the first episode was 22 ± 34 days for the combined liver and intestine, and 15 ± 7 days for the multivisceral allografts. On 88 occasions on which both liver and small bowel biopsies were taken simultaneously or closely together, 47 (53%) of the dual specimens had no signs of rejection in either organs, 12 (14%) had rejection in both, 15 (17%) had rejection only in the liver and 14 (16%) had rejection in the intestine only. Chronic rejection was the cause of graft failure in one adult, with a strong positive cytotoxic crossmatch, who received a combined liver-intestine.

Graft-Versus-Host-Disease (GVHD) — Monitoring of GVHD is

done by clinical examination (fever, skin rash, septic-like syndrome), standard histology, immuno-histochemical techniques (immuno-staining, sex identification after fluorescence-in-situ-hybridization-FISH) and PCR-karyotyping ("DNA fingerprinting"). With these procedures it is possible to differentiate migrating immunocompetent cells from the donor (donor "passenger leukocytes") from recipient cells, as well as to document the immunological injury of the recipient tissues by the infiltrating donor cells. Inadequate immunosuppression is a major risk factor for GVHD. Using standard histology and in situ hybridization techniques, GVHD was unequivocally diagnosed in only one combined liver-intestinal pediatric recipient. Light immunosuppression was attempted early in the postoperative course of this child because of pneumocystis carinii pneumonia and an intestinal anastomotic leak. The skin lesions appeared 10 days after transplantation, and the overall clinical picture simulated life-threatening sepsis. The immunosuppression was reduced significantly, and 13 days later the patient succumbed to multiple organ failure. Therefore, despite of the "historical" fear⁶⁵ of high incidence of

GVHD documented in experimental intestinal transplantation,^{54,69,72} our clinical experience has actually shown a minimal occurrence of severe GVHD.

Actually, one of the most intriguing findings from the immunological patient surveillance was the gradual replacement of the donor hemolymphoid cells, in the intestinal wall and mesenteric lymph nodes of the graft, by immunocompetent hemolymphoid cells of the recipient, which rearrange the normal intestinal mucosal immune system architecture.⁷² Conversely, donor migratory immunocytes ("passenger leukocytes") originating from the graft migrate at the same time ubiquitously into the recipient blood stream and tissues. This new immunological status ("systemic chimerism") could be the basis of gradual induction of donor specific non-reactivity (tolerance).^{59,74-76}

CLINICAL XENOTRANSPLANTATION

The significant advances achieved in the field of liver transplantation have led to an increased demand for organs, and created a wide gap between organ availability and supply.^{63,77} As of March 31, 1994, there were 34,493 patients in the United Network for Organ Sharing (UNOS) waiting list,⁷⁸ up from 13,115 in December 21, 1987, an increase of 263%. Of these, 3,264 awaited liver transplantation, up from 449 in 1987 (727% increase). The supply of organ donors, on the other hand, underwent a marginal increase between 1988 and 1990 (from 4,085 to 4,514), and has remained relatively stable (4,531 in 1991, 4,521 in 1992, and 4,849 in 1993) thereafter. A wider availability of organs for transplantation would allow an expansion⁷⁹ rather than a contraction of the indications for transplantation, and at the same time a relaxation of the patient selection criteria.^{80,81} All these facts clearly justify the renewed interest in xenotransplantation observed in the last decade.⁸²

The first three attempts at whole organ xenotransplantation were made in France and Germany between January and April 1906, using a pig, a goat, and a macaque as kidney donors.^{83,84} None of these kidneys functioned because of almost immediate vascular thrombosis, and the human recipients died in less than 3 days. In a further attempt in 1923 by Neuhof⁸⁵ a lamb was used as a kidney donor, and the patient died 9 days after. On February 16, 1963, Hitchcock of

(Children = 16)		
Etiology of Intestinal Failure	Intestine + Liver	Multivisceral
Gastroschisis	5	0
Necro. enterocolitis	4	0
Volvulus	3	0
Intestinal atresia	2	0
Microvillus disease	1	0
Pseudo-obstruction	0	1
Adults (n = 11)		
Etiology of Intestinal Failure	Intestine + Liver	Multivisceral
Crohn's disease	1	0
Abdominal trauma	2	0
Celiac A. occlusion	0	3*
S.M.A. thrombosis	2	0
Desmoid tumor	1	0
Metastatic gastrinoma	0	1
Budd-Chiari syndrome	0	1

*These patients had short-gut syndrome due to concomitant superior mesenteric artery (S.M.A.) thrombosis by Protein S deficiency (n=1), Antithrombin III deficiency (n=1) or unknown cause (n=1).

Table 4: Etiology of intestinal failure, and indications for combined liver-intestine and multivisceral transplantations in a group of 21 patients operated at the Pittsburgh Transplantation Institute.

the Hennepin County Hospital, in Minneapolis, transplanted the kidney of a baboon to a 65-year-old woman. The organ functioned for 4 days before its artery clotted.⁸⁶ A few months later on October 8, 1963, Reemtsma of Tulane University used a Rhesus monkey as kidney donor for a human recipient who survived 12 days. Then, Reemtsma tried again with a series of 6 consecutive chimpanzee kidney grafts.⁸⁷ One of these xenografts functioned for 270 days.

In December, 1963 and January, 1964, 6 patients received baboon kidneys at the University of Colorado, in Denver.⁸⁸ All of these kidneys worked immediately and sustained a dialysis-free life for 10 to 60 days. The patients were treated with high doses of azathioprine and prednisone, and 4 of them died of sepsis, while rejection was mainly responsible for the other two deaths. However, the pathology of the rejection was not qualitatively different from that observed in allografts.⁸⁹ Similar immunopathological events brought to failure, after 20 days, a baboon heart transplanted in 1984 into a 2.2 kg neonate,⁹⁰ in spite of heavy cyclosporine-steroid immunosuppression. A pig kidney and heart transplanted by Kuss⁹¹ and Ross,⁹² respectively, in the 1960s were hyperacutely rejected in a matter of minutes, demonstrating that the pig was not, and will not be, an easy donor for a human recipient.

The Antiproliferative Drugs — Sir Peter Medawar, in 1969, stated that: "A new solution is therefore called for: the use of heterografts - that is to say, of grafts transplanted from lower animals into man. Of the use of heterografts I can say only this: that in the laboratory we are achieving greater success with grafts *between* species today than we achieved with grafts *within* 15 years ago. We shall solve the problem by using heterografts one day if we try hard enough, and maybe in less than 15 years."⁹³ However, the laboratory work performed at different institutions in the following 15-20 years did not bring results that could encourage further clinical trials. In May, 1992 a study performed in Pittsburgh by Murase et al.,⁹⁴ using a hamster-to-rat xenotransplant model, was discussed at the meeting of the American Society of Transplant Surgeons, in Chicago. Murase's work clearly showed that indefinite survival under FK506 was routinely achievable if it was combined, for the

first two post-transplant weeks, with either of two "antiproliferative" drugs that suppress purine (RS 61443) or pyrimidine (brequinar) ribonucleotide synthesis. The use of cyclophosphamide, an alkylating agent with considerable B cell specificity,^{38,95} allowed similar consistent chronic survival after either heart or liver xenotransplantation. Particularly significant was the fact that a single large dose of cyclophosphamide, given 10 days before the xenotransplant, allowed success in almost 100% of the animals with only daily administration of FK506. This work, together with the previous experience with cyclophosphamide^{96,97} as an effective drug in clinical transplantation, justified its use in clinical xenograft trials.

The Liver Clinical Xenotransplant Trial — On June 28, 1992, and on January 10, 1993, two patients, age 35 and 62 years, respectively, underwent liver xenotransplantation. Both had end-stage chronic active hepatitis caused by hepatitis B virus (HBV), and were in stage 3 coma during the 24 hours that preceded the surgery. The evidence that the baboon liver is resistant to the HBV,^{98,99} which reinfects most allografts under comparable circumstances,¹⁰⁰ prompted the selection of these two candidates, to whom human liver transplantation had already been refused at other institutions. The second patient was far more

frail, and underwent splenectomy on the fourth day post-transplant, while the first had had a splenectomy (for trauma) in 1989. Both patients were immunocompetent at the time of the xenograft, although the first also had an HIV infection.^{98,99,101-103} These differences may have impacted on the efficacy of the perioperative immune modulation.

The chosen donor animal was the baboon *Papio cynocephalus*. The technical details of the donor surveillance and selection, as well as of the donor and recipient operations, have been published elsewhere^{98,99,101-103} and will not be repeated here. The baboon liver reperused promptly and uniformly in both cases (Figure 6). The post-reperfusion biopsies showed a good liver architecture, with a moderate degree of sinusoidal neutrophilic aggregates. The immunosuppression was based on the use of 4 drugs: cyclophosphamide, FK506, methylprednisolone and PGE₁. Doses and routes of administration are shown in Figures 7 and 8. Cyclophosphamide was started 2 days before the xenotransplants, and was given for 56 days (out of 70) in Case 1, and for 10 days (out of 26) in Case 2, with the dose ranging from 0.07 to 10.6 mg/kg/day. FK506 was started on the day of the xenografts and, except for higher doses given during the first 2 postoperative weeks in Case 1, the doses were within standard therapeutic ranges. Detailed



Figure 6: The *Papio cynocephalus* liver at the time of reperfusion in the baboon-to-human liver xenotransplantation (first patient: June 28, 1992). The organ is uniformly and nicely reperused. (From: Marino IR, Tzakis AG, Fung JJ, Todo S, Doyle HR, Manez R, Starz TE. Liver xenotransplantation. In: *Surgical Technology International II*, Braverman MH and Tawes RL (eds.), 139-144, Thomas F. Laszlo Publisher, San Francisco, California, 1993. Used by permission).

descriptions of the immunosuppressive drug doses and their blood levels have been recently reported elsewhere.^{98,99,101-103} The first patient awoke promptly, was extubated after 17 hours, and was eating and walking 5 days after surgery. He had an almost normal bilirubin for the majority of the 70 days that he survived (Figure 7). He also spent more than 30 days in a regular ward. The second patient, however, remained icteric (Figure 8) and comatose, and required mechanical ventilation during his whole postoperative course. Both patients suffered from hypoalbuminemia, and received frequent albumin infusions.^{98,99,101-103} The first patient went into renal failure on postoperative day 21, while the second patient became anuric immediately after surgery.

Papio cynocephalus normally produces elevated levels of factor VII and low levels of factors IX and XI, as compared to humans. Coagulation profiles were done in both recipients preoperatively and several times postoperatively. Our results, reported elsewhere,¹⁰⁴ showed that the baboon's coagulation pattern was acquired by the patient after liver xenografting, but this did not affect the clotting ability of the patients.

During their postoperative course, the patients underwent several liver biopsies (6 in patient 1 and 8 in patient 2, including the autopsy specimens). Only the biopsy obtained from the first patient on the 12th postoperative day had signs of mild focal cellular rejection, while no evidence of cellular rejection was detected in any of the other biopsies

from either patient.^{98,99,101-103,105} No evidence of HBV reinfection was detectable by immunoperoxidase staining in the liver tissue at any time.

Both baboon livers underwent a dramatic growth after implantation into the larger human recipient, with tripling or quadrupling of the organ volume within the first month.¹⁰² The cause of death in the first case was diffuse subarachnoid hemorrhage and left uncus brain stem herniation, secondary to angioinvasive aspergillosis; the second patient died of peritonitis. Details of the necropsies have been reported elsewhere.^{98,99,101-103} However, cell chimerism was proven in both patients by the presence of baboon DNA in all tissues examined (using PCR amplification of baboon-specific DNA).^{98,99} It should also be noted that, in addition to the liver, the second patient was given a large dose of baboon bone marrow cells (3x10⁸/Kg body weight), after the reperfusion of the baboon liver.

Analysis of the Two Cases and Strategies for Future Clinical Xenotransplantation.

— The most disquieting fact in our baboon-to-human liver transplant experience was the disparity between the paucity of the histopathologic findings of rejection (which was very encouraging) and the discouraging functional deficiencies of these xenotransplants, which suggested incomplete control of xenograft rejection. The pathology of the transplanted baboon livers was compared to that of 6 baboon kidney xenografts transplanted in Denver in 1963.^{88,89} These kidneys, as we mentioned before, functioned for 6 to 60 days. The key pathological finding was an occlusive endothelialitis of the graft vessels, presumably antibody-mediated. The pathology of those kidneys removed in 1964⁸⁹ showed distal ischemia, caused by the vascular injury, that appeared to be responsible for the patchy gangrene of the xenografts. In the two recent liver xenotransplants, polymorphonuclear leukocytes were seen in the sinusoids immediately after reperfusion, and biliary sludging was detected at the autopsy. Both the sludging and the appearance of polymorphonuclear leukocytes were compatible with a diagnosis of an aborted hyperacute (humoral) rejection. Complement studies were also consistent with this possibility. Total complement was depleted for most of the critical first 2 weeks, while complement components C3, 4 and 5 became undetectable.

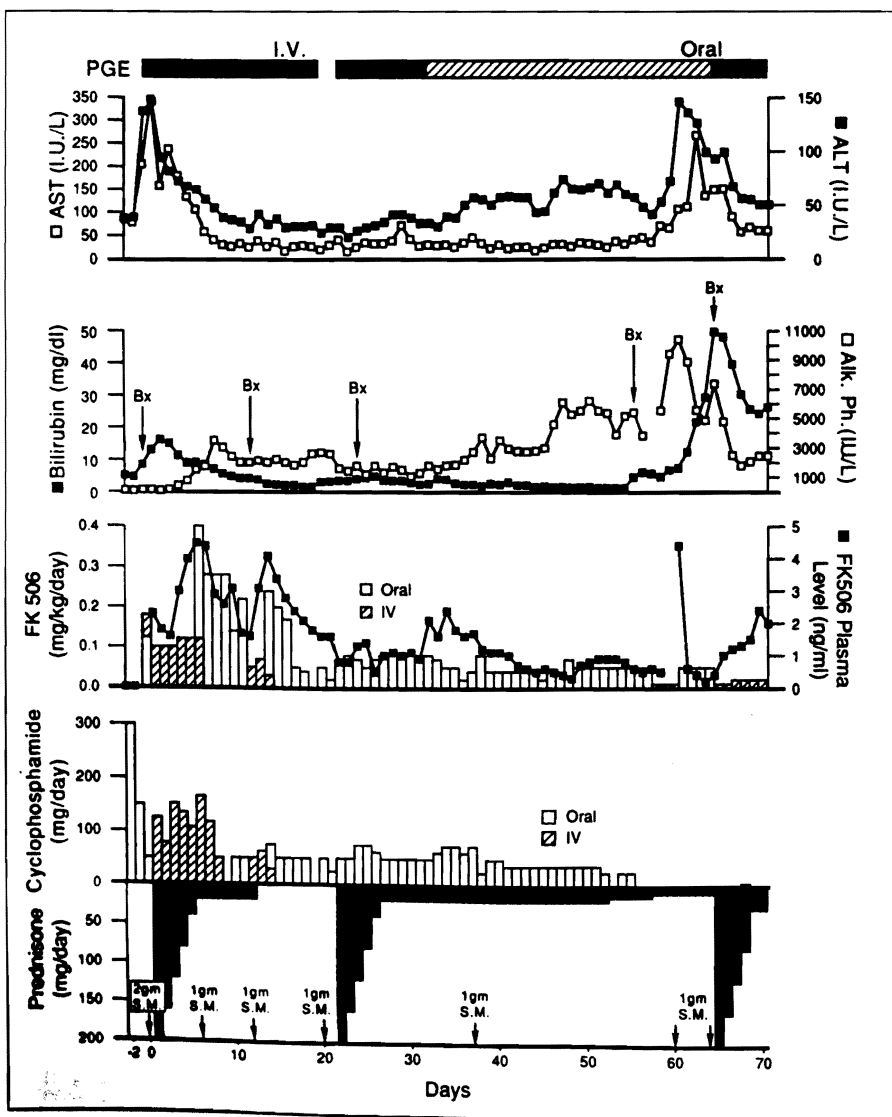


Figure 7: Clinical course of the first liver xenograft (baboon-to-human) recipient (June 28, 1992). SM Schumadrol (methylprednisolone); PGE, prostaglandin E; Bx, biopsy; AST, aspartate aminotransferase; ALT, alanine aminotransferase; AlkPh, alkaline phosphatase. (From: Starzl TE, Fung J, Tzakis A, Todo S, Demetris AJ, Marino IR, Doyle H, Zeevi A, Warty V, Michaels M, Kusne S, Rudert WA, Trucco M. Baboon to human liver transplantation, *Lancet* 1993; 341:65-71. Used by permission).

During this time, circulating immune complexes appeared.^{99,101} After 10 days the complement system was restored, but irreversible damage may have been already done. Although these baboon liver xenografts looked almost normal, closer inspection showed a very fine microsteatosis, which was particularly obvious in the second patient. This may represent a sub-lethal immunological injury that precluded long term success in both cases.

We believe now that these livers were acutely damaged by an incomplete version of a form of rejection that was described, in 1964, in ABO incompatible kidneys,^{106,107} and seen later in kidney allografts transplanted across a positive lymphocytotoxic crossmatch.¹⁰⁸ These were the first descriptions of hyperacute kidney rejection by preformed anti-graft antibodies. A few years later, hyperacute kidney rejection was defined in a more sophisticated way as a complement activation syndrome, analogous to the Shwartzman and local Arthus reactions.^{109,110} It was pointed out that, although hyperacute allograft rejection usually was associated with anti-graft antibodies, this was not an absolute requirement, a heretical statement at that time. However, the distinction between hyperacute rejection with and without preformed antibodies is merely the difference between the classical pathway of complement activation, in which the first steps are antibody dependent, and the alternative pathway, which does not require an antibody trigger or the participation of complement components C1, C2, and C4. We believe that these hyperacute rejection syndromes, with or without preformed anti-graft antibodies, are not fundamentally different from those seen after xenotransplantation of organs between genetically diverse species.

Many methods of manipulating the xenograft recipient have been tried and re-tried since the 1960s, without any definite success. These methods include antibody suppression,¹¹¹ antibody depletion,¹¹²⁻¹²³ inhibition of the complement cascade,¹²⁴⁻¹²⁹ and inhibition of the inflammatory response.¹³⁰⁻¹³¹ Alteration of the xenograft before its implantation, mainly by blocking antibody binding sites with recipient F(ab')₂ immunoglobulin fragments,^{120,132,133} has also been unsuccessful. The introduction of the concept of systemic chimerism, has heightened interest in designing strategies aimed to alter the cell composition of the graft.

The creation of a transgenic pig, to be utilized as a source of organs for clinical xenotransplants, has been already started in a few laboratories.^{134,135} The scientists working on this project have embarked on a program to produce pigs transgenic for human regulators of complement activation (e.g. DAF, CD59, and MCP). This is achieved by micro-injection of human genomic DNA fragments into the pronuclei of fertilized porcine oocytes.¹³⁶ However, only one of the components of the xenotransplant barrier could be overcome by this strategy (namely, the complement cascade); therefore it is difficult to hope that a complete control of rejection will be achieved by this method alone.

One other extremely fascinating possibility is the production of chimeric

organs. Human-to-baboon bone marrow transplantation has already been performed in our laboratories, after conditioning with non-lethal irradiation.¹³⁷ In this experiment, two baboons preconditioned with 7.5 Gy total lymphoid irradiation were given 6×10^8 /Kg body weight unaltered human bone marrow cells, without any subsequent treatment. Donor DNA was found widely distributed in the tissues of both animal when they were sacrificed, 18 months later. It is also interesting to note that GVHD did not occur in either animal. As recently stated elsewhere¹⁰⁵: "it remains to be seen if incomplete or even full chimerism will change the image of baboon organs enough to make them viewed as allografts by humans". In conclusion, the impression we want to leave is that with

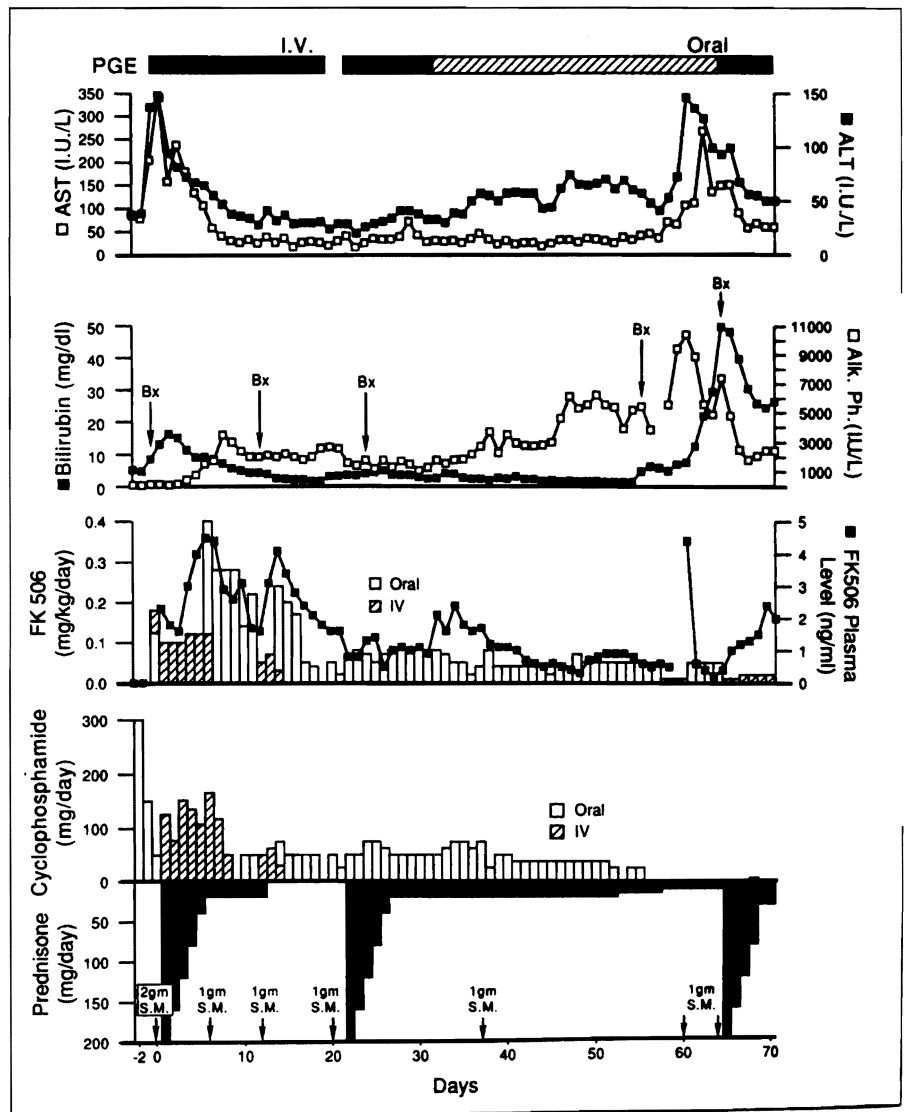


Figure 8: Clinical course of the second liver xenograft (baboon-to-human) recipient (January 10, 1993). SM, Solumedrol (methylprednisolone); PGE, prostaglandin E; Bx biopsy; AST, aspartate aminotransferase; ALT, alanine aminotransferase; WBC, white blood cells, (from: Starzl TE, Tzakis A, Fung J, Todo S, Marino IR, Demetris AJ: Human liver xenotransplantation. *Xeno* 1993; 1(1):4-7. Used by permission)

a combination of modern immunosuppressive agents and donor cell manipulation the prospect of successfully performing clinical xenografts seems today closer than ever.

INDUCTION OF GRAFT ACCEPTANCE

The mechanisms through which allografts are able to weather the initial recipient immune system attack, and later allow for two cell populations (donor and recipient) to coexist with less and less need for immunosuppression, was not well understood until recently. It has been postulated by us^{74,75,138,139} that the migration of donor leukocytes from transplanted organs, facilitated by immunosuppressive drugs, and the ubiquitous persistence of these cells in the recipient tissues, are the seminal explanation for the occurrence of microchimerism. Also, this cell migration is the first stage in the development of donor specific nonreactivity, and the necessary pathway to allograft acceptance.

Observations compatible with this concept were already reported more than 30 years ago, when azathioprine and prednisone were introduced as combined immunosuppression for kidney transplantation.¹⁴⁰ In fact, there is a characteristic cycle of kidney allograft rejection, in the first few days or weeks post transplant, that can be reversed

with steroids. The ability to reduce and sometimes even to stop the immunosuppression was thereafter confirmed in cases of transplantation of the liver, heart and other solid organs. More recently, study of transplanted abdominal organs and their host have provided unique insights into these processes.^{74,75,138,139,141,142} In 1969 it was noted that the Kupffer cells and other tissue leukocytes became predominantly of recipient phenotype within 100 days of transplantation, while the hepatocytes permanently retained their donor specificity. This transformation was long assumed to be unique to the hepatic allograft.¹⁴³

However, 22 years later, first in rat models, and then in humans, it was realized that the same process occurred in all successfully transplanted intestines (see previous section), and other organs, differing quantitatively (and perhaps qualitatively) in the number of substituted tissue leukocytes, being greatest with the liver. In 1992,¹⁴⁴ the fate of the leukocytes vacating the grafts was determined by studying the longest survivors after kidney (30 years) or liver transplantation (23 years). Biopsies were obtained from these patients, and from more recently transplanted patients that received hearts, lung, or intestines. Samples were taken from the transplanted organ, as well as from the patient's own skin, lymph

nodes, and other tissues. After special staining procedures (immunostaining or sex identification after fluorescence in situ hybridization [FISH]), it was possible to determine if the individual cells had come from the donor organ, the recipient's own body, or both. In confirmatory investigations, the donor and recipient contributions to any specimen could be separated by polymerase chain reaction ("DNA fingerprinting") techniques.

From these analyses, supporting laboratory experiments in animals, and the most recent experience with baboon-to-human transplants, it became clear that within minutes after restoring the blood supply of any transplant, myriads of sessile, but potentially migratory leukocytes that are part of the normal structure of all organs (passenger leukocytes) left the allograft or the xenograft and migrated ubiquitously; at the same time they were being replaced in the transplanted organ by similar recipient immunocytes, under the protection of immunosuppressive drugs (ure 9). In this new context, the drugs could be viewed as traffic directors, allowing movement of leukocytes to and from the allograft or the xenograft, but preventing the immune destruction that is the normal purpose of this traffic. Because of this bidirectional cell traffic, an immunological status can be reached in which immunosuppression can be stopped, particularly after liver transplantation.¹⁴⁵ Such a stable immunological condition can be achieved more easily with the liver than with any other graft, because of the high concentration in the liver of those critical leukocytes that apparently include pluri-potent stem cells.

PATIENTS AND METHODS

In a direct extension of this described leukocyte chimerism that occurs spontaneously with whole organ allo- and xenotransplantation, we augmented the host leukocyte load by perioperative infusion of unmodified donor bone marrow to 36 organ recipients who were treated with a conventional regimen of FK506 and prednisone immunosuppression. We report herein only on the first 18 patients, treated between December 1992 and December 1993, and for whom a follow-up of 4 to 16 months is available. Ten patients received a kidney trans-

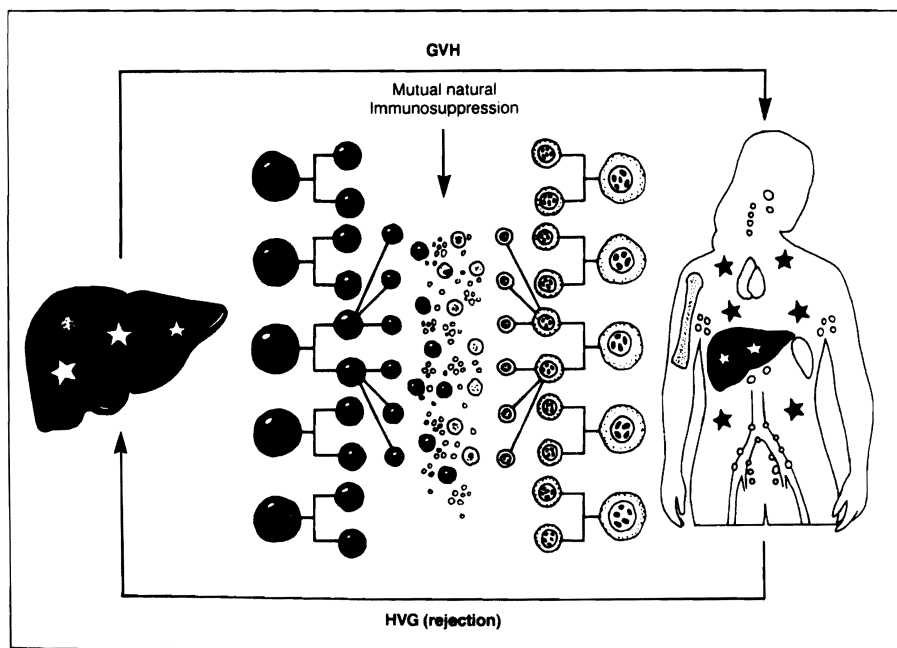


Figure 9: The mutual engagement of migrating immunocytes from the graft and the recipient following organ transplantation under potent pharmacological immunosuppression. GVH: graft versus host; HVG: host versus graft. (From: Starzl TE, Demetris AJ, Murase N, Thomson AW, Trucco M, Ricordi C: Donor cell chimerism permitted by immunosuppressive drugs: a new view of organ transplantation. *Immunology Today* 14(6):326-332, 1993. Used by permission).

plant, 7 received a liver, and 1 received a heart, including 3 diabetics with no detectable serum C-peptide who also received pancreatic islets intraportally. Their mean age was 46 ± 13.2 years, (range 20 to 63). The cadaveric donors were ABO identical with their recipients, and all patients received 3×10^8 donor bone marrow cells/Kg of recipient body weight, at the time of the solid organ graft.

RESULTS

All patients are presently well, and have excellent function of their transplanted organs. Persistent multilineage leukocyte chimerism was found in the blood of 17 of these 18 recipients, using either flow cytometry and qualitative or quantitative PCR techniques for detection of donor HLA alleles or, additionally, Y chromosomes in female recipients of male organs. In the only patient in whom chimerism could not be demonstrated, the use of a 5-antigen HLA matched, same-sex donor precluded the use of these markers. Rejection was diagnosed and successfully treated in 9 (50%) of the 18 recipients, and transient GVHD occurred in 2 (11%). Donor specific hyporeactivity at variable times postoperatively was demonstrable with in vitro tests in the majority of the recipients, and could be identified as early as 50 days post-transplant. It is now too early to attempt discontinuation of the immunosuppressive therapy, however, the pronounced trend to donor-specific nonreactivity (tolerance) revealed by the in vitro tests is very encouraging.

CONCLUSIONS

During the last 15 years, survival after orthotopic liver transplantation has dramatically improved. This has been due to advanced medical technology, and important technical refinements,^{7,9} better organ preservation,¹⁴⁶ and new potent immunosuppressive drugs.^{5,147} The recent introduction of FK506 has further improved the survival and the quality of life of liver transplant recipients, compared with our previous experience.¹⁴⁷ Summary of the worldwide experience with FK506 was presented during the 1991 First International Congress on FK506, and has been published elsewhere.¹⁴⁸ FK506 completed on April 8, 1994, its "fast track" journey through the Food and

Drug Administration, and it is now commercially available in the U.S.

The recent achievement of satisfactory long term survival of patients treated with combined liver-intestinal and multivisceral transplantation justifies a continuation of the clinical trials. However, the surveillance and intensity of care required by these patients for the first year, and in most instances thereafter, was very high, far more than at comparable times after the transplantation of the liver alone. Further immunologic and surgical strategies will be required to increase the practicality and success of such creative surgery.⁶⁵

Although our recent attempts at baboon-to-human xenotransplantation failed, there were encouraging notations. First, the xenografts had no evidence of B virus infection during their post-transplant survival of 70 and 26 days in B virus carriers. Second, there also was little histopathologic evidence of humoral or cellular rejection of both liver xenografts. Nonetheless, the function of both xenografts was unsatisfactory. This could be explained by a damage caused by a complement activation syndrome precipitated by classical pathway or independent of antibodies (alternative pathway). Third, the discovery that chimerism easily occurs after baboon-to-human transplants, and after human-to-baboon bone marrow transplant, can possibly open new avenues for the feasibility of clinical xenotransplantation.

The discovery that immunosuppressive drugs can lead to tolerance induction, by allowing a previously unrecognized common mechanism of cell migration and microchimerism to occur, has important therapeutic and clinical implications.

Because the chimeric leukocytes dispersed from the allograft are of bone marrow origin, a therapeutic corollary was that acceptance of less favored organs such as the heart and kidney (or even the liver itself) could be facilitated by the infusion of unaltered donor bone marrow perioperatively. Donor leukocyte infusion to induce tolerance was the best therapeutic strategy of transplantation immunology, but perhaps the least well understood. It was first used by Main and Prehn¹⁴⁹ who showed that lethally irradiated adult mice reconstituted with allogeneic bone marrow could accept skin from the same donor strain but no other. These were efforts

to mimic the two conditions (inoculation of mature donor immunocytes and immunologic non-reactivity of recipients) that had allowed Billingham, Brent and Medawar¹⁵⁰ to induce acquired tolerance of neonatally or perinatally injected mice. Thousands of similar experiments, as well as the treatment policies in the clinical field of bone marrow transplantation, have assumed the need for either a natural or imposed state of host non-reactivity. The resultant risk of GVHD from liver donor cells, described by Billingham and Brent,¹⁵¹ has been so great in the presence of MHC incompatibility that their use has been largely avoided.

Armed with the discoveries that natural chimerism from the graft itself begins within minutes of organ revascularization, and is persistent, it was possible during 1993 to simulate this timing in unconditioned patients whose transplanted organ, routine immunosuppression, and adjuvant bone marrow all arrived perioperatively. The ambitious goal of these projects is to induce a condition of donor-specific tolerance, both in allo- and xenotransplantation, preserving all the functions of the host immune system. These achievements, along with the demonstration that xenotransplantation and intestinal transplantation are a clinical possibility and not any longer futuristic projects, will be chronicled as some of the most significant advances in medicine. When all these become a reality the work started by Sir Peter Medawar will be completed. **STI**

REFERENCES

1. Starzl TE, Marchioro TL, Von Kaulla KN, Hermann G, Brittain RS, Waddell WR: Homotransplantation of the liver in humans. *Surg Gynecol Obstet* 117:659-676, 1963.
2. Calne RY, Williams R: Liver transplantation in man: I. Observations on technique and organization in five cases. *Br Med J* 4:535-540, 1968.
3. Starzl TE (with the assistance C.W. Putnam): Experience in Hepatic Transplantation WB Saunders Company, Philadelphia, 1969.
4. Starzl TE, Ishikawa M, Putnam CW, Porter KA, Picache R, Husberg BS, Halgrimson CG, Schroter G: Progress in and deterrents to orthotopic liver transplantation, with special reference to survival, resistance to hyperacute rejection, and biliary duct reconstruction. *Transplantation Proc* 6:129-139, 1974.
5. Calne RY, Rolles K, White DJG, Thiru S, Evans DB, McMaster P, Dunn DC, Craddock GN, Henderson RG, Aziz S, Lewis P: Cyclosporin A initially as the only immuno-

- suppressant in 34 recipients of cadaveric organs: 32 kidneys, 2 pancreases, and 2 livers. *Lancet* 2(8151):1033-1036, 1979.
6. Starzl TE, Iwatsuki S, Van Thiel DH, Gartner JC, Zitelli BJ, Malatack JJ, Schade RR, Shaw BW Jr, Hakala TR, Rosenthal JT, Porter KA: Evolution of liver transplantation. *Hepatology* 2:614-636, 1982.
7. Starzl TE and Demetris AJ: Liver transplantation: A 31 year perspective. *Current Problems in Surgery Part I* 27:49-116, 1990; *Part II* 27:117-178, 1990; *Part III* 27:181-240, 1990.
8. Calne RY: Liver transplantation: the Cambridge-King's College Hospital experience, Second Edition, Grune & Stratton, Inc, Orlando, Florida, 1987.
9. Starzl TE, Iwatsuki S, Esquivel CO, Todo S, Kam I, Lynch S, Gordon RD, Shaw BW Jr: Refinements in the surgical technique of liver transplantation. *Seminars in Liver Disease* 5:349-356, 1985.
10. Ochiai T, Nakajima K, Nagata M, Suzuki T, Asano T, Eumatsu T, Goto T, Hori S, Kenmochi T, Nakagori T, Isono K: New immunosuppressive drugs. Effect of a new immunosuppressive agent, FK506, on heterotopic cardiac allotransplantation in the rat. *Transplant Proc* 19:1284-1286, 1987.
11. Ochiai T, Nakajima K, Nagata M, Hori S, Asano T, Isono K: Studies of the induction and maintenance of long-term graft acceptance by treatment with FK506 in heterotopic cardiac allotransplantation in rats. *Transplantation* 44(6):734-738, 1987.
12. Ochiai T, Nagata M, Nakajima K, Suzuki T, Sakamoto K, Enomoto K, Gunji Y, Uematsu T, Goto T, Hori S, Kenmochi T, Nakagori T, Asano T, Isono K, Hamaguchi K, Tsuchida H, Nakahara K, Inamura N, Goto T: Studies of the effects of FK506 on renal allograft in the beagle dog. *Transplantation* 44:729-733, 1987.
13. Ochiai T, Hamaguchi K, Isono K: Histopathologic studies in renal transplant recipient dogs receiving treatment with FK506. *Transplant Proc* 19(Suppl.6):93-97, 1987.
14. Ochiai T, Sakamoto K, Gunji Y, Hamaguchi K, Isegawa N, Suzuki T, Shimada H, Hayashi H, Yasumoto A, Asano T, Isono K: Effects of combination treatment with FK506 and cyclosporine on survival time and vascular changes in renal allograft recipient dogs. *Transplantation* 48(2):193-197, 1989.
15. Ochiai T, Gunji Y, Sakamoto K, Suzuki T, Isegawa N, Asano T, Isono K: Optimal serum trough levels of FK506 in renal allotransplantation of the beagle dog. *Transplantation* 48(2):189-193, 1989.
16. Murase N, Todo S, Lee P-H, Lai H, Chapman F, Nalesnik MA, Makowka L, Starzl TE: Heterotopic heart transplantation in the rat under FK-506 alone or with cyclosporine. *Transplantation Proc* 19(Suppl.6):71-75, 1987.
17. Todo S, Demetris AJ, Ueda Y, Imventarza O, Okuda K, Casavilla A, Cemaj S, Ghalab A, Mazzaferro V, Rhoe BS, Tonghua Y, Makowka L, Starzl TE: Canine kidney transplantation with FK-506 alone or in combination with cyclosporine and steroids. *Transplantation Proc* 19(Suppl.6):57-61, 1987.
18. Todo S, Ueda Y, Demetris JA, Imventarza O, Nalesnik M, Venkataramanan R, Makowka L, Starzl TE: Immunosuppression of canine, monkey, and baboon allografts by FK 506 with special reference to synergism with other drugs, and to tolerance induction. *Surgery* 104:239-249, 1988.
19. Todo S, Demetris A, Ueda Y, Imventarza O, Cadoff E, Zeevi A, Starzl TE: Renal transplantation in baboons under FK 506. *Surgery* 106:444-451, 1989.
20. Zeevi A, Duquesnoy R, Eiras G, Rabinowich H, Todo S, Makowka L, Starzl TE: Immunosuppressive effect of FK 506 on in vitro lymphocyte alloactivation: Synergism with cyclosporine A. *Transplantation Proc* 19(Suppl.6):40-44, 1987.
21. Warty V, Diven V, Cadoff E, Todo S, Starzl TE, Sanghvi A: FK 506: A Novel immunosuppressive agent characteristics of binding and uptake by human lymphocytes. *Transplantation* 46:453-455, 1988.
22. Lim SML, Thiru S, White DJG: Heterotopic heart transplantation in the rat receiving FK506. *Transplant Proc* 19:68-70, 1987.
23. Collier DS, Thiru S, Calne R: Kidney transplantation in the dog receiving FK506. *Transplant Proc* 19(Suppl.6):62, 1987.
24. Thiru S, Collier DS, Calne R: Pathological studies in canine and baboon renal allograft recipients immunosuppressed with FK506. *Transplant Proc* 19(Suppl.6):98-99, 1987.
25. Starzl TE, Todo S, Fung J, Demetris AJ, Venkataramanan R, Jain A: FK 506 for human liver, kidney and pancreas transplantation. *Lancet* 2:1000-1004, 1989.
26. Todo S, Fung JJ, Starzl TE, Tzakis A, Demetris AJ, Kormos R, Jain A, Alessiani M, Takaya S: Liver, kidney, and thoracic organ transplantation under FK 506. *Ann Surg* 212:295-305, 1990.
27. Starzl TE, Fung J, Jordan M, Shapiro R, Tzakis A, McCauley J, Johnston J, Iwaki Y, Jain A, Alessiani M, Todo S: Kidney transplantation under FK 506. *JAMA* 264:63-67, 1990.
28. Venkataramanan R, Jain A, Cadoff E, Warty V, Krajack A, Imventarza O, Todo S, Fung JJ, Starzl TE: Pharmacokinetics of FK 506: Preclinical and clinical studies. *Transplantation Proc* 22:52-56, 1990.
29. Venkataramanan R, Jain A, Warty VW, Abu-Elmagd K, Furakawa H, Imventarza O, Fung J, Todo S, Starzl TE: Pharmacokinetics of FK 506 following oral administration: A comparison of FK 506 and cyclosporine. *Transplantation Proc* 23:931-933, 1991.
30. Starzl TE, Abu-Elmagd K, Tzakis A, Fung JJ, Porter KA, Todo S: Selected topics on FK 506: With special references to rescue of extrahepatic whole organ grafts, transplantation of "forbidden organs", side effects, mechanisms, and practical pharmacokinetics. *Transplantation Proc* 23:914-919, 1991.
31. Tamura K, Kobayashi M, Hashimoto K, Kojima K, Nagase K, Iwasaki K, Kaizu T, Tanaka H, Niwa M: A highly sensitive method to assay FK506 levels in plasma. *Transplant Proc* 19(5 Suppl 6):23-29, 1987.
32. Cadoff E, Venkataramanan R, Krajack A, Jain A, Fung JJ, Todo S, Starzl TE: Assay of FK 506 in plasma. *Transplantation Proc* 22:50-51, 1990.
33. Fung J, Abu-Elmagd K, Jain A, Gordon R, Tzakis A, Todo S, Takaya S, Alessiani M, Demetris A, Bronsther O, Martin M, Miele L, Selby R, Reyes J, Doyle H, Stieber A, Casavilla A, Starzl TE: A randomized trial of primary liver transplantation under immunosuppression with FK 506 versus cyclosporine. *Transplantation Proc* 23:2977-2983, 1991.
34. Abu-Elmagd K, Fung JJ, Alessiani M, Jain A, Venkataramanan R, Warty VS, Takaya S, Todo S, Shannon WD, Starzl TE: The effect of graft function on FK 506 plasma levels, doses, and renal function: with particular reference to the liver. *Transplantation* 52:71-77, 1991.
35. Abu-Elmagd KM, Fung J, Draviam R, Shannon W, Jain A, Alessiani M, Takaya S, Venkataramanan R, Warty VS, Tzakis A, Todo S, Starzl TE: Four-hour versus 24-hour intravenous infusion of FK 506 in liver transplantation. *Transplantation Proc* 23:2767-2770, 1991.
36. Jain A, Fung JJ, Venkataramanan R, Todo S, Alessiani M, Starzl TE: FK 506 dosage in human organ transplantation. *Transplantation Proc* 22:23-24, 1990.
37. Takaya S, Iwaki Y, Starzl TE: Liver Transplantation in positive cytotoxic cross-match cases using FK 506, high dose steroids and prostaglandin E1. *Transplantation* 54:927-930, 1992.
38. Marino IR, Doyle HR: Conventional immunosuppressive drugs. In: *Immunosuppressive drugs: Advances In Anti-rejection Therapy*, Thomson AW, Starzl TE, (eds), Chapter 1, 1-14, Edward Arnold Publishers, London, 1994.
39. Detre K, Belle S, Beringer K, Daily OP: Liver transplantation for fulminant hepatic failure in the United States, October 1987 through December 1991. *Clinical Transplantation* 8:274-280, 1994.
40. Esquivel CO, Iwatsuki S, Marino IR, Markus B, Van Thiel D, Starzl TE: Liver transplantation for hepatocellular carcinoma and other primary hepatic malignancies. In: *Trends in Gastroenterology* (K Sugahara, ed) Japan, 1987, pp. 323-332.
41. Van Thiel DH, Carr B, Iwatsuki S, Selby R, Fung JJ, Starzl TE: The 11-year Pittsburgh experience with liver transplantation for hepatocellular carcinoma: 1981-1991. *J Surg Oncol Suppl* 3:78-82, 1993.
42. Jain AB, Fung JJ, Todo S, Alessiani M, Takaya S, Abu-Elmagd K, Tzakis A, Starzl TE: Incidence and treatment of rejection episodes in primary orthotopic liver transplantation under FK506. *Transplantation Proc* 23:928-930, 1991.
43. Shapiro R, Fung JJ, Jain A, Parks P, Todo S, Starzl TE: The side effects of FK 506 in humans. *Transplantation Proc* 22:35-36, 1990.
44. Alessiani M, Kusne S, Martin M, Fung JJ, Jain A, Todo S, Simmons R, Starzl TE: Infections under FK 506 immunosuppression: Preliminary results with primary therapy. *Transplantation Proc* 22:44-46, 1990.

45. Alessiani M, Cillo V, Fung JJ, Irish W, Abu-Elmagd K, Jain A, Takaya S, Van Thiel D, Starzl TE: Adverse effects of FK506 overdose after liver transplantation. *Transplantation Proc* 25:628-634, 1993.
46. Eidelman BH, Abu-Elmagd K, Wilson J, Fung JJ, Alessiani M, Jain A, Takaya S, Todo S, Tzakis A, Van Thiel D, Shannon W, Starzl TE: Neurological complications of FK 506. *Transplantation Proc* 23:3175-3178, 1991.
47. Alessiani M, Kusne S, Martin M, Jain A, Abu-Elmagd K, Moser J, Fung J, Starzl T: Infection in adult liver transplant patients under FK506 immunosuppression. *Transplantation Proc* 23:1501-1503, 1991.
48. Green M, Tzakis A, Reyes J, Nour B, Todo S, Starzl TE: Infectious complications of pediatric liver transplantation under FK 506. *Transplantation Proc* 23:3038-3039, 1991.
49. Reyes J, Tzakis A, Green M, Nour B, Nalesnik M, Van Thiel D, Martin M, Breinig MK, Fung J, Cooper M, Starzl TE: Posttransplant lymphoproliferative disorders occurring under primary FK 506 immunosuppression. *Transplantation Proc* 23:3044-3046, 1991.
50. Manez R, Martin M, Venkataraman R, Silverman D, Jain A, Warty V, Gonzalez-Pinto I, Kusne S, Starzl TE: Fluconazole therapy in transplant recipients under FK506 therapy. *Transplantation*, in press.
51. Jain A, Venkataraman R, Lever J, Warty V, Fung J, Todo S, Starzl T: FK506 and pregnancy in liver transplant patients. *Transplantation* 56:751, 1993.
52. Lillehei RC and Miller VA: The physiologic response of small bowel of the dog to ischemia including prolonged in vitro preservation of the small bowel with successful replacement and survival. *Ann Surg* 150:543-560, 1959.
53. Starzl TE and Kaupp HA Jr: Mass homotransplantation of abdominal organs in dogs. *Surg Forum* 11:28-30, 1960.
54. Starzl et al. Homotransplantation of multiple visceral organs. *Am J Surg*, 103:219-229, 1960.
55. Kirkman R: Small bowel transplantation. *Transplantation* 37:429-433, 1989.
56. Starzl TE, Rowe M, Todo S, Jaffe R, Tzakis A, Hoffman A, Esquivel C, Porter K, Venkataraman R, Makowka L, Duquesnoy R: Transplantation of multiple abdominal viscera. *JAMA* 261:1449-1457, 1989.
57. Grant D: Intestinal transplantation: Current status. *Transplant Proc* 21:2869-2871, 1989.
58. Murase N, Kim D, Todo S, Cramer DV, Fung J, Starzl TE: Induction of liver, heart and multivisceral graft acceptance with a short course of FK 506. *Transplantation Proc* 22:74-75, 1990.
59. Murase N, Demetris AJ, Matsuzaki T, Yagihashi A, Todo S, Fung J, Starzl TE: Long survival in rats after multivisceral versus isolated small bowel allotransplantation under FK 506. *Surgery* 110:87-98, 1991.
60. Starzl TE, Todo S, Tzakis A, Alessiani M, Casavilla A, Abu-Elmagd K, Fung JJ: The many faces of multivisceral transplantation. *Surg Gynecol Obstet* 172:335-344, 1991.
61. Todo S, Tzakis AG, Abu-Elmagd K, Reyes J, Fung JJ, Nakamura K, Yagihashi A, Jain A, Murase N, Iwaki Y, Demetris AJ, Van Thiel DH, Starzl TE: Cadaveric small bowel and small bowel-liver transplantation in humans. *Transplantation* 53:369-376, 1992.
62. Scotti-Foglieni CL, Marino IR, Cillo U, Furukawa H, Abu-Elmagd K, Nour B, Reyes G, Todo S, Tzakis A, Fung JJ, Starzl TE: Human intestinal and multivisceral transplantation: three years clinical experience at the Pittsburgh Transplantation Institute. In: *Liver Transplantation*, D'Amico D, Bassi N (eds), Masson Publishing, Paris, 1994.
63. Marino IR, Doyle HR, Kang Y, Kormos RL, Starzl TE: Multiple organ procurement. In: *Textbook of Critical Care*, 3rd Edition, (Ayres CM, Grenvik A, Holbrook PR, Shoemaker WC, eds), Saunders, Philadelphia, 1994, in press.
64. Abu-Elmagd K, Fung JJ, Reyes J, Casavilla A, Van Thiel DH, Iwaki Y, Warty V, Nikolaidis N, Block J, Nakamura K, Goldbach B, Demetris J, Tzakis A, Todo S, Starzl TE: Management of intestinal transplantation in humans. *Transplantation Proc* 24:1243-1244, 1992.
65. Abu-Elmagd K, Todo S, Tzakis A, Reyes J, Nour B, Furukawa H, Fung JJ, Starzl TE: Intestinal transplantation: 3 years clinical experience. *Surg Gynecol & Obstets*, in press.
66. Todo S, Tzakis AG, Abu-Elmagd K, Reyes J, Nakamura K, Casavilla A, Selby R, Nour BM, Wright H, Fung JJ, Demetris AJ, Van Thiel DH, Starzl TE: Intestinal transplantation in composite visceral grafts or alone. *Ann Surg* 216:223-234, 1992.
67. Abu-Elmagd KM, Tzakis A, Todo S, Reyes J, Fung J, Nakamura K, Wright H, Furukawa H, Demetris J, Van Thiel DH, Starzl TE: Monitoring and treatment of intestinal allograft rejection in humans. *Transplantation Proc*, 25:1202-1203, 1993.
68. Abu-Elmagd K, Bronsther O, Jain A, Irish W, Fung JJ, Ramos H, Marino I.R., Dodson F, Selby R, Doyle HR, Furukawa H, Gavowski T, Nour B, Reyes J, Pinna A, Rao A, Fontes P, Casavilla A, Jabbour N, Marsh W, Tzakis A, Todo S, Iwatsuki S, Starzl TE. Recent advances in hepatic transplantation at the University of Pittsburgh. In: "Clinical Transplants 1993", Terasaki P.I., ed., 137-152, published by UCLA Tissue Typing Laboratory, 1000 Veterans Avenue, Los Angeles, California, 90024.
69. Monchik GJ and Russell PS: Transplantation of small bowel in the rat: technical and immunological considerations. *Surgery* 70:693-702, 1971.
70. Markus PM, Cai X, Ming W, Demetris AJ, Fung JJ, Starzl TE: FK 506 reverses acute graft-versus-host disease following allogeneic bone marrow transplantation in rats. *Surgery* 110:357-364, 1991.
71. Hoffman AL, Makowka L, Banner B, Cai X, Cramer DV, Pascualone A, Todo S, Starzl TE: The use of FK 506 for small intestine allotransplantation: Inhibition of acute rejection and prevention of fatal graft-versus-host disease. *Transplantation* 49:483-490, 1990.
72. Iwaki Y, Starzl TE, Yagihashi A, Taniwaki S, Abu-Elmagd K, Tzakis A, Fung J, Todo S: Replacement of donor lymphoid tissue in human small bowel transplants under FK 506 immunosuppression. *Lancet* 337:818-819, 1991.
73. Murase N, Demetris AJ, Woo J, Tanabe M, Furuya T, Todo S, Starzl TE: Graft versus host disease (GVHD) after BN to LEW compared to LEW to BN rat intestinal transplantation under FK 506. *Transplantation* 55:1-7, 1993.
74. Starzl TE, Demetris AJ, Murase N, Ildstad S, Ricordi C, Trucco M: Cell migration, chimerism, and graft acceptance. *Lancet* 339:1579-1582, 1992.
75. Starzl TE, Demetris AJ, Murase N, Thomson AW, Trucco M, Ricordi C: Donor cell chimerism permitted by immunosuppressive drugs: a new view of organ transplantation. *Immunol Today* 14:326-332, 1993; also published in *Trends Pharmacological Sci* 14:217-223, 1993.
76. Starzl TE, Demetris AJ, Trucco M, Zeevi A, Ramos H, Terasaki P, Rudert WA, Kocova M, Ricordi C, Ildstad S, Murase N: Chimerism and donor specific nonreactivity 27 to 29 years after kidney allotransplantation. *Transplantation* 55:1272-1277, 1993.
77. Marino IR, Doyle HR, Doria C, Aldrighetti L, Fung JJ, Tzakis AG, Starzl TE: Liver transplantation outcome using donors 60 to 79 years of age. Abstract, accepted at the XVth World Congress of The Transplantation Society, Kyoto, Japan, August 28 - September 2, 1994.
78. UNOS Update 10(4):29-30, 1994.
79. Land W, Hammer C, Brynner H (eds). Indication for organ transplantation. *Transplant Proc* 18(Suppl 3)(4):1-102, 1986.
80. Merriken KJ and Overcast TD: Patient selection for heart transplantation. when is a discriminatory choice discrimination? *J Health Polit Policy Law* 10(1):7-32, 1985.
81. Starzl TE, Todo S, Gordon R, Makowka L, Tzakis A, Iwatsuki S, Marsh W, Esquivel C, Van Thiel D: Liver transplantation in older patients. (Letter to the Editor) *New Engl J Med* 316:484-485, 1987.
82. Auchincloss H: The scientific study of xenografting: 1964-1988. In: *Xenotransplantation - The Transplantation of Organs and Tissues Between Species* Cooper DKC, Kemp E, Reemtsma K, White DJG (eds), pp. 23-43, Springer-Verlag, Berlin, 1991.
83. Jaboulay M: Greffe de reins au pli du coude par soudures arterielles et veineuses. *Lyon Med* 107:575, 1906.
84. Unger E: Nierentransplantation. *Klin Wschr* 47:573, 1910.
85. Neuhof H: The transplantation of tissues. Appleton and Company, New York, 1923, p. 260.
86. Hitchcock CR, Kiser JC, Telander RL, Seljeskog EL: Baboon renal grafts. *JAMA* 189(12):158-161, 1964.
87. Reemtsma K, McCracken BH, Shlegel JU, Pearl MA, Pearce CW, DeWitt CW, Smith PE, Hewitt RL, Flinner RL, Creech O: Renal heterotransplantation in man. *Ann Surg* 160:384, 1964.
88. Starzl TE, Marchioro TL, Peters GN, Kirkpatrick CH, Wilson WEC, Porter KA,

Rifkind D, Ogden DA, Hitchcock CR, Waddell WR: Renal heterotransplantation from baboon to man: Experience with 6 cases. *Transplantation* 2:752-776, 1964.

89. Porter KA: Pathological changes in transplanted kidneys. In: Experience In Renal Transplantation, Starzl TE (ed), Philadelphia, WB Saunders, 1964, pp. 346-357.

90. Bailey LL, Nehlsen-Cannarella SL, Concepcion W, Jolley WB: Baboon-to-human cardiac xenotransplantation in a neonate. *JAMA* 254(23):3321-3329, 1985.

91. Kuss R, Quoted by Starzl TE In: Murase N, Starzl TE, Demetris AJ, Valdivia L, Tanabe M, Cramer D, Makowka L: Hamster to rat heart and liver xenotransplantation with FK506 plus antiproliferative drugs. *Transplantation* 55:701-708, 1993.

92. Ross DN: In: Experience With Human Heart Transplantation (Shapiro H, ed), Butterworths, Durban, 1969.

93. Medawar P: Quoted by Reemtsma K: Heterotransplantation. *Transplant Proc* 1(1):251-255, 1969.

94. Murase N, Starzl TE, Demetris AJ, Valdivia L, Tanabe M, Cramer D, Makowka L: Hamster to rat heart and liver xenotransplantation with FK506 plus antiproliferative drugs. *Transplantation* 55:701-708, 1993.

95. Putnam CW, Halgrimson CG, Groth CG, Kashiwagi N, Porter KA, Starzl TE: Immunosuppression with cyclophosphamide in the dog. *Clin Exp Immunol* 22:323-329, 1975.

96. Starzl TE, Putnam CW, Halgrimson CG, Schroter GT, Martineau G, Launois B, Corman JL, Penn I, Booth AS Jr, Groth CG, Porter KA: Cyclophosphamide and whole organ transplantation in human beings. *Surg Gynecol Obstet* 133:981-991, 1971.

97. Starzl TE, Groth CG, Putnam CW, Corman J, Halgrimson CT, Penn I, Husberg B, Gustafsson A, Cascardo S, Geis P, Iwatsuki S: Cyclophosphamide for clinical renal and hepatic transplantation. *Transplantation Proc* 5:511-516, 1973.

98. Starzl TE: The future of xenotransplantation. *Ann Surg* 216(4):lead article, October, 1992.

99. Starzl TE, Fung J, Tzakis A, Todo S, Demetris AJ, Marino IR, Doyle H, Zeevi A, Warty V, Michaels M, Kusne S, Rudert WA, Trucco M: Baboon to human liver transplantation. *Lancet* 341:65-71, 1993.

100. Todo S, Demetris AJ, Van Thiel D, Fung JJ, Starzl TE: Orthotopic liver transplantation for patients with hepatitis B virus (HBV) related liver disease. *Hepatology* 13(4):619-626, 1991.

101. Starzl TE, Tzakis A, Fung JJ, Todo S, Marino IR, Demetris AJ: Human liver xenotransplantation. *Xeno Today* 1:4-7, 1993.

102. Marino IR, Tzakis AG, Fung JJ, Todo S, Doyle HR, Manez R, Starzl TE: Liver xenotransplantation. In: *Surgical Technology International II* (Braverman MH and Tawes RL, eds) Thomas F. Laszlo, Publisher, 1993, pp. 139-144.

103. Marino IR and Starzl TE: Xenotransplantation. In: *Human In Vitro Organogenesis*, Johnson PC (ed), CRC Press, 1994.

104. Bontempo FA, Lewis JH, Marino IR, Doyle HR, Todo S, Tzakis A, Fung JJ, Starzl TE: Coagulation factor pattern in baboon-to-human liver transplant: acquisition of baboon pattern by recipient. The American Society of Hematology, 34th Annual Meeting, *Blood* 80(10), Suppl. 1:309a, 1992.

105. Starzl TE, Valdivia LA, Murase N, Demetris AJ, Fontes P, Rao AS, Manez R, Marino IR, Todo S, Thomson AW, Fung JJ: The biologic basis of and strategies for clinical xenotransplantation. *Immunological Rev*, in press.

106. Starzl TE, Marchioro TL, Holmes JH, Hermann G, Brittain RS, Stonington OH, Talmage DW, Waddell WR: Renal homografts in patients with major donor-recipient blood group incompatibilities. *Surgery* 55:195-200, 1964.

107. Starzl TE: Patterns of permissible donor-recipient tissue transfer in relation to ABO blood groups. In: Experience In Renal Transplantation, Starzl TE, (ed), WB Saunders, 1964, pp. 37-47.

108. Terasaki PI, Marchioro TL, Starzl TE: Sero-typing of human lymphocyte antigens: Preliminary trials on long-term kidney homograft survivors. In: *Histocompatibility Testing National Acad Sci-Comptat Res Council*, Washington DC, 1965, pp. 83-96.

109. Starzl TE, Lerner RA, Dixon FJ, Groth CG, Brettschneider L, Terasaki PI: Shwartzman reaction after human renal transplantation. *New Engl J Med* 278:642-648, 1968.

110. Starzl TE, Boehmig HJ, Amemiya H, Wilson CB, Dixon FJ, Giles GR, Simpson KM, Halgrimson CG: Clotting changes including disseminated intravascular coagulation, during rapid renal-homograft rejection. *New Engl J Med* 283:383-390, 1970.

111. Starzl TE: Role of Excision of Lymphoid masses In Attenuating The Rejection Process. In: Experience In Renal Transplantation, Starzl TE (ed), WB Saunders, 1964, pp. 126-129.

112. Merkel FK, Bier M, Beavers DC, Merriman WG, Wilson C, Starzl TE: Modification of xenograft response by selective plasmapheresis. *Transplantation Proc* 3:534-537, 1971.

113. Bier M, Beavers DC, Merriman WG, Merkel FK, Eiseman B, Starzl TE: Selective plasmapheresis in dogs for delay of heterograft response. *Transactions - American Society for Art Intern Organs* 16:325-333, 1970.

114. Alexandre GPJ, Latinne D, Gianello P, Squifflet JP: Preformed cytotoxic antibodies and ABO-incompatible grafts. *Clin Transplantation (spec issue)* 5:583-594, 1991.

115. Bygren P, Freiburghaus C, Lindholm T, Simonsen O, Thysell H, Wieslander J: Goodpasture's syndrome treated with straphylococcal protein A immunoabsorption. (Letter) *Lancet* 2:1295-1296, 1985.

116. Fischel RJ, Bolman RM, Platt JL, Najarian JS, Bach FH, Matas AJ: Removal of IgM anti-endothelial antibodies results in prolonged cardiac xenograft survival. *Transplant Proc* 22:1077-1078, 1990.

117. Giles GR, Boehmig HJ, Lilly J, Amemiya H, Takagi H, Coburg AJ, Hathaway

WE, Wilson CB, Dixon FJ, Starzl TE: Mechanism and modification of rejection of heterografts between divergent species. *Transplantation proc* 2:522-538, 1970.

118. Cooper DKC, Human PA, Lexer G, Rose AG, Rees J, Keraan M, Du Toit E: Effects of cyclosporine and antibody adsorption on pig cardiac xenograft survival in the baboon. *J Heart Transplantation* 7:238-246, 1988.

119. Tuso PJ, Cramer DV, Yasunaga C, Cosenza CA, Wu GD, Makowka L: Removal of natural humanxenoantibodies to pig vascular endothelium by perfusion of blood through pig kidneys and livers. *Transplantation* 55:1375-1378, 1993.

120. Corman JL, Kashiwagi N, Porter KA, Andres G, Iwatsuki S, Putnam CW, Popovtzer M, Penn I, Starzl TE: Unsuccessful attempts to control hyperacute rejection of human renal homografts with F(ab')₂ and citrate organ pretreatment. *Transplantation* 16:60-63, 1973.

121. Starzl TE, Weil R III, Koep LJ, McCalmon RT Jr, Terasaki PI, Iwaki Y, Schroter GPJ, Franks JJ, Subryan V, Halgrimson CT: Thoracic duct fistula and renal transplantation. *Ann Surg* 190:474-486, 1979.

122. Starzl TE, Koep LJ, Weil R III, Halgrimson CG, Franks JJ: Thoracic duct drainage in organ transplantation: Will it permit better immunosuppression? *Transplantation Proc* 11:276-284, 1979.

123. Soares M, Lu X, Havaux X, Baranski A, Reding R, Latinne D, Daha M, Lambotte L, Bach FH, Bazin H: In vivo IgM depletion by anti-m monoclonal antibody therapy: the role of IgM in hyperacute vascular rejection of discordant xenografts. *Transplantation* 57:1003-1009, 1994.

124. Kux M, Boehmig HJ, Amemiya H, Torisu M, Yokovama T, Launois B, Popovtzer MM, Wilson CB, Dixon FJ, Starzl TE: Modification of hyperacute canine renal homograft and pig-to-dog heterograft rejection by the intra-arterial infusion of citrate. *Surgery* 70:103-112, 1971.

125. Belitsky P, Popovtzer M, Corman J, Launois B, Porter KA: Modification of hyperacute xenograft rejection by intra-arterial infusion of disodium ethylenediamineteraacetate. *Transplantation* 15:248-251, 1973.

126. Leventhal JR, Dalmasso AP, Cromwell JW, Platt JL, Manivel CJ, Bolman RM III, Matas AJ: Prolongation of cardiac xenograft survival by depletion of complement. *Transplantation* 55:857-866, 1993.

127. Pruitt SK, Kirk AD, Bollinger RR, Marsh HC Jr, Collins BH, Levin JL, Mault JR, Heinle JS, Ibrahim S, Rudolph AR, Baldwin WM III, Sanfilippo F: The effect of soluble complement receptor type I on hyperacute rejection of porcine xenografts. *Transplantation* 57:363-370, 1994.

128. Xia W, Fearon DT, Kirkman RL: Effect of repetitive doses of soluble human complement receptor type I on survival of discordant cardiac xenografts. *Transplant Proc* 25:410-411, 1993.

129. Miyagawa S, Shirakura R, Matsumiya G, Fukushima N, Nakata S, Matsuda H,

- Matsumoto M, Kitamura H, Seya T: Prolonging discordant xenograft survival with anticomplement reagents K76COOH and FUT175. *Transplantation* 55:709-713, 1993.
130. Mundy AR: Prolongation of cat to dog renal xenograft survival with prostacyclin. *Transplantation* 30:226-228, 1980.
131. Makowka L, Miller C, ChapChap P, Podesta L, Pan C, Pressley D, Mazzaferro V, Esquivel CO, Todo S, Banner B, Jaffe R, Saunders R, Starzl TE: Prolongation of pig-to-dog renal xenograft survival by modification of the inflammatory mediator response. *Ann Surg* 206:482-495, 1987.
132. Shaipanich T, Vanwijck RR, Kim JP, Lukl P, Busch GJ, Wilson RE: Enhancement of rat renal allografts with F(ab')₂ fragment of donor specific ant kidney serum. *Surgery* 70:113-121, 1971.
133. Gambiez L, Salame E, Chereau C, Calmus Y, Cardoso J, Ayani E, Houssin D, Weill B: The role of natural IgM in the hyperacute rejection of discordant heart xenografts. *Transplantation* 54:577-583, 1992.
134. White DJG: Complement regulation. *Transplant Proc*, in press.
135. White DJG: Xenografting: present and future. *Xeno* 2(1):1-2, 1994.
136. Langford GA, Yammoutos N, Cozzi E, Lancaster R, Elsome K, Chen P, Richards A, White DJG: Production and analysis of pigs transgenic for human decay accelerating factor. *Transplant Proc*, in press.
137. Fontes P, Rao AS, Ricordi C, Zeevi A, Kocova M, Rybka WB, Ukah FO, Mullen E, Vasko C, Trucco M, Demetris AJ, Fung JJ, Starzl TE: Human to baboon bone marrow transplantation after conditioning with non-lethal irradiation. *Transplantation Proc*, in press.
138. Starzl TE, Demetris AJ, Trucco M, Murase N, Ricordi C, Ildstad S, Ramos H, Todo S, Tzakis A, Fung JJ, Nalesnik M, Rudert WA, Kocova M: Cell migration and chimerism after whole organ transplantation: The basis of graft acceptance. *Hepatology* 17(6):1127-1152, 1993.
139. Starzl TE, Demetris AJ, Murase N, Thomson AW, Trucco M, Ricordi C: Donor cell chimerism permitted by immunosuppressive drugs: a new view of organ transplantation. *Immunol Today* 14:326-332, 1993.
140. Starzl TE, Marchioro TL, Waddell WR: The reversal of rejection in human renal homografts with subsequent development of homograft tolerance. *Surg Gynecol Obstet* 117:385-395, 1963.
141. Starzl TE, Demetris AJ, Trucco M, Ramos H, Zeevi A, Rudert WA, Kocova M, Ricordi C, Ildstad S, Murase N: Systemic chimerism in human female recipients of male livers. *Lancet* 340:876-877, 1992.
142. Starzl TE, Demetris AJ, Trucco M, Ricordi S, Ildstad S, Terasaki P, Murase N, Kendall RS, Kocova M, Rudert WA, Zeevi A, Van Thiel D: Chimerism after liver transplantation for type IV glycogen storage disease and Type I Gaucher's disease. *New Engl J Med* 328:745-749, 1993.
143. Porter KA: Pathology of the orthotopic homograft and heterograft. Chapter 20, p.422-471, In: *Experience in Hepatic Transplantation*, (Starzl TE, Ed), WB Saunders Company, Philadelphia, 1969.
144. Starzl TE, Demetris AJ, Trucco M, Zeevi A, Ramos H, Terasaki P, Rudert WA, Kocova M, Ricordi C, Ildstad S, Murase N: Chimerism and donor specific nonreactivity 27 to 29 years after kidney allotransplantation. *Transplantation* 55:1272-1277, 1993.
145. Tzakis AG, Reyes J, Ramos HC, Zeevi A, Nour B, Reismoen N, Todo S, Starzl TE: Early tolerance in pediatric liver allograft recipients. *J Pediatric Surg*, in press.
146. Belzer FO, Southerd JH: Principles of solid organ preservation by cold storage. *Transplantation* 45:673-676, 1988.
147. Gordon RD, Todo S, Tzakis AG, Stieber A, Staschak SM, Iwatsuki S, Starzl TE: Liver transplantation under cyclosporine: A decade of experience. *Transplantation Proc* 23:1393-1396, 1991.
148. Nossal GJV: Summary of the First International Congress: Perspectives and prospects. *Transplant Proc* 23:3371, 1991.
149. Main JM, Prehn RT: Successful skin homografts after the administration of high dosage X radiation and homologous bone marrow. *J Natl Cancer Inst* 15:1023, 1955.
150. Billingham RE, Brent L, Medawar PB: Actively acquired tolerance of foreign cells. *Nature* 172:603, 1953.
151. Billingham R, Brent L: Quantitative studies on transplantation immunity. IV. Induction of tolerance in newborn mice and studies on the phenomenon of runt disease. *Philos Trans R Soc Lond (biol)* 242:439, 1956.