

Reprinted from: ANNALS OF SURGERY, Vol. 222, No. 3, September 1995

## Outcome Analysis of 71 Clinical Intestinal Transplantations

Satoru Todo, M.D., Jorge Reyes, M.D., Hiroyuki Furukawa, M.D., Kareem Abu-Elmagd, M.D.,  
Randall G. Lee, M.D., Andreas Tzakis, M.D., Abdul S. Rao, M.D., D.Phil.,  
and Thomas E. Starzl, M.D., Ph.D.

# Outcome Analysis of 71 Clinical Intestinal Transplantations

Satoru Todo, M.D., Jorge Reyes, M.D., Hiroyuki Furukawa, M.D., Kareem Abu-Elmagd, M.D.,  
Randall G. Lee, M.D., Andreas Tzakis, M.D., Abdul S. Rao, M.D., D.Phil.,  
and Thomas E. Starzl, M.D., Ph.D.

*From the Pittsburgh Transplant Institute, University of Pittsburgh Medical Center,  
Pittsburgh, Pennsylvania*

---

## Objective

The aim of the study was to determine risk factors associated with graft failure and mortality after transplantation of the intestine alone or as part of an organ complex.

## Summary Background Data

Even with modern immunosuppressive therapies, clinical intestinal transplantation remains a difficult and unreliable procedure. Causes for this and solutions are needed.

## Methods

Between May 1990 and February 1995, 71 intestinal transplantations were performed in 66 patients using tacrolimus and low-dose steroids. The first 63 patients, all but one treated 1 to 5 years ago, received either isolated grafts ( $n = 22$ ), liver and intestinal grafts ( $n = 30$ ), or multivisceral grafts ( $n = 11$ ). Three more recipients of allografts who recently underwent surgery and one undergoing retransplantation were given unaltered donor bone marrow cells perioperatively as a biologic adjuvant.

## Results

Of the first 63 recipients, 32 are alive: 28 have functioning primary grafts and 4 have resumed total parenteral nutrition after graft enterectomy. Thirty-five primary grafts were lost to technical and management errors ( $n = 10$ ), rejection ( $n = 6$ ), and infection ( $n = 19$ ). Regression analysis revealed that duration of surgery, positive donor cytomegalovirus (CMV) serology, inclusion of graft colon, OKT3 use, steroid recycle, and high tacrolimus blood levels contributed to graft loss. All four intestine and bone marrow recipients are alive for 2-3 months without evidence of graft-versus-host disease.

## Conclusion

To improve outcome after intestinal transplantation with previous management protocols, it will be necessary to avoid predictably difficult patients, CMV seropositive donors, and inclusion of the graft colon. Bone marrow transplantation may further improve outcome by ameliorating the biologic barriers of rejection and infection and allowing less restrictive selection criteria.

---

Two problems were predicted with intestinal transplantation for which simultaneous resolution was not easily envisioned. By analogy with bone marrow transplantation<sup>1,2</sup> or with direct experimentation,<sup>3-6</sup> it appeared that either the recipient would reject a histoincompatible intestine or the immunocytes in the leukocyte-laden bowel would gain ascendancy and reject the host (graft-versus-host disease [GVHD]). Recent laboratory and clinical research with intestinal transplantation<sup>7-10</sup> played a critical role in overthrowing this false dogma and in establishing a generic two-way (bidirectional) paradigm of transplantation immunology that is relevant to all organs.<sup>11,12</sup> The reassessment began in November 1987, when a 3-year-old multivisceral recipient developed neither rejection nor GVHD.<sup>13</sup>

In this first example of a functioning human intestinal allograft, the cadaveric organs were depleted of T lymphocytes by infusing the donor with OKT3 treatment before procurement and by *ex vivo* irradiation after their removal. The graft conditioning was suspected to have contributed to the widespread B-cell lymphoma that caused death more than 6 months later.<sup>9,13</sup> During the subsequent 2 years, four more patients achieved prolonged function of cadaveric intestine grafts, transplanted alone<sup>14</sup> or as a component of liver-intestine<sup>15,16</sup> or multivisceral allografts.<sup>17</sup> Only the intestine-alone recipient of Goulet et al.<sup>14</sup> is still alive, but the two liver-intestine recipients of Grant et al. and McAlister et al.<sup>15,16</sup> survived for 58 and 66 months. Additionally, a 60-cm living donor jejunoileal segment transplanted by Deltz et al.<sup>18</sup> to an adult in February 1988 supported nutrition for 61 months and was the first successful isolated intestinal transplantation in the world. Cyclosporine-based immunosuppression was used in all of these cases.

In 1989, the advent of the new immunosuppressant FK 506 (tacrolimus [Prograf, Fujisawa Pharmaceutical Co., Osaka, Japan]) allowed more consistent survival of rat<sup>7,19-21</sup> and human intestinal and multivisceral recipients.<sup>10,22-24</sup> We report here the first 66 patients treated with this drug, all but the last 4 with follow-ups of 1 to 5 years. The last three patients and an additional one undergoing intestinal retransplantation also were given unaltered adjuvant donor bone marrow.

**Table 1. CAUSES OF INTESTINAL FAILURE**

Children		Adults	
Cause	No.	Cause	No.
Volvulus	9	Thrombotic disorder	8
Gastroschisis	8	Chron's disease	7
Necrotizing enterocolitis	6	Desmoid tumor	5
Intestinal atresia	6	Intestinal trauma	4
Pseudo-obstruction	3	Intestinal adhesions	2
Microvillus inclusion disease	3	Pseudo-obstruction	1
Intestinal polyposis	1	Malignant gastrinoma	1
Hirschsprung's disease	1	Volvulus	1
Total	37	Total	29

## METHODS

### Case Material

Under immunosuppression with tacrolimus and low-dose steroids, 71 intestinal transplantations were performed in 66 patients between May 1990 and February 1995. There were 37 children, 16 male and 21 female, with a mean age of  $4.3 \pm 4.2$  years. Twenty-nine were patients were adults, 16 male and 13 female, with a mean age of  $33.3 \pm 9.5$  years. The original diseases ultimately leading to transplantation are listed in Table 1. Two adults had extensive thrombosis of the mesenteric venous system, creating the most difficult technical problems in our experience. Two other adults with this condition died of massive hemorrhage while the incision was made for preliminary dissection of the native organs; they were excluded from the analysis.

All but three of the recipients had been managed by total parenteral nutrition (TPN) for a mean duration of  $36 \pm 35$  months. They had experienced multiple episodes of TPN-related complications, such as line sepsis, major vessel thrombosis, cholelithiasis, renal stones, and hepatic dysfunction. Sixty-two patients (94%) had undergone an average of 3.1 previous laparotomies, and 13 patients had a history of more than 5 previous operations. Of the 54 patients with short-bowel syndrome, only 5 retained the large bowel including the ileocecal valve. The average length of the remaining proximal small bowel was  $14 \pm 13$  cm in children and  $26 \pm 23$  cm in adults.

All of the patients were followed until April 6, 1995. Median follow-up was 21 months, ranging from 1.5 months to 57 months. Because of a moratorium throughout most of 1994, all but four of the patients have had follow-up of at least 1 year (range, 1 to 5 years).

### Donors

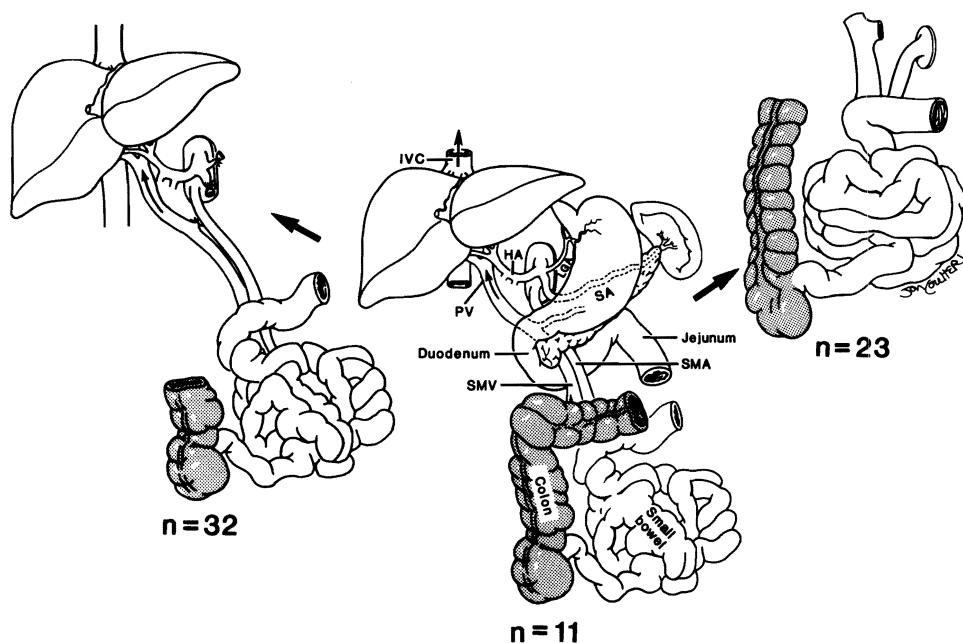
The grafts were obtained from ABO blood type identical cadaveric donors. Lymphocytotoxic cross-match was

Presented at the 115th Annual Meeting of the American Surgical Association, April 6-8, 1995, Chicago, Illinois.

Aided by Project Grant No. DK 29961 from the National Institutes of Health, Bethesda, Maryland.

Address reprint requests to Thomas E. Starzl, M.D., Ph.D., Department of Surgery, 3601 Fifth Avenue, 5C Falk Clinic, University of Pittsburgh, Pittsburgh, PA 15213.

Accepted for publication April 10, 1995.



**Figure 1.** Three kinds of visceral allografts: intestine alone (right), liver and intestine (left), and multivisceral (middle). The number of patients receiving each type of graft is indicated by "n." Colonic segments (shaded) were included in 29 recipients scattered through the three cohorts. IVC: inferior vena cava; PV: portal vein; HA: hepatic artery; SMA: superior mesenteric artery; SMV: superior mesenteric vein; SA: splenic artery; LGA: left gastric artery.

positive in seven patients. Matching of human leukocyte antigen (HLA) was random and poor. Donor management and operative procedures have been described elsewhere.<sup>9,25,26</sup> The University of Wisconsin solution was used for organ preservation in all but one case. Cold ischemia time from aortic clamping until graft revascularization averaged  $7.7 \pm 2.4$  hours.

### Transplantation Operations

The three kinds of allografts are shown in Figure 1: isolated intestinal ( $n = 23$ ), combined intestine and liver ( $n = 32$ ), and multivisceral ( $n = 11$ ). Patients who still had good liver function received intestine only. Those who had inborn and/or TPN-related hepatic dysfunction received liver and intestine. Abdominal multivisceral grafts were reserved for patients who had extensive abnormalities of the gastrointestinal tract caused by absorptive, motility, or vascular disorders. The principles and various modifications of the three generic procedures have been described elsewhere.<sup>9,22-24,26-29</sup> In all three recipient cohorts, some of the grafts contained a segment of large bowel, whereas others did not. Use of the colon was prompted by the high postoperative stomal output and frequent readmissions for treatment of dehydration that were frequently observed otherwise.<sup>23</sup>

### Bone Marrow Transplantation

Bone marrow cells recovered from the same donor as the intestine were infused intravenously into the recipient during the operation in four recent cases (three pri-

mary and one retransplantation). The rationale and methods of simultaneous bone marrow infusion in solid organ transplantation have been reported elsewhere.<sup>30-32</sup> In brief, bone marrow cells were isolated from the thoracolumbar vertebrae of the donor and suspended in 200 mL of Dulbecco's Modified Eagle Medium (Gibco, Grand Island, NY) at a concentration of  $6 \times 10^8$  cells/kg body weight. The infusions were given over 20 minutes, 2 to 12 hours after revascularization of the intestinal graft.

### Postoperative Management

Immunosuppression was achieved with tacrolimus and low-dose steroids, to which prostaglandin E<sub>1</sub> was added briefly during the early postoperative period. Adjustment of tacrolimus dose and/or supplemental prednisone, OKT3, and azathioprine were given for episodes of rejection or for tacrolimus-related adverse effects, as previously described.<sup>22,27,33</sup> In a few cases, azathioprine was given as a third drug from the outset. Depression of white blood cell count ( $<5000$ ) was treated with 3 to 5  $\mu\text{g/kg}$  granulocyte colony-stimulating factor (Neupogen, Amgen, Thousand Oaks, CA). The complex infectious disease and nutritional management was as described elsewhere.<sup>22,27,33,34</sup>

### Sampling Protocols

#### Rejection Surveillance

Histopathologic study of endoscope-guided biopsies was done twice weekly until hospital discharge. The clin-

ical diagnosis of rejection was not accepted unless confirmed histopathologically by criteria described elsewhere.<sup>22,35</sup> More than 1440 intestinal biopsy specimens have been examined by a single pathologist (R.G.L.).

#### Graft-Versus-Host Disease Surveillance

Suspicious skin lesions were biopsied and studied by routine histology, immunohistologic staining for donor-specific HLA antigens, and *in situ* hybridization technique using the Y-chromosome-specific probe, as described elsewhere.<sup>12,36,37</sup>

#### Cytokines

Plasma samples collected serially from patients who did not receive colon ( $n = 9$ ) and from patients receiving colon segments ( $n = 7$ ) were stored ( $-70^{\circ}\text{C}$ ) and analyzed for tumor necrosis factor- $\alpha$ , interleukin- $1\beta$ , and interleukin-6 by the enzyme-linked immunosorbent assay method (R&D Systems, Minneapolis, MN).

#### Chimerism

Donor leukocyte chimerism was followed before and after intestinal transplantation in four patients who also were given perioperative bone marrow and in nonmarrow control recipients of the same kinds of allografts. Leukocytes circulating in the recipient peripheral venous blood were identified as donor with donor-specific anti-HLA class I monoclonal antibodies and by fluorescent-activated cell sort analysis.<sup>30</sup> The results were confirmed using probes directed against HLA class II chromosomes by polymerase chain reaction (PCR) and by *in situ* hybridization technique with Y-chromosome-specific probe.

#### Statistics

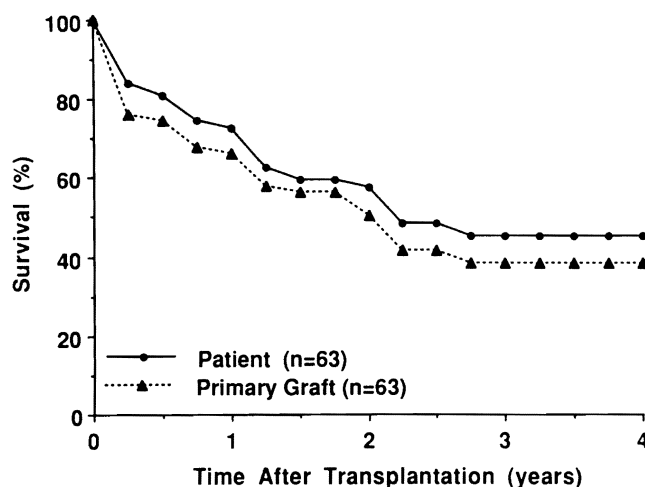
Figures are expressed as the mean plus or minus the standard deviation of the mean. Differences in group means were tested using the one-way analysis of variance, and differences in proportions were examined using Pearson's chi square test. Patient and graft survival curves were generated using the life table method and were compared between the groups using the log-rank (Mantel-Cox) test. To analyze the risk factors for morbidity, graft loss, and mortality, Cox's proportional hazards model was used.

## RESULTS

### Cases Without Bone Marrow

#### Patient Survival

All but 1 of the 63 patients have a potential follow-up of at least 1 year (range, 1 to 5 years) (Fig. 2). Thirty-two



**Figure 2.** Actuarial patient and primary graft survival of the first 63 recipients of the procedures depicted in Figure 1.

are still alive. There was no survival difference with the three kinds of operations (Fig. 3) or between the pediatric and adult age groups. Twenty-eight of these 32 surviving patients still bear their primary allografts, all of which function. The other four patients were returned to hyperalimentation after graft enterectomy, and one patient later underwent successful retransplantation.

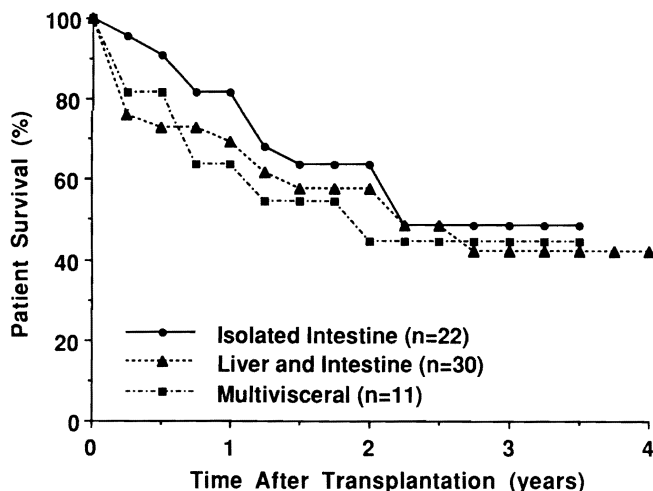
#### Graft Survival and Function

All of the four patients returned to chronic intravenous nutrition were in the intestine-alone group (Fig. 4). Thus, although a slightly better early patient survival (83% at 1 year) (Fig. 3) was obtained after the intestine-alone procedure (not significant), this operation succeeded in restoring alimentary function at the lowest rate at all follow-up times after 9 months. The poor survival of patients in the intestine-alone group compared with that of patients who underwent other operations is shown in Figure 5. The results were similar in adults and children.

Successfully treated patients had gratifying rehabilitation. Although absorption was never completely normal, 27 of the 28 patients still bearing their original grafts are free of intravenous support, and some even have had to go on obesity-control diets. Several of the patients take special dietary precautions to prevent diarrhea or dysmotility symptoms. Only one patient requires intermittent nighttime intravenous supplementation.

#### Cause of Failure

Thirty-five (55.6%) of the 63 primary grafts were lost by recipient death or as the result of their surgical removal followed by an immediate attempted retransplantation ( $n = 4$ ) or return to hyperalimentation ( $n = 4$ ).

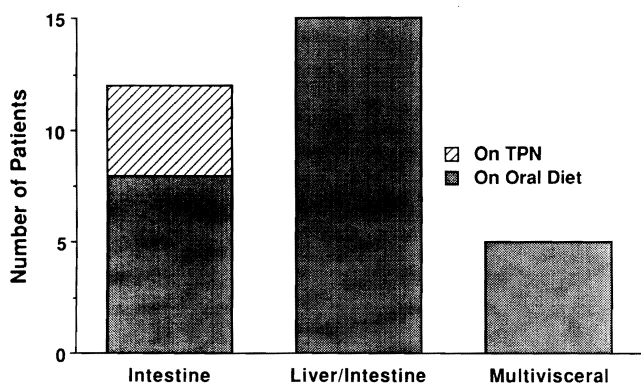


**Figure 3.** Patient survival after the three types of allografts shown in Figure 1.

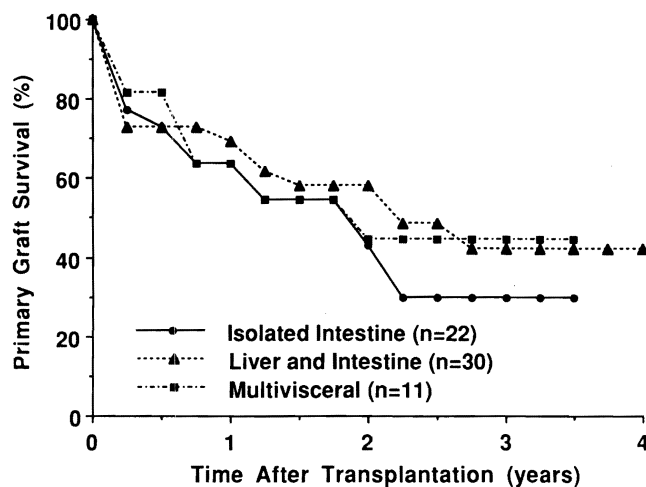
The principal reasons for the primary graft losses are summarized schematically in Figure 6.

In 10 cases, the failures could be traced back to surgical or management errors. Eight of these 10 grafts were functioning at or shortly before the time of their loss. The subgroup of technical surgical errors, all in children, included intestinal anastomotic leakage, hepatic artery thrombosis, biliary anastomotic leakage, and cerebral infarction associated with intraoperative cardiac arrest. One of the six grievous management errors (Fig. 6) was nonrecognition of a pre-existing pneumonia. The graft was removed immediately, immunosuppression was stopped, and the patient was successfully returned to hyperalimentation. Other management errors were overdosing or underdosing of tacrolimus or other agents ( $n = 4$ ), including a lethal infusion of hypertonic saline. There was one failure to diagnose drug noncompliance.

The exact reason for loss of the other 25 grafts was



**Figure 4.** Primary graft function in the 32 surviving patients after each of the three different transplantations. Note that 4 of the 12 intestine-alone recipients are alive despite removal of their transplants.

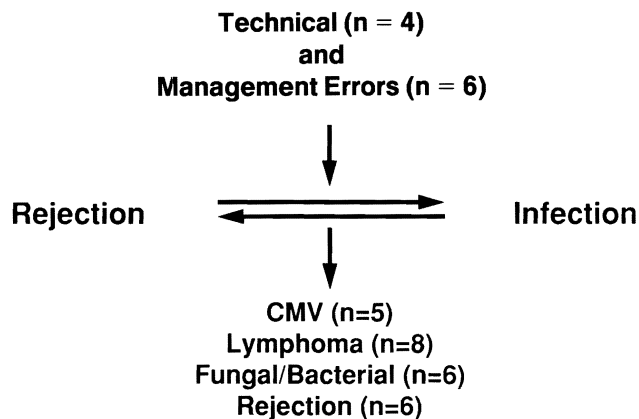


**Figure 5.** Allograft survival with the three different kinds of operations. The differences are not statistically significant.

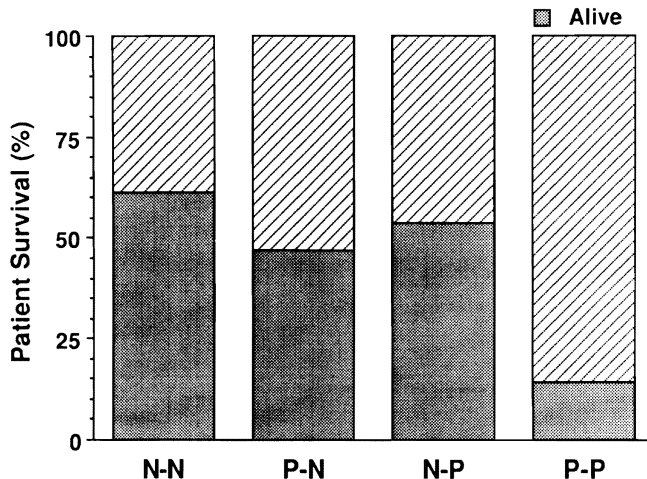
difficult to pinpoint because of multiple interlocking factors (Fig. 6). The principal diagnosis was rejection in only 6 cases, whereas an infectious complication attributable to antirejection therapy was the major diagnosis in 19. The responsible microorganisms included bacteria and fungi ( $n = 6$ ), but among the viruses, cytomegalovirus (CMV) alone accounted for nearly as many losses ( $n = 5$ ). Moreover, Epstein-Barr virus (EBV) associated B-cell lymphomas occurred in 12 (19%) of the 63 patients, of whom 8 lost their grafts and died of this complication. Eleven of the 12 patients who developed the lymphomas had been treated with OKT3.

#### Retransplantation

Four patients underwent retransplantation on the same day as primary graft removal (two liver-intestine) or 1 to 2 months later (two intestine only). They died 47 days, 57 days, 71 days, and 147 days after the second



**Figure 6.** Causes of the 35 primary graft losses.



**Figure 7.** Effect on patient survival of donor and recipient CMV+ serology. N-N: negative donor-negative recipient (26 patients); P-N: positive donor-negative recipient (13 patients); N-P: negative donor-positive recipient (17 patients); and P-P: positive donor-positive recipient (7 patients).

procedure, with the principal diagnoses of rejection ( $n = 2$ ), B-cell lymphoma ( $n = 1$ ), and systemic bacterial infection ( $n = 1$ ). In addition, liver retransplantation was unsuccessful in a pediatric patient who developed isolated hepatic artery thrombosis 11 days after combined intestine and liver transplantation.

A fifth intestinal retransplantation was performed in an intestine-only recipient 11 months after graft enterectomy. This patient, who is alive, also was given bone marrow from the second intestine donor (see below).

#### Risk Factors

With univariate and multivariate analysis, 6 statistically significant risk factors for graft loss and/or death among 28 variables examined were high FK 506 blood levels, prednisone bolus therapy, administration of OKT3, length of operation (reflecting the technical difficulty of the procedure), CMV plus status of donor and recipient, and inclusion of a segment of colon with the graft. The first four of these risk factors have often been described with transplantation of other organs and will not be considered here except to mention their obvious relation to the infectious complications. The fifth and sixth risk factors were more specific to the intestinal recipient.

The CMV effect was pervasive. Serologically negative CMV recipients are surviving after 1 to 5 years at a rate of 62% if their donors were CMV negative, but only at a rate of 47% if their donors were CMV positive (Fig. 7). An adverse effect on survival also was observed when the recipient already was serologically CMV positive at operation. Fifty-four percent survive to date if a CMV-neg-

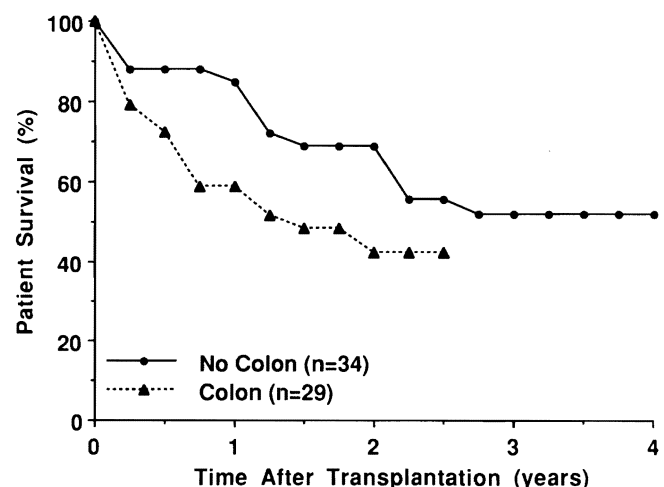
ative donor was used, but only 14% with a CMV-positive donor (Fig. 7). As recently reported in detail,<sup>38</sup> therapy that can regularly control this infection in other kinds of allograft recipients was only marginally effective in the intestinal recipient. Once the clinical diagnosis of CMV was made, the predominant target in essentially all cases was the intestinal allograft itself. The resulting ulcerations were associated with bacterial translocation.

Inclusion of a colonic segment in 29 patients was a significant risk factor. Significantly better graft survival was observed in 34 patients without the colon than with it (Fig. 8). Although the negative colon influence was more pronounced in adults, it also was identified in the pediatric recipients.

A possible explanation was the postoperative increase in plasma tumor necrosis factor- $\alpha$  (and by implication, endotoxemia) in recipients given colon *versus* the lower levels in nine patients whose grafts did not contain colon. Interleukin-1 levels were barely detectable in both cohorts, and interleukin-6 responses were comparable.

#### Bone Marrow Augmentation

Two of the augmentation patients received intestine alone, and two were given liver plus intestine (Table 2). All were classified as high risk. Patient 1, an intestinal retransplant recipient, had a monoclonal B-cell lymphoma that had been in remission since discontinuance of immunosuppression and removal of his primary graft 11 months previously. Although the lymphocytotoxic cross-match was negative, he had a high antibody index (plasma renin activity) before retransplantation and experienced a severe rejection during the second postoperative week, which was reversed with OKT3. Shortly af-



**Figure 8.** Survival of 29 primary grafts containing a colon segment *versus* 34 grafts not including colon ( $p < 0.0313$ ).

**Table 2. INTESTINAL TRANSPLANTATION WITH DONOR BONE MARROW AUGMENTATION ( $6 \times 10^8$ /KG CELLS IV) WITH ALL RECIPIENTS CURRENTLY HAVING 0.5–2.5% CIRCULATING DONOR LEUKOCYTES**

Operation	Age	Duration of Operation (hr)	CMV		Complications
			Donor	Recipient	
Intestine* (retransplantation)	4.3	10	—	+	Rejection (reversible), EBV
Intestine†	13.2	9.4	—	+	None
Liver/bowel	15.0	12.8	+	—	None
Liver/bowel‡	29.2	27	—	+	Pancreatitis, gangrene, jejunum 50 cm resected

EBV = Epstein-Barr virus antigenemia, B-cell lymphoma in remission; CMV = cytomegalovirus.

\* First intestinal transplant in October 1991; graft enterectomy after 2.1 years and return to parenteral hyperalimentation in 11 months because of B-cell lymphoma.

† Previous liver transplantation in December 1984; intestine infarcted by volvulus in March 1994.

‡ Protein C/S deficiency; complete portal and mesenteric thrombosis.

terward, EBV reactivation was diagnosed by *in situ* hybridization for Epstein-Barr early RNA (EBER), which showed staining of the intestinal biopsy specimen. The diagnosis was confirmed with semiquantitative EBV antigen titer measurement by PCR. The EBV infection resolved within 2 weeks after reduction of immunosuppression and administration of two doses of gamma-interferon (Actimmune, Genentech, Inc., San Francisco, CA).

Patient 2 had undergone a liver transplantation in 1984 and lost his native intestine to a volvulus 10 years later. This patient, like the other three, had extensive previous procedures. Patient 4, whose complete splanchnic venous thrombosis was secondary to protein C and S deficiency, required a 27-hour operation. All four recipients faced the CMV handicap (Table 2). Patients 1, 2, and 3 are receiving oral nutrition, and Patients 2 and 3 are at home after discharge 4 and 5 weeks postoperatively. Patient 4 developed severe acute pancreatitis postoperatively and required resection of a 50-cm gangrenous midjejunum graft during the 3rd postoperative week. He is still in the intensive care unit.

Donor cells were easily detected in all four bone marrow augmented bowel recipients by either PCR or flow cytometry or both (Fig. 9) up to the last sample tested (postoperative day 58). In the female child (Patient 65) who received a male allograft, the presence of donor cells was confirmed by fluorescent *in situ* hybridization for the Y chromosome. As expected, very low levels (by PCR only) of donor cell chimerism were detected in the peripheral blood of three of the four nonaugmented control patients for up to 16 weeks after transplantation.

No evidence of GVHD was found in any of the four recipients who were given bone marrow cells.

## DISCUSSION

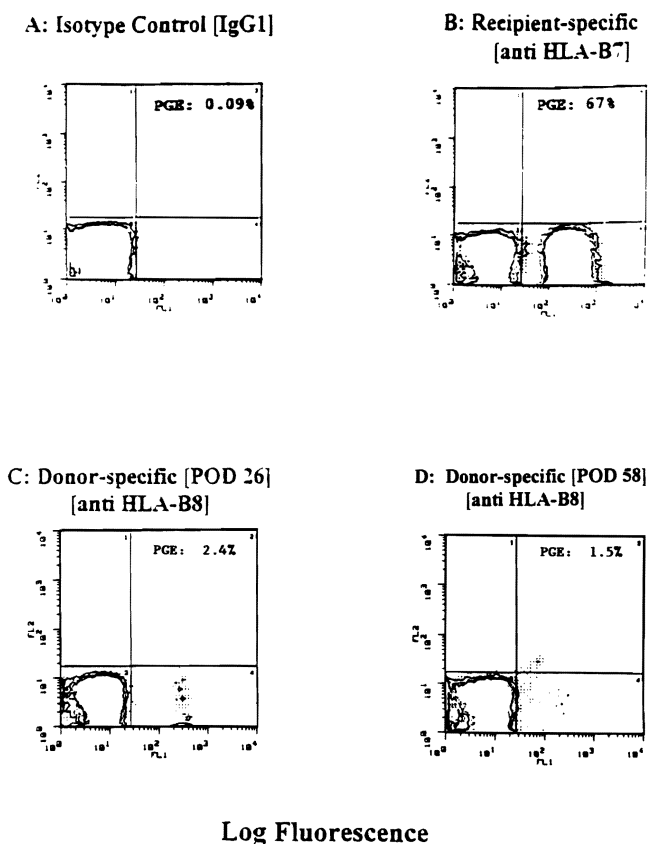
The three procedures used in this clinical series are products of the post-World War II renaissance of surgical

research laboratories. The intestine-alone operation was essentially the same as developed in dogs and described to the American Surgical Association 36 years ago by Lillehei et al.<sup>39</sup> The multivisceral procedure and the liver-intestine variant first used by Grant et al.<sup>15</sup> are derived from an experimental canine operation reported in 1960.<sup>3,40</sup> All three operations are interrelated, because the liver, pancreas, and intestine—whether allograft or host—can each influence the immunologic environment and metabolic function of the others.<sup>9</sup>

With only one exception, the first 63 patients treated with these difficult operations have potential follow-ups of 1 to 5 years. Thirty-two are still alive. In our earlier reports comparing the different operations, the most encouraging results were with the intestine alone.<sup>22,23</sup> This advantage lessened with time,<sup>27</sup> so that by 2 years, there was no longer a significant difference between the three cohorts, and the graft survival after the intestine-alone operation turned out to be inferior. Yet, one of these patients with a failed graft has now had successful retransplantation after graft enterectomy and 11 months of intervening intravenous nutrition and recovery from a B-cell lymphoma. The strategy of interval support has not yielded great dividends, but it is expected to. Because a “rest period” is not an option for patients with failed complex grafts that contain liver, we have never performed multivisceral or liver-intestine procedures in patients who need only the intestine.

Despite the numerous gratifying successes generated by this experience, we self-imposed a moratorium on further case accrual throughout most of 1994. The decision was made because we had been unable, despite much experience, to reduce the previously described mortality rate, difficulty of postoperative management, and need for excessive hospitalization.<sup>22,23,27,41–43</sup> The problems were no different in principle than those encountered with recipients of other transplanted organs and largely





**Figure 9.** Detection of donor cells in the peripheral blood on bone marrow-augmented small-bowel recipient (Patient 1, Table 2) by fluorescence-activated cell sorter analysis. Staining with (A) isotype control (IgG1), (B) recipient-specific antibody (HLA-B7), and donor specific antibody (HLA-B8) on (C) POD 26 and (D) 58, respectively. For analysis, using Consort 30 (Becton-Dickinson, Mountain View, CA) acquisition software,  $2 \times 10^4$  events were acquired on a FACStar<sup>R</sup> (Becton-Dickinson). PGE: percent gated events. The circulating donor cells are in the right lower quadrant of C and D.

stemmed from the inability to completely control rejection without resorting to chronic heavy immunosuppression.

However, the management difficulties were more frequent and intractable, often leading to infections that were the leading cause of death. The interface of rejection and infection appeared to be closer in these patients than after other kinds of organ transplantation. Because the bowel wall becomes a bacterial sieve when it is damaged by any mechanism, including rejection,<sup>22</sup> the specter of bacterial translocation resulted in the need for heavy immunosuppression. Thus, three of the six significant risk factors were high FK 506 levels, high-dose steroids, and use of OKT3. A sinister aspect of the infection problem was the development of EBV-associated B-cell lymphomas that have euphemistically been termed "lymphoproliferative disorders."<sup>44</sup> The lymphomas occurred in 12 (19%) of the 63 patients and caused 8 deaths.

The three additional significant risk factors identified against this complex background could be construed to suggest (1) avoidance of predictably difficult patients, such as those with multiple previous operations, (2) ineligibility of CMV+ donors and recipients, and (3) omission of colon from the allograft to reduce the potential liability of endotoxemia.<sup>45-47</sup> However, the first two reforms would preclude treatment for almost all of the patients who need it, and the third would ultimately diminish the quality of postoperative life. Consequently, less restrictive strategies are being evaluated, to which intestinal transplant research has provided seminal clues, into the generic mechanisms of graft acceptance.

In 1990, it was demonstrated in established rat<sup>7</sup> and human<sup>8-10</sup> intestinal and multivisceral allografts that the intestine had changed into a genetic composite after surgery. The epithelial and vascular endothelial components remained donor phenotype, but the leukocyte substrate of the lamina propria and elsewhere became repopulated with recipient cells. It had been known that this transformation occurred with the liver,<sup>48,49</sup> and it was suspected and subsequently proven that the same transformation occurred in all established allografts, regardless of the organ.<sup>12,50</sup> The natural question was the fate of the replaced donor leukocytes of the graft. The answer was that, like events after any kind of transplantation, the intestinal leukocytes migrated from the allograft and in successful cases established residence throughout the recipient. We have postulated that these events are the seminal basis of allograft acceptance.<sup>11,12,36,37,51</sup> The mutually canceling effect of the co-existing leukocyte populations (donor and recipient) explained the freedom from GVHD of the intestinal as well as liver recipients.<sup>12</sup>

Although the intestine is a rich source of these migratory white cells, our laboratory studies in rats<sup>52</sup> and the historic contributions of Monaco et al.<sup>53,54</sup> have shown that intestinal leukocytes have inferior tolerogenic qualities compared with bone marrow cells. In addition, the lineage profile of the migratory intestinal cells were predisposed to GVHD,<sup>55-57</sup> a complication never caused in the rat models by migratory donor hepatic leukocytes or suspensions of bone marrow cells.<sup>52</sup>

To exploit the tolerogenicity and safety of donor bone marrow leukocytes, we began a trial 2½ years ago of donor leukocyte augmentation with these cells.<sup>30-32</sup> In the first 100 kidney, liver, heart, or lung recipients, no adverse effects, including GVHD, and considerable benefit were observed. Intestinal recipients were excluded from the trial during the first 2 years because of concern that the extra load of bone marrow leukocytes might cause GVHD. Eventually, the favorable experience with the other organs prompted extension of the bone marrow strategy to intestinal recipients, using the same FK 506-

steroid immunosuppression as before. The first four intestinal recipients treated in this way are alive after 2 to 3 postoperative months. Donor cells account for approximately 1% to 2.5% of their circulating mononuclear cells. There has been no evidence of GVHD.

Aside from this direct therapeutic application, other implications of the recently evolved two-way paradigm of transplantation<sup>11,12,36,37,51,58</sup> are relevant in assessing the intestinal transplant experience. First, the unusual infectivity of CMV is not enigmatic. Because this virus is lymphotropic and contained in the migratory cells, it is not hard to envision its massive and efficient inoculation in either direction (graft to host or *vice versa*), proportional to the magnitude of cell migration that begins within a few minutes after graft revascularization.

Second, the etiology, prevention, and management of the EBV-associated B-cell lymphomas that have plagued efforts at intestinal transplantation also become more understandable. Because of the now obsolete belief that intestinal grafts should be T-cell (or pan-leukocyte) depleted to avoid GVHD,<sup>4,6,59-63</sup> most of the bowel donors before 1990 were treated before organ procurement with antilymphoid preparations, or the allografts were irradiated.<sup>13,15,16,64,65</sup> Most of the patients who survived the operation developed B-cell lymphomas of recipient origin. The lymphomas were similar to those associated with overimmunosuppression in recipients of other organs,<sup>66,67</sup> especially after the T-cell-directed agents cyclosporine and<sup>68,69</sup> FK 506<sup>70</sup> became available.

In a series of studies,<sup>71</sup> Klein delineated the cellular and molecular mechanisms by which these iatrogenic interventions or inherited immunodeficiency diseases allow an inherently self-limited EBV infection to proceed to a malignancy. In essence, surveillance of potentially neoplastic virus-infected B cells depends on the intact T-cell system that the various procedures used in transplantation disarm in the donor or recipient leukocyte populations, or both. Suspicion that this was the reason for B-cell lymphomas in our first multivisceral recipients caused us more than 6 years ago to recommend against either donor or allograft conditioning.<sup>9,72</sup> When B-cell lymphomas develop in organ recipients, restoration of T-cell surveillance over EBV (whose antigenicity is expressed during replication<sup>71</sup>) can be accomplished by lightening immunosuppression,<sup>68</sup> but at the risk of rejection.

Bone marrow recipients who are cytoablated (with total body irradiation or drugs) and given T-cell-depleted allografts have an increased incidence of B-cell lymphomas. These are of donor (not recipient) origin, and the option of reducing maintenance immunosuppression usually is not available. However, Papadopoulos et al.<sup>73</sup> reported a regression of these donor phenotype lymphomas by infusing peripheral blood cytotoxic T lympho-

cytes collected from the original marrow donor. This mimics the therapeutic effect achieved in organ recipients by lightening immunosuppression and allowing recipient T-cell surveillance. Predictably, the penalty of such treatment in the bone marrow recipients was GVHD.

All of the B-cell lymphomas reported in intestinal recipients have been of recipient origin. It is possible to use immunotherapy in such patients to treat tumors of this kind that fail to respond to reduction immunosuppression. Unaltered recipient buffy coat or bone marrow could be collected preoperatively and stored for such an exigency, to be used as a last resort.

A better understanding of the pathogenesis of B-cell lymphomas and other problems of intestinal transplantation is the first step to solving them, particularly if complications are of a unifying etiology. However, progress will depend on obtaining stable graft acceptance more quickly and completely, thereby decreasing the harm caused by high-dose chronic immunosuppression. The administration of adjuvant donor bone marrow has this objective. Although there is a solid experimental base for this approach, its clinical value is unproven.

Even if the bone marrow initiative is effective, these often difficult operations will not be made easier to perform. Nevertheless, intestinal transplantation seems to us at least as far along as liver transplantation was little more than 12 years ago or even kidney transplantation in the early 1970s.

## References

1. Billingham RE. Reactions of grafts against their hosts: transplantation immunity works both ways—hosts destroy grafts and grafts may harm hosts. *Science* 1959; 130:947-953.
2. Vriesendorp HM. Engraftment of hemopoietic cells. In van Bekkum DW, Lowenberg B, eds. *Bone Marrow Transplantation: Biological Mechanisms and Clinical Practice*. New York: Marcel Dekker, Inc; 1985:76-78,114-119.
3. Starzl TE, Kaupp HA Jr., Brock DR, et al. Homotransplantation of multiple visceral organs. *Am J Surg* 1962; 103:219-229.
4. Monchik GJ, Russell PS. Transplantation of the small bowel in the rat: technical and immunologic considerations. *Surgery* 1971; 70:693-702.
5. Lillehei RC, Manax WG, Lyona GW, Dietzman RH. Transplantation of gastrointestinal organs, including small intestine and stomach. *Gastroenterology* 1966; 51:966.
6. Cohen Z, MacGregor AB, Moore KTH, et al. Canine small bowel transplantation. *Arch Surg* 1976; 111:248.
7. Murase N, Demetris AJ, Matsuzaki T, et al. Long survival in rats after multivisceral *versus* isolated small bowel allotransplantation under FK 506. *Surgery* 1991; 110:87-98.
8. Iwaki Y, Starzl TE, Yagihashi A, et al. Replacement of donor lymphoid tissue in human small bowel transplants under FK 506 immunosuppression. *Lancet* 1991; 337:818-819.
9. Starzl TE, Todo S, Tzakis A, et al. The many faces of multivisceral transplantation. *Surg Gynecol Obstet* 1991; 172:335-344.
10. Todo S, Tzakis AG, Abu-Elmagd K, et al. Cadaveric small bowel

- and small bowel-liver transplantation in humans. *Transplantation* 1992; 53:369-376.
11. Starzl TE, Demetris AJ, Murase N, et al. Cell migration, chimerism, and graft acceptance. *Lancet* 1992; 339:1579-1582.
  12. Starzl TE, Demetris AJ, Trucco M, et al. Cell migration and chimerism after whole organ transplantation: the basis of graft acceptance. *Hepatology* 1993; 17:1127-1152.
  13. Starzl TE, Rowe MI, Todo S, et al. Transplantation of multiple abdominal viscera. *JAMA* 1989; 261:1449-1457.
  14. Goulet O, Devillon Y, Brousse N, et al. Successful small bowel transplantation in an infant. *Transplantation* 1992; 53:940-943.
  15. Grant D, Wall W, Mimeault R, et al. Successful small-bowel/liver transplantation. *Lancet* 1990; 335:181-184.
  16. McAlister V, Wall W, Ghent C, et al. Successful small intestine transplantation. *Transplant Proc* 1992; 24:1236-1237.
  17. Margreiter R, Konigsrainer A, Schmid T, et al. Successful multivisceral transplantation. *Transplant Proc* 1992; 24:1226-1227.
  18. Deltz E, Schroeder P, Gebhardt H, et al. Successful clinical small bowel transplantation: report of a case. *Clin Transplantation* 1989; 3:89-91.
  19. Murase N, Kim D, Todo S, et al. Induction of liver, heart and multivisceral graft acceptance with a short course of FK 506. *Transplant Proc* 1990; 22:74-75.
  20. Lee K, Stangl MJ, Todo S, et al. Successful orthotopic small bowel transplantation with short term FK 506 immunosuppressive therapy. *Transplant Proc* 1990; 22:78-79.
  21. Hoffman AL, Makowka L, Banner B, et al. The use of FK 506 for small intestine allotransplantation: inhibition of acute rejection and prevention of fatal graft-versus-host disease. *Transplantation* 1990; 49:483-490.
  22. Todo S, Tzakis AG, Abu-Elmagd K, et al. Intestinal transplantation in composite visceral grafts or alone. *Ann Surg* 1992; 216:223-234.
  23. Todo S, Tzakis A, Reyes J, et al. Small intestinal transplantation in humans with or without colon. *Transplantation* 1994; 57:840-848.
  24. Todo S, Tzakis A, Abu-Elmagd K, et al. Abdominal multivisceral transplantation. *Transplantation* 1995; 59:234-240.
  25. Casavilla A, Selby R, Abu-Elmagd K, et al. Logistics and technique for combined hepatic-intestinal retrieval. *Ann Surg* 1992; 216:605-609.
  26. Furukawa H, Abu-Elmagd K, Reyes J, et al. Technical aspects of intestinal transplantation. In Braverman MH, Tawes RL, eds. *Surgical Technology International. Vol 2*. San Francisco, CA: Universal Medical Press Inc; 1994:165-170.
  27. Abu-Elmagd K, Todo S, Tzakis A, et al. Three years clinical experience with intestinal transplantation. *J Am Coll Surg* 1994; 179:385-400.
  28. Tzakis AG, Todo S, Reyes J, et al. Piggyback orthotopic intestinal transplantation. *Surg Gynecol Obstet* 1993; 176:297-298.
  29. Tzakis AG, Nour B, Reyes J, et al. Endorectal pull through of transplanted colon as part of intestinal transplantation. *Surgery* 1995; 117:451-453.
  30. Fontes P, Rao A, Demetris AJ, et al. Augmentation with bone marrow of donor leukocyte migration for kidney, liver, heart, and pancreas islet transplantation. *Lancet* 1994; 344:151-155.
  31. Starzl TE, Demetris AJ, Rao AS, et al. Spontaneous and iatrogenically augmented leukocyte chimerism in organ transplant recipients. *Transplant Proc* 1994; 26:3071-3076.
  32. Rao AS, Fontes P, Zeevi A, et al. Augmentation of chimerism in whole organ recipients by simultaneous infusion of donor bone marrow cells. *Transplant Proc* 1995; 27:210-212.
  33. Abu-Elmagd K, Fung JJ, Reyes J, et al. Management of intestinal transplantation in humans. *Transplant Proc* 1992; 24:1243-1244.
  34. Reyes J, Tzakis AG, Todo S, et al. Nutritional management of intestinal transplant recipients. *Transplant Proc* 1993; 25:1200-1201.
  35. Nakamura K, Nalesnik M, Jaffe R, et al. Morphologic monitoring of human small bowel allografts. *Transplant Proc* 1993; 25:1212.
  36. Starzl TE, Demetris AJ, Trucco M, et al. Systemic chimerism in human female recipients of male livers. *Lancet* 1992; 340:876-877.
  37. Starzl TE, Demetris AJ, Trucco M, et al. Chimerism after liver transplantation for type IV glycogen storage disease and Type I Gaucher's disease. *N Engl J Med* 1993; 328:745-749.
  38. Manez R, Kusne S, Green M, et al. Incidence and risk factors associated with the development of cytomegalovirus disease after intestinal transplantation. *Transplantation* 1995; 59:1010-1015.
  39. Lillehei RC, Goott B, Miller FA. The physiologic response of the small bowel of the dog to ischemia including prolonged *in vitro* preservation of the bowel with successful replacement and survival. *Ann Surg* 1959; 150:543.
  40. Starzl TE, Kaupp HA Jr. Mass homotransplantation of abdominal organs in dogs. *Surg Forum* 1960; 11:28-30.
  41. Abu-Elmagd KM, Tzakis A, Todo S, et al. Monitoring and treatment of intestinal allograft rejection in humans. *Transplant Proc* 1993; 25:1202-1203.
  42. Tzakis AG, Todo S, Reyes J, et al. Clinical intestinal transplantation: focus on complications. *Transplant Proc* 1992; 24:1238-1240.
  43. Tzakis A, Starzl TE. Liver transplantation. In Ashcraft KW, Holder TM, eds. *Pediatric Surgery*. 2nd ed. Philadelphia: WB Saunders Co; 1992:505-524.
  44. Hanto DW, Frizzera G, Gajl-Peczalska KJ, Simmons RL. Epstein-Barr virus, immunodeficiency, and B cell lymphoproliferation. *Transplantation* 1985; 39:461-472.
  45. Yokoyama I, Todo S, Miyata T, et al. Endotoxemia and human liver transplantation. *Transplant Proc* 1989; 21:3833-3841.
  46. Miyata T, Yokoyama I, Todo S, et al. Endotoxemia, pulmonary complications and thrombocytopenia with clinical liver transplantation. *Lancet* 1989; 8656:189-191.
  47. Miyata T, Todo S, Imventarza O, et al. Endogenous endotoxemia during orthotopic liver transplantation in dogs. *Transplant Proc* 1989; 21:3861-3862.
  48. Kashiwagi N, Porter KA, Penn I, et al. Studies of homograft sex and of gamma globulin phenotypes after orthotopic homotransplantation of the human liver. *Surg Forum* 1969; 20:374-376.
  49. Porter KA. Pathology of the orthotopic homograft and heterograft. In Starzl TE, ed. *Experience in Hepatic Transplantation*. Philadelphia: WB Saunders Co; 1969:464-465.
  50. Randhawa PS, Starzl TE, Ramos H, et al. Allografts surviving for 26-29 years following living related kidney transplantation: analysis by light microscopy, *in situ* hybridization for the Y chromosome, and anti-HLA antibodies. *Am J Kidney Dis* 1994; 24:72-77.
  51. Starzl TE, Demetris AJ, Trucco M, et al. Chimerism and donor specific nonreactivity 27 to 29 years after kidney allotransplantation. *Transplantation* 1993; 55:1272-1277.
  52. Murase N, Tanabe M, Fujisaki S, et al. Variable chimerism, graft versus host disease, and tolerance after different kinds of cell and solid organ transplantation from Lewis to Brown-Norway rats. *Transplantation* 1995 (in press).
  53. Monaco AP, Wood ML, Maki T, Gozzo J. The use of donor-specific bone marrow to induce specific unresponsiveness (tolerance) to tissue allografts. In Ildstad ST, ed. *Chimerism and Tolerance*. Austin, TX: RG Landes Co; 1994:99.
  54. Monaco AP, Wood ML. Studies on heterologous antilymphocyte serum in mice. VII. Optimal cellular antigen for induction of im-

- munologic tolerance with antilymphocyte serum. *Transplant Proc* 1970; 2:489.
55. Murase N, Demetris AJ, Woo J, et al. Lymphocyte traffic and graft-versus-host disease after fully allogeneic small bowel transplantation. *Transplant Proc* 1991; 23:3246-3247.
  56. Murase N, Demetris AJ, Woo J, et al. Graft versus host disease (GVHD) after BN to LEW compared to LEW to BN rat intestinal transplantation under FK 506. *Transplantation* 1993; 55:1-7.
  57. Tanabe M, Murase N, Demetris AJ, et al. The influence of donor and recipient strains in isolated small bowel transplantation in rats. *Transplant Proc* 1994; 26:3733-3740.
  58. Starzl TE, Demetris AJ. Transplantation milestones: viewed with one- and two-way paradigms of tolerance. *JAMA* 1995; 273:876-879.
  59. Williams JW, McClellan T, Peters TG, et al. Effect of pretransplant graft irradiation on canine intestinal transplantation. *Surg Gynecol Obstet* 1988; 167:197-204.
  60. Deltz E, Ulrich K, Schach T, et al. Graft-versus-host reaction in small bowel transplantation and possibilities for its circumvention. *Am J Surg* 1986; 151:379-386.
  61. Lee KKW, Schraut WH. *In vitro* allograft irradiation prevents graft versus host disease in small bowel transplantation. *J Surg Res* 1985; 38:364-372.
  62. Shaffer D, Maki T, DeMichele SJ, et al. Studies in small bowel transplantation: prevention of graft-versus-host disease with preservation of allograft function by donor pretreatment with antilymphocyte serum. *Transplantation* 1988; 45:262-269.
  63. Shaffer D, Ubhl CS, Simpson MA, et al. Prevention of graft vs. host disease following small bowel transplantation with polyclonal and monoclonal antilymphocyte serum: effect of timing and route of administration. *Transplantation* 1991; 52:948-952.
  64. Williams JW, Sankary HN, Foster PF, et al. Splanchnic transplantation: an approach to the infant dependent on parenteral nutrition who develops irreversible liver disease. *JAMA* 1989; 261:1458-1462.
  65. Jaffe R, Trager JDK, Zeevi A, et al. Multivisceral intestinal transplantation: surgical pathology. *Pediatr Pathol* 1989; 9:633-654.
  66. Penn I, Hammond W, Brettschneider L, Starzl TE. Malignant lymphomas in transplantation patients. *Transplant Proc* 1969; 1: 106-112.
  67. Starzl TE, Penn I, Putnam CW, et al. Iatrogenic alterations of immunologic surveillance in man and their influence on malignancy. *Transplant Rev* 1971; 7:112-145.
  68. Starzl TE, Nalesnik MA, Porter KA, et al. Reversibility of lymphomas and lymphoproliferative lesions developing under cyclosporin-steroid therapy. *Lancet* 1984; 1:583-587.
  69. Calne RY, Rolles K, White DJG, et al. Cyclosporin A initially as the only immunosuppressants in 34 recipients of cadaveric organs: 32 kidneys, 2 pancreases, and 2 livers. *Lancet* 1979; 2:1033-1036.
  70. Reyes J, Tzakis AG, Bonet H, et al. Lymphoproliferative disease after intestinal transplantation under primary FK506 immunosuppression. *Transplant Proc* 1994; 26:1426-1427.
  71. Klein G. Epstein-Barr virus strategy in normal and neoplastic B cells. *Cell* 1994; 77:791-793.
  72. Starzl TE, Todo S, Tzakis A, et al. Abdominal organ cluster transplantation for the treatment of upper abdominal malignancies. *Ann Surg* 1989; 210:374-386.
  73. Papadopoulos EB, Ladanyi M, Emanuel D, et al. Infusions of donor leukocytes to treat Epstein-Barr virus-associated lymphoproliferative disorders after allogeneic bone marrow transplantation. *N Engl J Med* 1994; 330:1185-1191.

## Discussion

DR. RONALD W. BUSUTTL (Los Angeles, California): I would like to congratulate Dr. Starzl on his presentation and

thank him for providing me with the manuscript. This paper is truly a "must" read for all of you who have any interest in transplantation. The material described is detailed, it is forthright, and it is very timely.

But as I see it, the real value of this paper lies in the fact that it is truly the only series of human intestinal grafts that have been studied and scrutinized so closely. Some of us in this room have a handful of cases each, but none of us have the extensive experience of Dr. Starzl's group, which allows them to advance this discipline in truly a scholarly manner.

The Pittsburgh group has systematically developed not only the techniques and protocols for experimental and clinical intestinal transplantation, but has also provided us with the science to support its cautious application to the clinical setting. A few examples of such advances include:

1. A description and a refinement to both the donor and recipient operations for intestinal transplantation, with a view of the indications on whether to use the intestine alone, the liver plus the intestine, or a multivisceral graft.
2. Conducting seminal experiments on the use of F-K 506 in immunosuppression for this group of patients.
3. Showing depletion of the immunocytes in the intestinal graft is not necessary and indeed may be deleterious to graft function.

In this paper are the important observations that retention of the ileocecal valve and colon to decrease the intractable diarrhea after small bowel transplantation is counterproductive and that cytomegalovirus (CMV) disease, particularly when it is primary, is disastrous for graft survival.

Finally, the finding of a 19% incidence of B-cell lymphoma with a 67% mortality is ominous.

These findings are extremely important. However, they leave many unanswered questions.

First, why is CMV prophylaxis ineffective in intestinal transplantation while it is extremely effective in liver allografts? In our own series at UCLA, we have eradicated CMV disease by giving intravenous ganciclovir for 100 days post-transplant, even in the sinister combination of CMV-positive donors and CMV-negative recipients. Is it the increased immunosuppression used in intestinal grafting or are other factors involved?

Second, is it possible that CMV alters the lymphocyte trafficking that is seen after intestinal transplantation and thus through this mechanism makes the grafts more susceptible to rejection? Is the problem with the retention of the colon a mechanical one? Is it bacterial overgrowth? Is it rejection? Or is it the site where CMV becomes manifested? You suggested that increased levels of tumor necrosis factor-alpha and its relationship to increased endotoxin may be the cause for this problem in these patients. If this is the case, have you considered using anti-tumor necrosis factor antibody in these patients?

The incidence of B-cell lymphoma is a real problem. What strategies are you currently using for prevention of treatment? It seems improbable to completely avoid OKT-3 usage in this group of patients.

You have used bone marrow transplantation to augment four of these patients in your more recent series, what do you think the role of this added procedure is in intestinal transplantation?

Finally, I would like to echo what Dr. Starzl said, that although the results of intestinal transplantation are not very encouraging at the present time, they are where we were about 15 years ago with liver allografting.

I think it is extremely encouraging that 27 of the 28 patients who retain their original grafts are not dependent on intravenous nutritional support. I think this is truly an outstanding result and I congratulate the authors on this very fine piece of work.

**DR. ALAN LANGANAS** (Omaha, Nebraska): At the University of Nebraska, we have performed 21 intestinal transplants to date. Without the seminal work by the University of Pittsburgh, these efforts would have not been possible.

My questions primarily relate to those that were alluded to by Dr. Busuttil, and in particular, viral infections.

We have observed similar events that you have seen with Epstein-Barr virus and cytomegalovirus (CMV)-related infections. What is not clear to me is why the CMV and Epstein-Barr virus not only are more virulent but appear to be more pernicious after intestinal transplantation. I would be interested in hearing why you think this organ is different than many others used in transplantation. As we all know, for liver transplant recipients, if you have a CMV-positive donor organ placed into CMV-negative recipient, you will see an 80% incidence of CMV-related disease, but this is an unusual and infrequent cause of graft loss or death.

My second question relates to the use of the bone marrow. As you have written about many times, after a liver transplantation recipient passes through the initial turmoil of the first few weeks or months after transplantation, often they enter a quiescent phase in which there appears to be a greater graft acceptance. You have proposed that cell trafficking of lymphoid lineage passes from the liver and settles into distant sites in the recipient. In intestinal transplantation, despite the huge lymphoid mass of the organ itself, we do not really see this "accommodation" of the transplanted organ. Why does this not occur, and why is donor bone marrow required?

**DR. FRANCIS D. MOORE** (Boston, Massachusetts): I, also, would like to congratulate Tom Starzl on behalf of all of us for his remarkable leadership in this difficult field. And I would like to go to a very detailed question.

He gave some bone marrow cells. I assume those were from the same donor. He did not state that clearly, but I assume they were. Did those patients have any different incidence of the B-cell lymphoma? Because that is a most remarkable finding in this series of cases.

**DR. S. TODO** (Closing Discussion): Thank you very much, Dr. Busuttil, Dr. Langanas, and Dr. Moore. I would like to take the clinical questions. Dr. Starzl will answer questions about the bone marrow program and the lymphomas.

Two of the discussants asked why these patients have such a high incidence of infections. This is due partly to the high-level maintenance requirements for FK 506, the frequent need for OKT-3, and the repeated use of steroid boluses. For the liver patient, we keep the FK trough level of whole blood in the 10-

to 15-ng/mL range. To control rejection in the intestinal recipient, the level often has been kept twice as high. There may be other confounding factors with the viral infections which Dr. Starzl will discuss, to explain why the enterocyte is the main target of the cytomegalovirus (CMV) infections. We use the same treatment strategies for CMV prophylaxis, such as acyclovir and ganciclovir for 2 to 3 months after transplant, as for other kinds of organ recipients. Yet, patients who received the CMV-seropositive intestine-containing grafts seemed not to be equivalently treatable. Typically, their difficulties surfaced after three to four months.

Regarding the higher tumor necrosis level in the colon recipient, we may be able to use anti-tumor necrosis factor antibody to mitigate the harmful consequences, particularly those associated with the colon, as Dr. Busuttil showed several years ago in experimental transplant models.

**DR. THOMAS E. STARZL** (Closing Discussion): Dr. Todo is such a fine scientist that he does not like to speculate and is inclined to leave that to his junior partner.

First, one could speculate about the unusual penetrance of cytomegalovirus (CMV). This is a lymphotropic virus. It is hard to think of a more spectacular way to disseminate a CMV infection than by the ubiquitous migration of the cells that carry the virus. Relevant to Dr. Moore's comment, the dominant cell population migrating from the intestine is lymphocytic.

This is the reason why the large number of white cells migrating from the intestinal graft fails to induce the kind of rapid graft acceptance that Dr. Langanas has pointed out is common after liver transplantation. This has been demonstrated in recent rat study (Murase et al. Transplantation 1995; 60:158-171). Among the parenchymal and secondary lymphoid organs, the liver and bone marrow were the most tolerogenic and least likely to cause graft-versus-host disease. The migratory leukocytes from these two sources had a heavy representation of cells of myeloid lineage with a much smaller lymphocyte component—in contrast to the lymphocyte-rich intestine.

The B-cell lymphoma problem also can be considered in the lymphocyte context. I would like to suggest a treatment approach for these intestinal patients which is speculative, but which has worked in a mirror image version for bone marrow recipients suffering this complication. In essence, the hyperproliferating cells are B lymphocytes in which the Epstein-Barr virus is contained. Most of us carry this oncogenic virus in our B cells, but as George Klein of Stockholm has demonstrated, the quiescent virus is nonantigenic. When the virus replicates—coincident with hyperproliferation of the B lymphocytes—six or perhaps as many as eight variants of the virus are expressed. All are antigenic except the original one that has been sustaining the virus in the latent state. With replication, competent cytotoxic T cells pounce on the antigenic virus and coincidentally destroy the B cells in which they reside. That is why we do not all have B-cell lymphomas.

How to exploit that information has been clear in whole organ recipients. All that is necessary is to reduce or stop immunosuppression allowing recovery of the host cytotoxic T lymphocytes which then carry out their normal B-lymphocyte surveillance. The consequence is that the tumors melt away. In

whole organ recipients, these tumors are essentially always of host origin.

In contrast, the B-cell lymphomas after conventional bone marrow transplantation (after recipient cytoablation) rise from donor, not recipient cells. The strategy of reducing immunosuppression is not feasible. However, a spectacular regression of the donor-type lymphomas has been reported in bone marrow recipients after infusion of fresh cytotoxic T lymphocytes obtained from the original donor (Papadopoulos et al. *New Eng J Med* 1994; 330:1185-1191). The principal risk is graft-versus-host disease.

An analogous approach should be feasible in the high-risk

intestinal recipient whose immunologic surveillance fails to recover despite stopping immunosuppression. This will require the simple precaution of storing and preserving either recipient bone marrow or blood buffy coat preoperatively so that the cells can be infused later, in the event of B-cell lymphoma development. Here, the principal risk will be rejection. In his analysis of a paper that I gave to this organization in 1989, Francis Moore pointed out that if we understood the pathogenesis of the post-transplant lymphomas in intestinal recipients, we would be able to rationally treat them. I believe that my suggestion will prove the wisdom of Dr. Moore's prophecy.