

**MANDIBULAR SHAPE IN MYOSTATIN-DEFICIENT MICE: A GEOMETRIC
MORPHOMETRIC ANALYSIS**

by

Fayth Johnston, DMD

B.S., Lehigh University, 2004

D.M.D., Temple University School of Dentistry, 2009

Submitted to the Graduate Faculty of
the School of Dental Medicine in partial fulfillment
of the requirements for the degree of Master of Dental Science

University of Pittsburgh

2012

UNIVERSITY OF PITTSBURGH
SCHOOL OF DENTAL MEDICINE

This thesis was presented

by

Fayth S. Johnston D.M.D.

It was defended on

May 3, 2012

and approved by

Seth M. Weinberg, PhD, Assistant Professor, Department of Oral Biology

Mark P. Mooney, PhD, Professor/Chair, Department of Oral Biology

Katherine Neiswanger, PhD, Research Associate Professor, Department of Oral Biology

Thesis Director: Seth M. Weinberg, PhD, Assistant Professor, Department of Oral Biology

Copyright © by Fayth S. Johnston

2012

**MANDIBULAR SHAPE IN MYOSTATIN-DEFICIENT MICE: A
GEOMETRIC MORPHOMETRIC ANALYSIS**

Fayth S. Johnston, MDS

University of Pittsburgh, 2012

The relationship between muscle function and mandibular morphology is unclear. Manipulating the size or function of muscle and then observing the effect on adjacent bone is one way to explore this relationship. The premise is that muscles under function create stress and strain on bone, thereby altering bone morphology. Myostatin knockout (MKO) mice are hypermuscular and may be used as an animal model to study this muscle-bone association. Previous studies comparing MKO mice have used conventional cephalometric analyses to compare their skeletal morphology to wild-type controls. The objective of our study is to provide a phenotypic description of the mandible in MKO mice compared to wild-type CD-1 control mice by quantifying their shape variation at 28 days of age utilizing a geometric morphometric approach. The hypothesis proposes that epigenetic muscle-bone interactions during development cause mandibular shape changes in MKO mice compared to the wild-type controls by 28 days of age. The present sample included nine wild-type and eight MKO mice 28 days old. Eleven mandibular landmarks were recorded on each cephalogram. The landmarks were aligned using Procrustes superimposition method and new coordinates were created to perform a canonical variates analysis (CVA). Results found a significant difference in the mean mandibular shape between the MKO and wild-type groups (Procrustes statistic: 0.047; $p = 0.014$). The inferior border of the mandible of the myostatin-deficient mice showed increased curvature and decreased ramal height when compared to the wild-type mice. The curved mandible phenotype

here may be analogous to the 'rocker' mandible reported to be prominent in the Polynesian population. These findings suggest that changing muscular forces altered mandibular morphology most dramatically in regions associated with masticatory muscle attachments.

TABLE OF CONTENTS

1.0	INTRODUCTION.....	1
2.0	BACKGROUND AND LITERATURE REVIEW	4
2.1	MUSCLE, BONE AND THE FUNCTIONAL MATRIX	4
2.2	MASTICATORY MUSCLE FUNCTION AND MANDIBULAR FORM.....	7
2.3	EFFECT OF MYOSTATIN (GDF-8) MUTATIONS ON CRANIAL AND MANDIBULAR FORM	12
2.4	AN ALTERNATIVE APPROACH TO QUANTIFYING BIOLOGICAL SHAPE.....	17
3.0	MATERIALS AND METHODS	20
3.1	SAMPLE.....	20
3.2	DATA ACQUISITION.....	21
3.3	STATISTICAL METHODS.....	22
4.0	RESULTS	25
5.0	DISCUSSION	27
6.0	CONCLUSIONS	34
	APPENDIX A	35
	APPENDIX B	36
	BIBLIOGRAPHY	40

LIST OF TABLES

Table 1: Sample	35
-----------------------	----

LIST OF FIGURES

Figure 1: Tracing Example	36
Figure 2: Shape Variables Following Procrustes Superimposition	37
Figure 3: Regression of Shape on Centroid Size	37
Figure 4: CVA Results After Removing Allometry	38
Figure 5: Wireframe Deformations: GDF-8 Mutant Mandible Compared to Consensus Shape..	38
Figure 6: Wireframe Deformations: Wild-Type Mandible Compared to Consensus Shape	39

1.0 INTRODUCTION

The concept that skeletal form is influenced by extrinsic mechanical forces has been known for over a century (reviewed by Murray, 1936). Skeletal muscles are a major source of mechanical loading on bones. In the early 1960's, based on a great deal of early experimental work in animal models, Moss developed the functional matrix hypothesis as a theoretical model to explain how muscles and other soft tissues affect skeletal form in the craniofacial complex (Moss and Salentijn, 1969). Capitalizing on the muscle-bone relationship, orthodontists often attempt to change an individual's pattern of craniofacial growth by altering muscle function (Wall, 2006).

Manipulating the size and/or function of muscle and then observing the effect on adjacent bone is one method for exploring the dynamic relationship between these tissues. For example, an increase in muscle mass can change patterns of mechanical stress on the corresponding bones, thereby altering bone morphology (Raadsheer et al., 1999, Pepicelli et al., 2005, Thongudomporn et al., 2009). In the craniofacial complex, changes in the size and shape of the mandible often occur as a consequence of primary changes in masticatory muscle function (Pepicelli et al., 2005). In the clinical orthodontic community, there is a great need to understand the mechanisms underlying growth of the facial skeleton and the factors that determine its form. To what degree can orthodontists alter craniofacial growth patterns? How important is muscle size and function and how should this factor into our treatment decisions? How well can

orthodontists predict how a patient's face will grow? Predicting whether a patient will be a favorable or unfavorable grower may determine what treatment will serve them best. Human skull morphology is multifactorial and hypermuscularity may be but one of the many factors involved (Menegaz et al., 2010, Vecchione et al., 2007). Perhaps more important to orthodontists than skull morphology is determining the effect that muscles have on the mandible. Several muscles of mastication insert on the mandible making it particularly susceptible to masticatory forces.

Myostatin knockout (GDF-8 myostatin-deficient) mice have been used as an animal model for studying craniofacial growth in relation to masticatory muscle mass and function. Myostatin is a negative regulator of skeletal muscle growth. Animals lacking myostatin have been found to have dramatically larger muscles (Walsh and Celeste, 2005, Vecchione et al., 2007, 2010, Welle et al., 2009, Cray et al., 2011, Kneib et al., 2011). Previous studies by Vecchione et al. (2007, 2010) have examined craniofacial morphology of myostatin-deficient mice using conventional cephalometric analysis. These studies have noted that adult myostatin knockout mice were more brachycephalic and had smaller cranial vaults and maxillary lengths than wild-type controls (Kneib et al., 2011, Vecchione et al., 2007) especially once they were weaned at 28 days (i.e., switched to a hard diet) (Vecchione et al., 2010). The mandibular shape of the knockout mice is different than the wild-type controls by 180 days and has been shown to be "rocker shape" (Vecchione et al., 2007). These studies have focused on the entire craniofacial complex; the present study will elaborate on mandibular morphology.

Traditional cephalometric analysis uses a limited set of linear distances, angles, areas of triangles, and ratios as parameters to quantify the form of craniofacial structures. As a tool for describing morphology, however, this type of approach is rife with limitations (McIntyre and

Mossey, 2003). Consequently, techniques other than conventional cephalometric analysis should be explored in an effort to more fully describe mandibular morphology in this mouse model and the role of the muscle-bone relationship in craniofacial growth.

The main objective of this study will be to provide a more comprehensive phenotypic description of the mandible in myostatin knockout mice compared to wild-type CD-1 control mice by quantifying their shape variation at 28 days of age. Geometric morphometrics will be used to analyze shape.

2.0 BACKGROUND AND LITERATURE REVIEW

2.1 MUSCLE, BONE AND THE FUNCTIONAL MATRIX

The role of muscles in the growth and development of skeletal form is very complex. Final skeletal morphology results from numerous factors working in concert, including genetic, epigenetic and extrinsic environmental factors (Beecher and Corruccini, 1981, van Limborgh, 1982, Renaud et al., 2010). Intrinsic genetic factors operating inside of the cells have a local influence, and are the result of the DNA sequence. The growth of skeletal elements (e.g., the mandible) is determined not by a single gene, but rather by complex patterns of genes controlling development (Cheverud et al., 1997, Klingenberg et al., 2001, Oshikawa et al., 2004). Epigenetic factors create a non-genetic change which alters the phenotype but not the DNA sequence of an organism (Renaud et al., 2010). An example of an epigenetic factor is hormones which are produced in one region of the body and have an effect at a distant site. In a study by Vogl et al. (1993), the impact of growth hormone on skeletal development was studied in mice. They found that growth hormone influenced the length of long bones and in the mandible had the largest effect on areas of muscle attachment. The bone of the mandible is plastic and can be remodeled during postnatal growth by its interaction with muscles (Renaud et al., 2010). Environmental factors may also be general or local. General environmental factors include food and oxygen; local environmental factors include muscle function, which produces strain patterns

in associated bones. In fields such as orthodontics, the goal is to modify local environmental factors to alter the pattern of skeletogenesis for therapeutic effect. This fact highlights the importance of understanding the role that muscles, a local environmental factor, play in shaping the final morphology of bone.

In general, mechanical stimulation created by the functioning muscles on bone is anabolic or osteo-inductive (Judex et al., 2009). Conversely, in animals with severe muscle mass reduction or complete loss of muscle attachment, the required strain threshold may not be reached and bone atrophy may occur (Beecher and Corruccini, 1981). This is considered disuse-induced bone loss (Menegaz et al., 2010, Poliachik et al., 2010). During very early development, a lack of proper muscle function can even result in craniofacial deformity (Schmitt et al., 2010). As early as 6 to 8 weeks in embryonic development, facial muscles can be observed contracting (Hall, 2010). Lack of muscle functioning has been linked to ocular hypertelorism, flat zygoma and midface, high bridge of nose, depressed tip of nose, small and open mouth, trismus, microretrognathia, small tongue, and abnormal palate (Hall, 2010). Functional loading is complex and its effect on bone is dependent on many factors such as: strain type, normal or shear; strain magnitude, dynamic or static; and the number of loading cycles, or strain frequency (Judex et al., 2009). The biological response of bone to mechanical stimuli may also be influenced by genetics, gender, and baseline morphology (Judex et al., 2009). A more recent study looked at the effect of transient muscle paralysis on adjacent bone in mice (Poliachik et al., 2010). The experiment isolated one muscle group in the hindlimb of mice and found significant cortical and trabecular bone loss within 3 weeks of muscle paralysis. The author concluded “these data confirm the essential role that normal muscle function plays in the homeostasis of an

adjacent bone” (Poliachik et al., 2010). Also, trabecular bone was found to be more resilient than cortical bone to the loss of muscle function.

Throughout the history of the study of growth and development, various hypotheses have been put forth to understand the factors governing the development of skeletal morphology. Classically, it was thought that purely genetics alone determined skeletal growth and morphology (Carlson, 1999). Based on this theory, craniofacial growth and form were considered immutable. Orthodontists who believed this concept were only able to reposition the teeth within the patient’s genetically predetermined jaws. With advances in developmental biology it has become clear that genes are not the only factor determining craniofacial growth (Carlson, 1999). Theories involving bone, cartilage, and soft tissues as the primary determinants of growth have been suggested (Carlson, 1999; Moss and Rankow, 1968; Profitt et al., 2007). It is clear through various experiments that neither bone nor cartilage are the primary factors of growth but rather act as secondary sites (Carlson, 1999; Profitt et al., 2007). In the 1960’s Melvin Moss proposed the *functional matrix hypothesis* based on previous work by van der Klaauw (Carlson, 1999). According to Moss’ paradigm, soft tissues were the primary determinant of craniofacial growth (Moss and Rankow, 1968). Moss divided the head into functions (e.g. digestion) with each function being carried out by a single *functional cranial component*. Each functional cranial component consists of both a *functional matrix* and a *skeletal unit*. The functional matrix (e.g. muscles) actually carry out the function of the component; while, the skeletal unit’s duty is to protect and support its specific functional matrix (Moss and Rankow, 1968). After experimentation Moss stated that “...the functional matrix is *primary* and that the presence, size, shape, spatial position and growth of any skeletal unit is *secondary*, compensatory and mechanically obligatory to changes in size, shape, spatial position

of its related functional matrix” (Moss and Rankow, 1968). Based on this concept, bone merely responds to changes in soft tissues. This emphasis on the plasticity of bone led to the possibility of using growth modification in orthodontics to correct facial deformity (Carlson, 1999).

2.2 MASTICATORY MUSCLE FUNCTION AND MANDIBULAR FORM

Numerous studies have altered masticatory forces in various ways to test their effect on craniofacial form. One common approach is to manipulate the type of diet for a set of animals and observe changes in skeletal morphology. The influence of a hard or soft diet alters the size and function of the masticatory muscle apparatus resulting in altered skeletal loading patterns, which ultimately affects craniofacial form (Beecher and Corruccini, 1981, Menegaz et al., 2010, Ravosa et al., 2007, Renaud et al., 2010). These effects are not limited to the jaws and often extend to distal areas of the cranial vault. A recent study looking at rabbits with a hard diet, and therefore exhibiting increased masticatory stresses, reported deeper pterygoid plates, shorter basisphenoid, greater face size relative to basicranial length, and increased thickening of the cranial vault compared to the soft-diet group (Menegaz et al., 2010). In another study comparing hard and soft diet rats, the maxillary length and width, mandibular length, condyle length, body weight, and masseter weight appeared to be larger in the hard diet rat population (Beecher and Corruccini, 1981). In general, rats raised on a hard diet have greater condylar and craniofacial dimensions and increased temporomandibular joint cartilage thickness (Beecher and Corruccini, 1981, Ravosa et al., 2007). The changes illustrated above emphasize the plasticity of the craniofacial complex during postnatal development in response to altered masticatory strain patterns.

Another way to investigate the model that supports muscle involvement in craniofacial form is to examine the relationship among muscle forces during biting, the resultant stresses on bone, and the ultimate changes in skeletal morphology that follow. For example, increased muscle mass, based on cross-sectional area or thickness, has been shown in studies to alter bone morphology (Raadsheer et al., 1999; Pepicelli et al., 2005; Thongudomporn et al., 2009). Larger muscle mass exerts an increased bite force magnitude on the bone. An interaction exists among bite force magnitude, jaw muscle size, and craniofacial morphology (Raadsheer et al., 1999). An experimental study by Thongudomporn et al. (2009) using human subjects investigated the effect of maximum bite force on alveolar bone morphology parameters. The results found that maximum bite force influenced alveolar bone thickness and shape, but not arch width. These findings imply that masticatory function plays a role in determining alveolar bone morphology. Despite a positive association, alveolar bone thickness and shape were only found to contribute to 10-20% of the morphologic variation in bone (Thongudomporn et al., 2009). Raadsheer et al. (1999) in a study measuring human bite force, concluded that 58% of the variance in bite force could be accounted for by variation in muscle size and craniofacial morphology. Both of these findings suggest that factors other than maximum bite force must also be contributing to alveolar bone morphology.

Humans with a strong bite force have been shown to present with brachycephalic facial types while those with a weaker bite force tend to display more dolichocephalic facial patterns (Humphrey et al., 1999, Pepicelli et al., 2005, Ueki et al., 2006, Zepa et al., 2009). This pattern is not seen in children and only appears in adulthood (Humphrey et al., 1999). According to Proffit and Fields (1983), something must happen after the age of 10 and before growth is completed that does not allow the mandibular elevator muscles of long-face children to increase

in strength. It is not clear whether jaw-muscle function determines growth or vice versa (Pepicelli et al., 2005). Weaker muscles have less of an effect on craniofacial morphology than do larger muscles, creating a greater variation among subjects with weaker muscles. The precise relationship between form and function is still unclear. A large amount of research has been focused on understanding the factors that influence the shape of the mandible. It is a morphologically complex structure, where initial form appears to be largely determined by genetic factors, followed by subsequent alteration via remodeling under mechanical load later in development (Beecher and Corruccini, 1981; Klingenberg et al., 2001; Menegaz et al., 2010). All of the major muscles of mastication insert on the mandible making masticatory forces in this region very important to final mandibular form (Cheverud et al., 1997). Studies have shown that even late in postnatal development the mandible is remodeled through interactions with muscles and shows high plasticity (Renaud et al., 2010).

According to Moss' *functional matrix theory* previously described, the mandible can be divided into 6 microskeletal units: basal, condyloid, coronoid, angular, alveolar, and symphyseal (Moore, 1973). Classical osteology viewed the mandible as a whole; while, Moss suggested it is actually composed of several relatively independent units integrated in function (Moss, 1969). The results of a study by Moss and Simon (1968), show that the angular process, a skeletal unit, changes shape with age as a result of changes in the orientation of its functional matrix, the masseter and the medial pterygoid muscles. As the masseter moves from a vertical line of action to a more oblique orientation, the angular process flares laterally. The postnatal development of the angular process is dependent on the presence of the masseter and internal medial pterygoid muscles (Avis, 1961). Removal of the angular cartilage in rats has been shown to result only in the absence of the angular process, while growth of all other mandibular skeletal units is normal,

illustrating the relative independence of skeletal units (Moss, 1969). Many other studies have been performed that come to the same conclusion: if a mandibular functional matrix is altered, there will be changes to its corresponding skeletal unit (Avis 1959, Avis 1961, Horowitz and Shapiro 1951, Horowitz and Shapiro 1955, Moss 1969, Riesenfeld 1969).

Various animal and human studies have been done using different techniques to investigate the relationship between masticatory muscles and mandibular shape. In a study by Nanda et al. (1967), the masseter muscle was unilaterally repositioned more anteriorly in dogs. The authors found that the masseter muscle on the experimental side was smaller and positioned more vertically than on the control side; however, the skeletal changes were limited and less than anticipated. The authors concluded that although muscle function is important in determining the size and shape of facial form, there are other factors that must be involved as well. In a more extreme example of altered muscle position, the effect of muscle resection was studied in an experiment by Yonemitsu et al. (2007). The masseter muscles were resected bilaterally in rats to determine the effect of masticatory force on the mandible and condylar shape. The authors found that various regions of the mandible experienced decreased bone formation as a result of masseter resection. Of the masticatory muscles, the masseter is one of the most important elevator muscles contributing to bite force magnitude (Eckhardt et al., 1997). Unilateral resection of the masseter muscle in rats causes asymmetrical mandibular growth and malocclusion (Pratt, 1943). These data suggest that masseter function is important in rat mandibular growth.

A more current study by Renaud et al. (2010) compared the epigenetic effect of two different methods for inducing plastic shape variation in mice mandibles. The authors compared two sources of mandibular remodeling: muscular dystrophy and food consistency. Bone

remodeling is an important determinant of bone morphology but depending on the source, the pattern of remodeling may vary (Renaud et al., 2010). The pattern of remodeling is dependent on masticatory function postnatally. Results showed that mice with muscular dystrophy, which affects all muscles, causes shape changes generalized over the entire mandible; while mice with altered food consistency show more localized changes to the molar region and area of masseter insertion. Thus, certain regions of the mandible may be more prone to remodeling than others.

Many studies have measured patterns of muscular activity to investigate the relationship between malocclusion and muscles (Moss and Chalmers, 1974). A study by da Silva and Cechinho (2009) studied the effect of locally applying an anabolic steroid to the masseter muscle of growing rats. The authors found a strong relationship between neuromuscular activity and skeletal morphogenesis. Results showed that the Frankfurt mandibular plane angle (FMA) decreased as did the gonial angle which were both most likely an indirect effect created by the increased functional force of the larger muscles (de Silva and Cechinho, 2009). A certain subset of these studies use electromyography (EMG) to measure the masticatory muscle activity in subjects with malocclusion. Despite advances in measuring muscle activity, there is still controversy over the association between masticatory muscle activity and skeletal form (Kitai et al., 2002). One particular study found that the resting surface electromyography (sEMG) activities of the masseter and anterior temporal muscles were increased in Class III subjects compared to normal and Class II subjects (Tecco et al., 2007); while, another study noted that resting EMG levels in Class III subjects were lower than in Class II subjects (Sabashi et al., 2009). The precise relationship between antero-posterior mandibular position and masticatory muscle activity is mixed in the literature; however, most studies do agree that subjects with Class III malocclusion have an abnormal masticatory muscle balance compared to normal subjects

(Deguchi *et al.*, 1995, Moss and Chalmers, 1974, Zepa *et al.*, 2009). In patients with mandibular prognathism, the morphology of the masseter and temporal muscles and distribution of masticatory forces differ from that found in normal subjects (Eckhardt *et al.*, 1997, Kitai *et al.*, 2002, Ueki *et al.*, 2006, Yamaoka *et al.*, 2001). If patients with Class III skeletal malocclusion innately have different masticatory muscle patterns when compared to normal patients, then the ability of such muscles to adapt after either orthognathic surgery or traditional orthodontics may be critical to achieving a successful treatment outcome and long-term stability (Kitai *et al.*, 2002, Zepa *et al.*, 2009). A study by Eckhardt *et al.* (1997) noted that after completion of orthognathic surgery for Class II correction, the masseter activity approximated that of Class I subjects. In contrast, Class III subjects' post-orthognathic surgery masseter activity levels did not approach a normal pattern. This lack of muscle adaptivity after surgery in Class III patients may be an important source of relapse.

2.3 EFFECT OF MYOSTATIN (GDF-8) MUTATIONS ON CRANIAL AND MANDIBULAR FORM

The studies previously mentioned provide evidence that muscles have a growth modifying potential on bone. In addition to experimental studies involving manipulation of masticatory muscle function directly by the investigator, transgenic knockout mice exhibiting hypermuscularity can be used to model the effects of excessive loading on the craniofacial complex. Growth and differentiation factor 8 (GDF-8^{-/-}) or myostatin-deficient mice exhibit a doubling of muscle mass (Elkasrawy and Hamrick, 2010, Ravosa *et al.*, 2007). Myostatin is a negative regulator of skeletal muscle growth and is a member of the transforming growth factor-

beta (TGF- β) signaling family (Vecchione *et al.*, 2007). Certain phenotypic characteristics have been associated with the loss of myostatin in mice. For example, decreased myostatin has been shown to result in increased skeletal muscle mass and bone rigidity. The increased size of skeletal muscle results from both cell hyperplasia and hypertrophy (Vecchione *et al.*, 2010). In addition, the diameters of some long bones in myostatin-deficient mice are widened in the transverse plane (Schmitt *et al.*, 2010). Myostatin-deficient mice have been used in recent studies to determine the relationship between craniofacial morphology, hypermuscularity, and increased bite force (Ravosa *et al.*, 2007, Elkasrawy and Hamrick, 2010). The exact mechanism by which myostatin alters the size and shape of bone is unclear. Some uncertainty remains about whether the strength of masticatory muscles determines craniofacial morphology, or vice versa (Pepicelli *et al.*, 2005). In the example of myostatin knockout mice, this may cause an increase in muscle mass thereby influencing bone indirectly through functional loading. Others have suggested a more direct effect of the absence of myostatin on bone osteogenesis (Elkasrawy and Hamrick, 2010). Although the exact mechanism is still elusive, it is clear that changes to craniofacial muscles will create alterations to the size and shape of bone.

Mice are often the animal model of choice in experimental studies; however, myostatin is also considered an important regulator of muscle growth in humans (Welle *et al.*, 2009). In addition to the hypermuscularity seen in myostatin-deficient mice, similar phenotypic findings have been found in cattle (e.g., the breed Belgian Blue and Piedmontese) and in hypermuscular children with myostatin mutations (Walsh and Celeste, 2005). When choosing an animal model it is important to determine the type of information that is to be extrapolated from such a model. The data may be extrapolated to humans and the effect of muscles on their craniofacial morphology if an appropriate model is chosen. According to Siegel and Mooney (1990), there

are different levels of hypothesis testing which may be used to determine the appropriate animal model. According to the authors, phyletic affinity to humans is not always needed nor desired in an experimental study. In the case of studying muscles and their effect on bone morphology a generic animal model is sufficient to provide a descriptive phenotype as long as there is no attempt to draw any additional conclusions beyond this level.

In mice, myostatin alters muscles which in turn play a role in skeletal morphology. More specifically, masticatory muscles have been shown to be important due to their influence on craniofacial morphology. As noted by Pepicelli et al. (2005) muscles in the maxilla and mandible are important in the etiology and treatment of malocclusions and jaw deformities, and also for the stability of treatment. Considering the importance of musculature on craniofacial morphology, studies describing the craniofacial phenotype of myostatin-deficient mice are warranted.

Focusing on the craniofacial phenotype, Vecchione et al. (2007) compared male CD-1 myostatin knockout mice to wild-type controls at 6 months of age. Lateral and dorso-ventral radiographs were taken for both groups of mice. The authors found that the myostatin knockout mice by 6 months of age already presented with altered craniofacial morphology compared to the controls. Significant differences between the wild-type and myostatin knockout mice were found for cranial vault length, maxillary length, mandibular body length, and mandibular shape index. In general, the myostatin knockout mice were larger than the wild-type mice by 6 months of age. The myostatin-deficient mice had significantly greater body weight and masseter muscle mass as well. They were found to be more brachycephalic and showed remodeling of the jaw creating a “rocker-shaped” mandible. This was similar to the ‘rocker’ mandible found in Hawaiian skulls (Schendel et al., 1980). “Rocker-shaped” mandibles are characterized by a

convex inferior border of the ramus, decreased gonial angle, absence of an antegonial notch, and no defined angular notch (Houghton, 1978). This alteration to bone morphology may be the result of increased muscularity found in the Polynesian population.

Along with the findings of a more brachycephalic facial form, the myostatin-deficient mice exhibited longer mandibles and a smaller mandibular height-to-length measurement. A positive association was noted between masseter muscle weight and craniofacial shape. This data was interpreted as a difference in bite force, resulting from increased masseter muscle mass, causing altered stress patterns on the mandible which lead to changes in craniofacial morphology. Conventional cephalometric analyses were performed to interpret the landmarks on the lateral and dorso-ventral radiographs. The results of this study are similar to those reported by Elkasrawy and Hamrick (2010) who found that myostatin-deficient mice were more brachycephalic and had an increased mandibular body length. In addition to those findings, they also reported an increase in symphysis bone mineral density, masseter and temporalis attachment sites, condyle and condylar head bone mineral density, buccal articular cartilage thickness, and a decrease in buccal condylar convexity. There also appears to be increased bone density between normal and myostatin-deficient mice along with different patterns of plasticity between the mandibular corpus and symphysis (Ravosa et al., 2007). This data suggests the presence of a distinct morphologic phenotype in myostatin-deficient mice.

After determining that mice which are myostatin-deficient are phenotypically different than the control mice by 6 months of age, the authors studied different age groups to establish whether these differences were present at birth or acquired with age. Vecchione et al. (2010) in a follow-up study compared the craniofacial morphology of mice at 1 day of age to those at 180 days of age. Myostatin-deficient mice at 1 day of age were noted to be significantly different in

several important factors when compared to 180 day old mice and their respective controls. The myostatin-deficient mice at 1 day of age were significantly smaller in size than the control mice. However, by 180 days of age they were showing significantly larger muscle mass and body size compared to controls.

To find the age at which myostatin-deficient mice begin having a larger body size than their matched controls, Mooney et al. (2010) assessed mice at 1, 28 (weaning), 56 and 180 days of age. The results showed that by 28 days of age the myostatin-deficient mice were already different than the 1-day-old mice. The myostatin-deficient mice were slightly smaller skeletally than age-matched controls at 1 day of age. However, by 28 days, the myostatin-deficient mice had significantly larger body and masseter muscle weight, greater cranial vault length and height, and an altered mandibular shape index. The differences became more pronounced in the 56- and 180-day-old mice, respectively. In general, myostatin-deficient mice had a longer mandibular body length, larger body and masseter muscle weight, and shorter craniofacial length. Qualitatively, it was shown that the myostatin-deficient mice were more brachycephalic with remodeled mandibular rami and a “rocker-shaped” mandible by 180 days of age (Vecchione et al., 2010). The previous studies by Vecchione et al. (2007, 2010) traced only four landmarks on the mandible and measured body length and mandibular shape index. Although these studies provided some insight into mandibular morphology, further research is needed to provide a more complete description of the differences between the myostatin-deficient and the control mice. Using approaches other than traditional linear measurements to extract shape information will provide quantitative results as opposed to mere qualitative observations. While the previous studies have suggested morphological differences between the mandibles of myostatin-deficient

mice and their respective controls, additional research in this area will provide us with the ability to measure the precise relationship.

2.4 AN ALTERNATIVE APPROACH TO QUANTIFYING BIOLOGICAL SHAPE

The most traditional method for orthodontists to measure skeletal size and shape is with the use of a lateral cephalogram. In the clinical context, the two main reasons for analysis of lateral cephalograms are to provide descriptive and predictive information about patients (Baumrind and Frantz, 1971). Despite its everyday use in clinical orthodontics, there are inherent limitations when basic cephalometric analyses are used to capture salient aspects of morphological variation. Traditionally, cephalometric analysis is performed using traced landmarks on the radiograph by measuring linear distances, angles, areas of triangles, and ratios (McIntyre and Mossey, 2003). However, there are limitations to the kinds of biologically relevant information which can be drawn from such parameters. Namely, only the most rudimentary information about shape is captured. In modern morphometrics, the term shape includes "...all features of landmark configurations except for overall size, position, and orientation" (Klingenberg, 2002). By using this definition, it is clear that the conventional cephalometric approach provides limited information about craniofacial shape. According to McIntyre and Mossey (2003), conventional cephalometric analysis is not very effective at describing irregular structures, like those that comprise the craniofacial complex.

As a consequence of the limitations to conventional cephalometric analysis it is prudent to evaluate other options for evaluation of craniofacial morphology. One such leading option that has been widely used in the field of evolutionary and developmental biology is geometric

morphometrics. Geometric morphometric emerged in the 1980's, building on more traditional morphometric approaches used in the 1960's and 1970's (Adams et al., 2004). These methods rely on multivariate statistics for the quantitative analysis of shape. Multivariate statistics are essential when more than one variable is to be compared, because most likely the variables are not completely independent of each other and should not be treated as such (McIntyre and Mossey, 2003). Morphometrics allows scientists to quantify subtle differences in shape that may be present on a continuum and may not be apparent through other means of analyses (Klingenberg, 2010). Another advantage of geometric morphometrics is that one can represent shape variation, since the geometric information encoded in landmark data is preserved throughout the analysis (Adams et al., 2004).

Similar to conventional cephalometric analysis, landmarks or outline methods are required in techniques applying geometric morphometric analyses. However, geometric morphometrics attempts to extract the shape information from the data by adjusting for orientation, rotation, and size differences by using the Procrustes superimposition method (Klingenberg, 2010). According to this method described by Klingenberg (2010), the traced forms are taken from their original configuration coordinates, scaled to the same size and re-oriented to a common but arbitrary coordinate system where they are translated and rotated to an optimal fit. Once the new landmark coordinate data are generated, a multivariate analysis is performed on the data to either examine within-group shape variation or describe the shape differences across multiple groups.

Previous studies have used conventional cephalometric analysis to compare the craniofacial morphology of myostatin-deficient mice to wild-type controls. However, there are limitations to the data provided by such analyses. Further studies extracting shape information,

such as geometric morphometrics, are needed to provide a more complete phenotypic description of mandibular morphology in myostatin-deficient mice.

3.0 MATERIALS AND METHODS

3.1 SAMPLE

The study sample was comprised of nine wild-type (four males and five females) and eight GDF-8^{-/-} myostatin-deficient mice (eight males and zero females). A preliminary review revealed that sexual dimorphism was not a factor in the mice and both sexes could be grouped together. It is common practice to group both male and female mice in the same group. All mice were on a CD-1 background. The myostatin-deficient mice were created by deletion of the C-terminal region of the myostatin gene in embryonic stem cells (McPherron *et al.*, 1997). These were the same sample of mice used by Mooney *et al.* (2010). The mice were housed together and given food (Harlan TekLad hard rodent chow) and water as needed. The knockout mice were housed, bred and killed at the Medical College of Georgia and subsequently sent to the University of Pittsburgh for imaging and analysis. The wild-type CD-1 mice were housed at the University of Pittsburgh. The mice were killed at 28 days of age by CO₂ overdose according to IACUC approved protocols.

Mouse skulls were disarticulated and weighed. Masseter muscles were then dissected and weighed wet to the nearest 0.001g on a Mettler vacuum balance. Heads were then fixed in 10% neutral buffered formalin for 24 hrs, and transferred to 70% ethanol for radiographic analysis. Lateral radiographs were taken using a Faxitron MX-20 (Faxitron X-Ray Corporation) at 35 kV

for 250 sec at 5 x magnification with X-OMAT V diagnostic film (Kodak) as described in the previous studies by Vecchione et al. (2007; 2010). The same radiographs will be used in this present study. Radiographs will be scanned at hi-resolution (600 dpi) on an AGFA DuoScan large-format flatbed scanner using AFGA FotoLook 3.2 software (Wilmington, MA, USA).

3.2 DATA ACQUISITION

Each scanned image was imported into Photoshop CS3 (Adobe, Inc) and adjusted for contrast and brightness. Although the geometric morphometric approach includes a registration step, each image was adjusted for orientation prior to landmark collection. This step was performed because we planned to collect points corresponding to the maximum curvature of structures, and the collection of such relational points can be affected by the native orientation of images. This pre-orientation step involved digitally superimposing a grid over the image of the mandible and then rotating the image until the occlusal plane was aligned to the horizontal axis. A set of 11 landmarks were collected by a single investigator (F.J.) on the lateral cephalometric radiographs using the TPSdig2 program (see Figure 1) and the resulting x,y coordinates saved. On the lateral cephalogram the following landmarks were collected: (1) the most prominent point between the incisal edges of the lower incisors; (2) superior-most point on incisor alveolar rim at midline (bone-tooth junction); (3) anterior edge of alveolar process where first molar hits alveolus at the midline; (4) intersection of molar alveolar rim and base of coronoid process; (5) apex of coronoid process; (6) the most posterosuperior point of the condylar process; (7) most concave subcondylar point; (8) tip of mandibular angle; (9) superior-most point on inferior border of mandibular ramus; (10) inferior-most point on the curvature of the body of the mandible; and

(11) inferior-most point on incisor alveolar rim at midline (bone-tooth junction) (Figure 1). All landmarks were captured twice from each scan and assessed for intra-observer reliability by calculating intraclass correlation coefficients (ICC). The resulting ICC values were above 0.80 for all landmarks in all dimensions; thus all 11 landmarks were included in the final analysis. The x,y coordinates associated with the landmarks were averaged across the two sessions and saved for analysis.

3.3 STATISTICAL METHODS

A geometric morphometric approach was used to assess mandibular shape variation. The 11 individual landmark coordinate configurations were first aligned to one-another using the Procrustes superimposition method (Figure 2). In this procedure, the original configurations are scaled to the same size, translated to the same location, and rotated to an optimal fit (Klingenberg, 2010). This procedure results in a new coordinate data set which contains information only relating to the traced object's shape. These shape coordinates are then typically projected (transformed) into a linear space, allowing them to be subjected to a variety of standard parametric statistics.

A canonical variates analysis (CVA) was performed on the shape coordinate variables. Conceptually similar to discriminant function analysis, CVA is a multivariate data reduction method designed to maximize the differences between two or more pre-existing groups in a given dataset (Zelditch *et al.*, 2004). In the present analysis, CVA was used to test whether mean mandibular shape is equivalent in wild-type and myostatin-deficient mice (i.e., are the two mean shapes different?); this is typically accomplished with an omnibus shape test. Furthermore, CVA

can identify which specific aspects of mandibular shape variation are most important for distinguishing between mouse groups (i.e., where are the salient shape differences located?). A hallmark of the geometric morphometric approach is the ability to visualize shape variation as positional shifts in the relative location of landmarks; this is possible because the variables in the analysis are landmark coordinates which have intrinsic geometric and spatial properties. As a result, with CVA one is able to visualize the magnitude and direction of shape differences across groups in a straightforward manner.

The CVA procedure was carried out in two ways: (1) with unadjusted shape variables and (2) with allometry-adjusted shape variables. Removing the effects of allometry (size related shape) can be important because allometric effects can sometimes obscure or confound the variation of interest. Allometry was removed by performing a regression of centroid size (used here as a general mandibular size measure) on the shape variables. The residuals from this analysis (allometry-free shape variables) were then subjected to a second CVA. The relationship between observed mandibular shape variation and masticatory muscle mass was assessed by computing the non-parametric correlation between each specimen's score from the CVA and their muscle weight. All shape analyses were performed in the program MorphoJ.

The CVA comparing shape between 28 day old GDF-8 mutant mice and wild-types yielded suggestive evidence of a group difference in mean mandibular shape (Procrustes statistic: 0.041; $p = 0.087$). Regression analysis of centroid size on shape revealed strong allometry effects, with 16.79% of the shape variation in the dataset accounted for by size ($p = 0.0058$). This regression plot is shown in Figure 3. CVA on the allometry-adjusted shape variables resulted in a significant difference in the mean mandible shape between the mutant and wild-type groups (Procrustes statistic: 0.047; $p = 0.014$). The clear group separation along the

main canonical axis of shape variation is shown in Figure 4 . A correlation between masseter muscle weight and shape was calculated to be -0.456, indicating that the shape of the GDF-8 mutant mice get more different from the wild-types as masseter muscle weight increases.

Mandibular wireframe deformations associated with the CVA (after adjusting for allometry) showed that the inferior border of the mandible of the myostatin-deficient mice had increased curvature and the height of the ramus was decreased when compared to the wild-type mice. These wireframes are shown in Figure 5 and Figure 6. The aforementioned increase in mandibular curvature was driven primarily by superior displacement of the gonial angle (ML 8) along with points associated with the anterior inferior body of the mandible (ML10 and ML11). The noted decrease in ramus height was driven principally by inferior displacement of points associated with the coronoid and condylar process (ML5 and ML6). Concomitant buccal tipping of the mandibular incisor (ML1) was also observed in the GDF-8 mutant group.

4.0 RESULTS

The CVA comparing shape between 28 day old GDF-8 mutant mice and wild-types yielded suggestive evidence of a group difference in mean mandibular shape (Procrustes statistic: 0.041; $p = 0.087$). Regression analysis of centroid size on shape revealed strong allometry effects, with 16.79% of the shape variation in the dataset accounted for by size ($p = 0.0058$). This regression plot is shown in Figure 3. CVA on the allometry-adjusted shape variables resulted in a significant difference in the mean mandible shape between the mutant and wild-type groups (Procrustes statistic: 0.047; $p = 0.014$). The clear group separation along the main canonical axis of shape variation is shown in Figure 4. A correlation between masseter muscle weight and shape was calculated to be -0.456, indicating that the shape of the GDF-8 mutant mice gets more different from the wild-types as masseter muscle weight increases.

Mandibular wireframe deformations associated with the CVA (after adjusting for allometry) showed that the inferior border of the mandible of the myostatin-deficient mice had increased curvature and the height of the ramus was decreased when compared to the wild-type mice. These wireframes are shown in Figure 5 and Figure 6. The aforementioned increase in mandibular curvature was driven primarily by superior displacement of the gonial angle (ML 8) along with points associated with the anterior inferior body of the mandible (ML10 and ML11). The noted decrease in ramus height was driven principally by inferior displacement of points

associated with the coronoid and condylar process (ML5 and ML6). Concomitant buccal tipping of the mandibular incisor (ML1) was also observed in the GDF-8 mutant group.

5.0 DISCUSSION

For many years studies have sought to understand the association between muscles and bone morphology. The premise is that muscles under function create stress and strain on bone, thereby altering bone morphology. Perhaps most important to orthodontists is how this phenomenon operates in the mandible. The muscles of mastication, which typically include the masseter, medial pterygoid, lateral pterygoid, and the temporalis, insert at various locations on the mandible each exerting their own forces. Of clinical significance to orthodontists is the relationship between muscle function and craniofacial morphology and how it affects treatment decisions. It has been well documented that people with a deep bite have extensive development of both the masseter and the temporal muscles compared to those patients with an open bite (Sassouni, 1969). However it is not well known if the muscles determine bone morphology or vice versa (Pepicelli *et al.*, 2005). In treating patients it is important to consider their facial type and plan treatment respecting their musculature and vertical pattern. An example given by Pepicelli *et al.* (2005) is in the consideration of surgical Class II deep bites. In patients who are brachyfacial and have a deep bite it may be more stable to level them post-surgically compared to trying to overcome their heavy musculature pre-surgically. Although our job is to properly align the teeth we must also consider how this alignment relates to our patients' facial harmony.

In the absence of using a human model to study such an association, a suitable alternative is the mouse model. The GDF-8 (myostatin-deficient) mice have been found to be

hypermuscular compared to wild-type controls in previous studies (Szabo et al., 1998, Walsh and Celeste, 2005, Ravosa et al., 2007, Vecchione et al., 2007, 2010, Welle et al., 2009, Elkasrawy and Hamrick, 2010, Cray et al., 2011). Myostatin is a negative regulator of skeletal muscle. It could be hypothesized that at birth there is no difference between control mice and myostatin-deficient mice; however, at a certain age it is expected that increased load bearing on the mandible would create forces which change its shape. According to Moss and Salentijn (1969), "...all growth changes in the size, shape, and spatial position...of all skeletal units are always secondary to temporally primary changes in their specific functional matrices." In this study there is an increase in muscularity followed by a secondary change to mandibular bone morphology, the skeletal unit. Kneib et al. (2011) noted that the cranial vault, cranial base, mandible and face show a temporal sequence of growth related to hypermuscularity. Previous studies by Mooney et al. (2010) and have found that myostatin-deficient mice 28 days old have larger masseter muscle weight and body size compared to the mice at 1 day of age. They further described that the mandible shows a temporal sequence of compensatory growth related to hypermuscularity. A comparison of myostatin-deficient mice at 1, 28, 56, and 180 days of age showed that skeletal changes were evident by 28 days and became more pronounced with age.

The hypothesis of the present study proposed that epigenetic muscle-bone interactions during development cause mandibular shape changes in myostatin-deficient mice compared to wild-type controls by 28 days of age. Previous studies have shown that myostatin-deficient mice are hypermuscular with increased muscle size and weight (Vecchione et al., 2007, 2010). In these mice, any changes in bone are hypothesized to be mediated via their attached muscles. The present study found that there was a statistically significant difference in mandibular shape between the mice by 28 days. Studies by Mooney et al. (2010) reported longer mandibles,

shorter cranial bases, and different mandibular and cranial vault shapes by 28 days of age. The present study builds on these findings and illustrates in what way mandibular shape is different from wild type mice by 28 days. For instance, the myostatin-deficient mice exhibited shorter ramal height and increased curvature of the inferior border of the mandible. This is in contrast to previous studies which altered the food consistency of rats and found that ramal height was greatest in rats with a hard diet compared to those placed on a soft diet (Tuominen et al., 1993, Maki et al., 2002, Enomoto et al., 2009). This suggests that the shortened ramus height observed here may not simply be a functional consequence of increased muscle loading patterns (as in hard diet modeling experiments), but may relate other developmental muscle-bone interactions. As many of the papers in this area are case reports and the results appear to be conflicting, it would be beneficial to see the results from a study with a larger sample size. A study by Renaud et al. (2010) studied the effect of a hard diet vs. a soft diet on the shape of the mouse mandible. The authors found that some areas of the mandible are more prone to postnatal plastic remodeling than others (ie. angular process) and that by altering food consistency, the shape but not the size of the mandible was affected. The changes to mandibular shape were found to be focused in areas related to mastication. The study found that mice fed a soft diet had "...a less robust alveolar region, a dorsally shifted molar alveolar region, and less robust angular processes" (Renaud et al., 2010). These results are consistent with the present study in that the changing muscular forces altered mandibular morphology most dramatically in regions associated with masticatory muscle attachments.

The curved mandible phenotype observed here in 28 day-old myostatin-deficient mice may be analogous to the 'rocker' mandible, reported in the anthropological literature to be prominent in Polynesian populations. This phenotype has been documented by Vecchione et al.

(2007, 2010) for myostatin-deficient mice 180 days of age. The ‘rocker’ mandible is estimated to occur in approximately 50% of all Polynesian crania (Marshall and Snow, 1956). When placed on a flat surface, the mandible rests on only two points of contact on a plane surface and is unstable when touched (Houghton, 1978). The Polynesian facial pattern includes: shorter posterior facial height, larger gonial angle, and the ‘rocker’ mandible (Schendel *et al.*, 1980). In a ‘rocker’ mandible, the inferior border of the mandible is described as convex and lacks an antegonial notch (Houghton, 1978, Vecchione *et al.*, 2007, 2010). Houghton (1977) describes this phenomenon as a byproduct of mandibular rotations. Polynesians possess open cranial base angles and a large upper facial height which creates a displacement or rotation at the condyle down and back; in order to maintain occlusion, rotation of the mandibular body upward in a closing direction is needed. The author states that this closed ramus-body angle is the cause of the loss of the antegonial notch. These findings are in contrast to our study which found that the myostatin-deficient mice had a larger or more open gonial angle (ramus-body angle). This suggests that perhaps a different process is causing the “rocker shaped” mandible in the mice.

In this study, the shape of the myostatin-deficient mice (Figs. 5 and 6), compared to the wild-type, had a shorter vertical ramus and a more convex inferior border of the mandible. An important consideration is timing; when in the development of a mouse or human, do these morphological changes occur? In humans, studies have found that the ‘rocker’ mandible occurs only in adults (Houghton, 1978, Schendel *et al.*, 1980), suggesting a rather straightforward association between skeletal morphology and biomechanical forces. Similarly, Vecchione *et al.* (2007; 2010) previously noted the presence of the rocker-type configuration in 180 day old mice. In the present study, however, GDF-8 mutant mice were shown to express this trait by at least day 28. This fact, of course, does not rule out biomechanics as the most likely cause, since the

musculature is already highly overdeveloped in this model by this age. To further pinpoint the origin of this trait, it will be necessary to examine time points between birth and 28 days. A sample of 1 day old mice have been previously studied (Vecchione *et al.*, 2010), and although the authors noted several other gross morphological changes to the mandible, they did not note the presence of the ‘rocker’ trait at this age. Unfortunately, cephalograms previously obtained on these 1 day old mice did not allow for a sufficiently detailed morphometric shape analysis of the mandible.

Preliminary statistics, which included size in the evaluation of shape, found no statistically significant difference in mandibular shape between the two groups of mice. The dependence of shape on size is referred to as allometry (Klingenberg, 2010). Although the tracing configurations are scaled during the Procrustes superimposition, size is not completely eliminated as a potential confounding variable. Statistical methods (e.g., regression) must be employed to extract shape information that is completely independent of size. Once statistics were performed to remove the allometric contribution of the shape variation, the myostatin-deficient mice and the wild-type controls were found to be statistically significantly different. This suggests that body size was acting as a confounder, partially masking the shape differences.

The predominant method for quantifying the effects of muscle function on craniofacial structure has been traditional cephalometric analysis of a lateral cephalogram. Conventional cephalometrics employs linear distances, angles, areas of triangles, and ratios to analyze cephalograms (McIntyre and Mossey, 2003). However there are limitations to the information that may be extracted from such data, shape being one of them. The problems with conventional cephalometric analyses are two-fold: the first involves landmark collection while the second pertains to the actual analysis. The validity and reliability of accurately marking landmarks has

been questioned throughout the history of cephalometrics (Baumrind and Frantz, 1971, McIntyre and Mossey, 2003). There are some points which are more difficult to find than others. Another concern with the use of landmarks is that some are dependent on postural position of the subject (McIntyre and Mossey, 2003). For instance, the location of the landmark menton (Me) is defined as the lowest point on the mandibular symphysis, which will change position as the subject's head moves up or down (Moyers and Bookstein, 1979).

Problems with the analysis involve the failure of angles, distances, and ratios to provide a valid and complete description of biological shape. When using the conventional cephalometric analysis to compare two different subjects, such analyses are only able to provide a partial description of shape and are biased by reference structures (Halazonetis, 2004). For instance, the so-called reference planes (Frankfort horizontal, Sella-nasion) may be inherently different between subjects and should not serve as loci for superimposition between subjects. All landmarks should be weighted equally, as in the Procrustes superimposition, and no preference should be given to those points located on the cranial base. Another limitation is that raw information from the cephalogram which rely on angles, fails to provide an adequate description of curved structures (Moyers and Bookstein, 1979). The true outline of a structure defined by three points may vary subtly around its landmarks. As mentioned by the authors, an arch, a bulge, and a wave are three very different shapes, yet all may have the same angle. Conventional analysis only describes a part of the shape. With the well documented limitations to the types of information such analyses provide, the present study aimed to quantify shape differences utilizing a geometric morphometric approach.

Geometric morphometrics uses multivariate statistics and is different from other analyses in that results "...can be visualized as shape changes and interpreted anatomically"

(Klingenberg, 2010). This technique is often used in biological systems to show shape variation and may be a more valid tool than conventional cephalometric analyses (Halazonetis, 2004). Jonke et al. (2007) suggests that geometric morphometrics has been proven to be a superior statistical test to “distance and angle-base methods.” Due to the many benefits of using this analysis, it is a tool which orthodontists may be able to utilize for analyzing skeletal changes in their patients. In a previous study by Halazonetis (2004), the author “... recommended that Procrustes superimposition and principal component analysis be incorporated into routine cephalometric analysis for more valid and comprehensive shape assessment.”

6.0 CONCLUSIONS

1. The mandibular shape of myostatin-deficient mice (GDF-8 deficient) is statistically different by 28 days of age compared to the wild-type, once size is controlled for.
2. Myostatin-deficient mice display increased curvature of the inferior border of the mandible ('rocker shape') and decreased ramal height compared to the wild-type control mice.
3. Epigenetic muscle-bone interactions during development cause mandible shape changes in myostatin knockout mice compared to wild-type mice. The myostatin knockout only directly affects muscle, so any changes in bone are mediated via attached muscles.
4. Geometric morphometrics is a valid statistical method for analyzing biological shape and may have other applications in the field of orthodontics.

APPENDIX A

TABLES

Table 1: Sample

	28 Day Old (17)	
	Male (12)	Female (5)
Wild-Type (9)	4	5
Knockout (8)	8	0

APPENDIX B

FIGURES

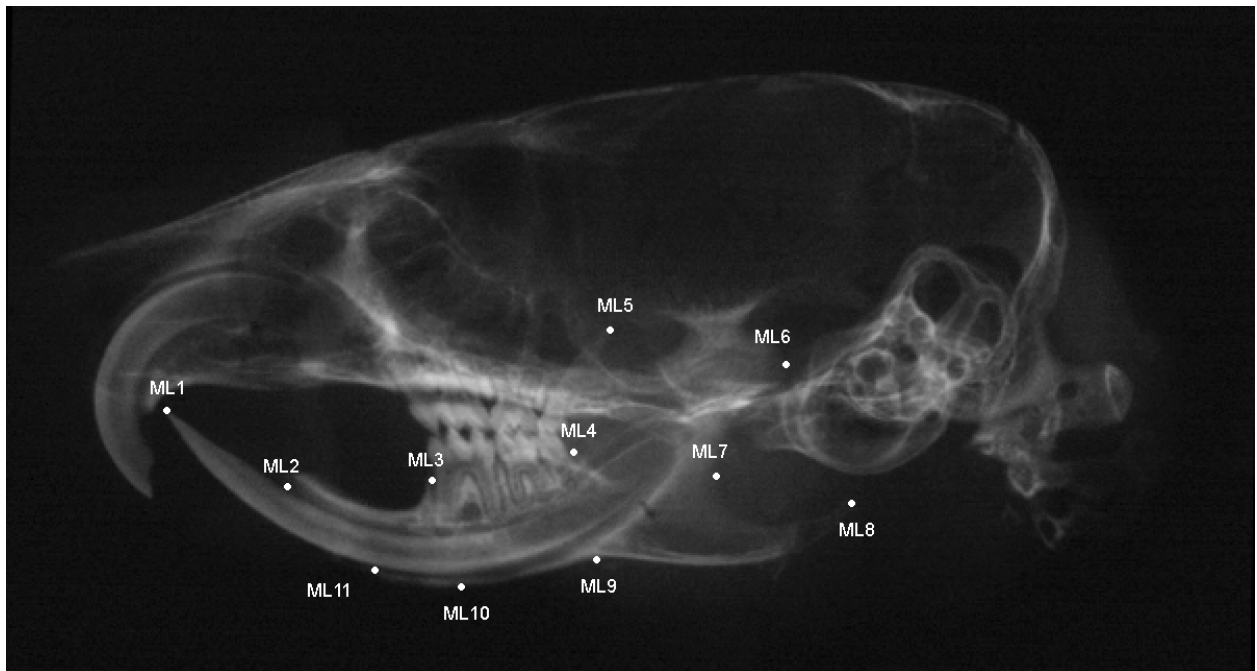


Figure 1: Tracing Example

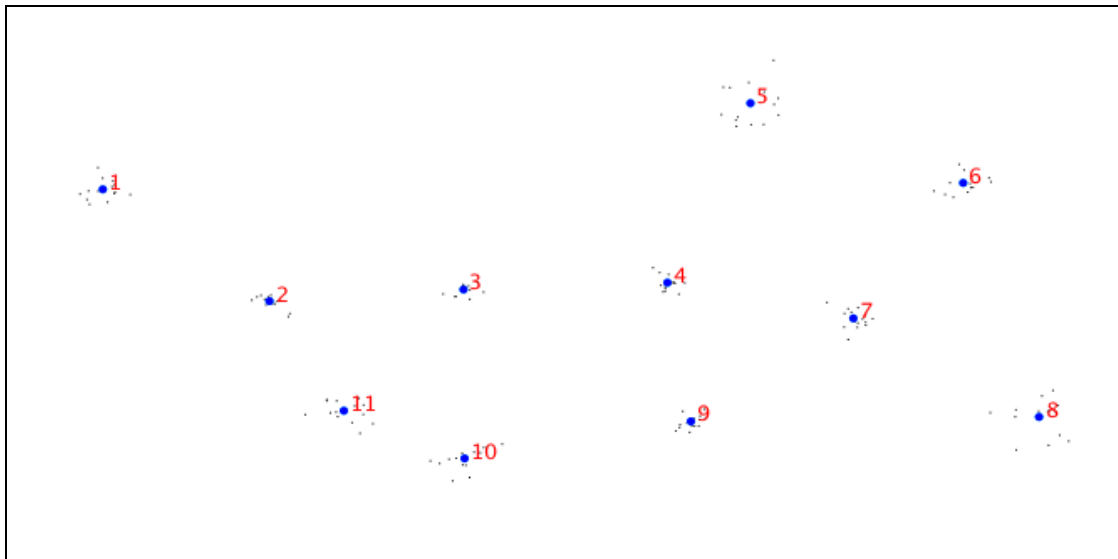


Figure 2: Shape Variables Following Procrustes Superimposition

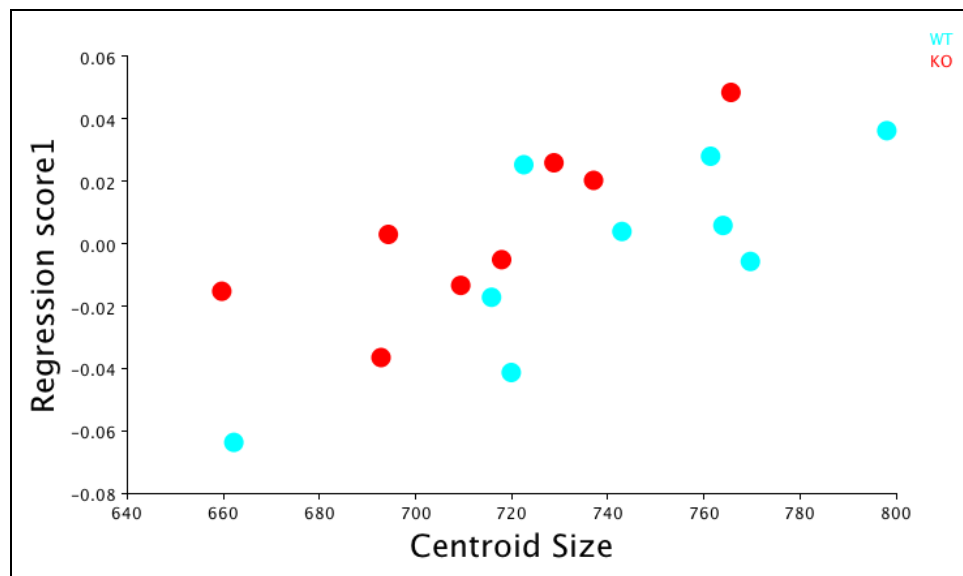


Figure 3: Regression of Shape on Centroid Size

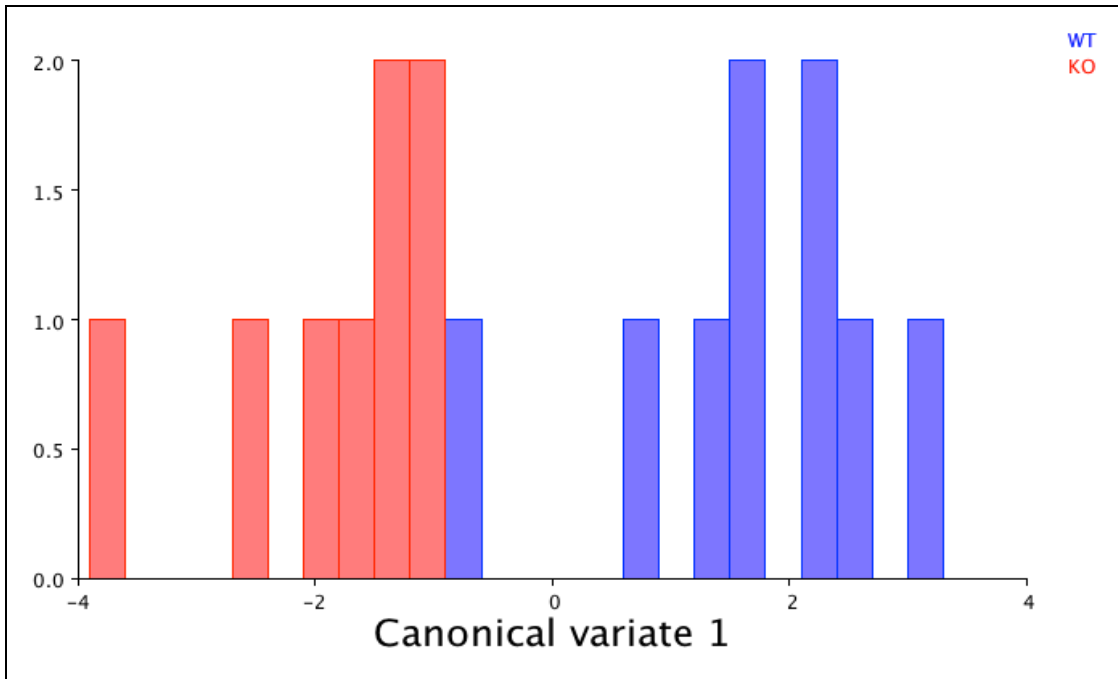


Figure 4: CVA Results After Removing Allometry

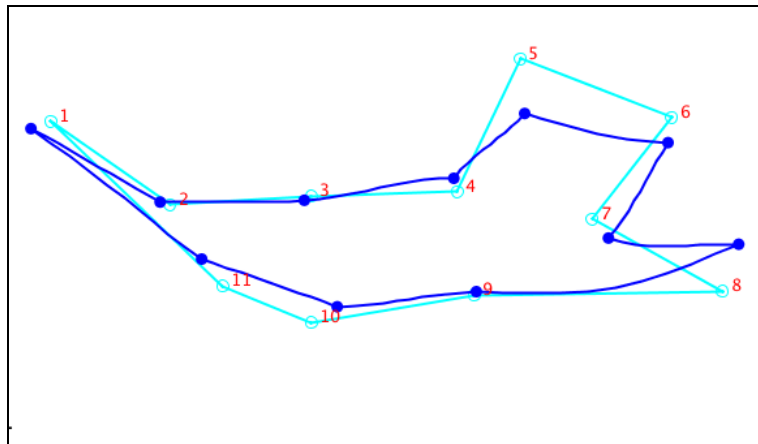


Figure 5: Wireframe Deformations: GDF-8 Mutant Mandible Compared to Consensus Shape

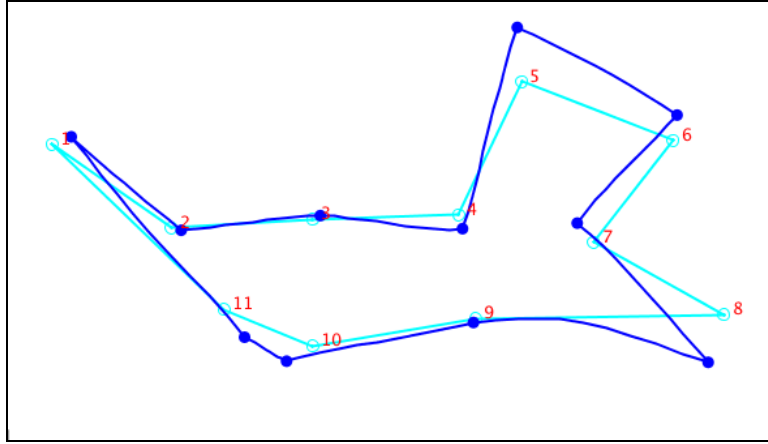


Figure 6: Wireframe Deformations: Wild-Type Mandible Compared to Consensus Shape

BIBLIOGRAPHY

- Adams DC, Rohlf FJ, Slice DE. (2004). Geometric morphometrics: ten years of progress following the 'revolution.' *Ital J Zool* 71:5-16.
- Avis V. (1959). The relation of the temporal muscle to the form of the coronoid process. *Am J Phys Anthropol* 17(2):99-104.
- Avis V. (1961). The significance of the angle of the mandible: an experimental and comparative study. *Am J Phys Anthropol* 19:55-61.
- Beecher RM, Corruccini RS. (1981). Effects of dietary consistency on craniofacial and occlusal development in the rat. *Angle Orthod* 51(1):61-69.
- Baumrind S, Frantz RC. (1971). The reliability of head film measurements. *Am J Orthod* 60(2): 111-127.
- Carlson DS. (1999). Growth modification: from molecules to mandibles. In: McNamara JA(ed). *Growth Modification: What works, what doesn't, and why*. Ann Arbor: Center for Human Growth and Development, University of Michigan. 17-61.
- Cheverud JM, Routman EJ, Irschick DJ. (1997). Pleiotropic effects of individual gene loci on mandibular morphology. *Evolution* 51(6):2006-2016.
- Cray Jr., J., J. Kneib, L. Vecchione, CD. Byron, GM. Cooper, JE. Losee, MI. Siegel, MW. Hamrick, JJ. Sciote, and MP. Mooney. Masticatory hyper-muscularity is not related to reduced cranial volume in myostatin-knockout mice. *Anat Rec*, 2011; 294:1170-1177.
- Da Silva HCFP, Cecanho R. (2009). Cephalometric changes produced by locally applied anabolic steroid in Wistar rats. *Arch Oral Biol* 54:389-395.
- Deguchi T, Garetto LP, Sato Y, Potter RH, Roberts WE. (1995). Statistical analysis of differential lissajous EMG from normal occlusion and Class III malocclusion. *Angle Orthod* 65(2):151-160.
- Eckhardt L, Harzer W, Schneevoigt R. (1997). Comparative study of excitation patterns in masseter muscle before and after orthognathic surgery. *J Cranio-Maxillofac Surg* 25:344-352.

- Elkasrawy MN, Hamrick MW. (2010). Myostatin (GDF-8) as a key factor linking muscle mass and bone structure. J Musculoskelet Neuronal Interact 10(1):56-63.
- Enomoto A, Watahiki J, Yamaguchi T, Irie T, Tachikawa T, Maki K. (2009). Effects of mastication on mandibular growth evaluated by microcomputed tomography. Eur J Orthod 32:66-70.
- Halazonetis DJ. (2004). Morphometrics for cephalometric diagnosis. AJODO 125:571-581.
- Hall JG. (2009). Importance of muscle movement for normal craniofacial development. J Craniofac Surg 21(5):1336-1338.
- Horowitz SL, Shapiro HH. (1955). Modification of skull and jaw architecture following removal of the masseter muscle in the rat. Am J Phys Anthropol 13:301-308.
- Horowitz SL, Shapiro HH. (1951). Modification of mandibular architecture following removal of temporalis muscle in the rat. J Dent Res 30(2):276-280.
- Houghton P. (1977). Rocker jaws. Am J Phys Anthropol 47(3):365-369.
- Houghton P. (1978). Polynesian mandibles. J Anat 127(2):251-260.
- Humphrey LT, Dean MC, Stringer CB. (1999). Morphological variation in great ape and modern human mandibles. J Anat 195:491-513.
- Jonke E, Prossinger H, Bookstein FL, Schaefer K, Bernhard M, Freudenthaler JW. (2007). Secular trends in the facial skull from the 19th century to the present, analyzed with geometric morphometrics. AJODO 132:63-70.
- Judex S, Gupta S, Rubin C. (2009). Regulation of mechanical signals in bone. Orthod Craniofac Res 12:94-104.
- Kitai N, Fujii Y, Murakami S, Furukawa S, Kreiborg, Takada K. (2002). Human masticatory muscle volume and zygomatico-mandibular form in adults with mandibular prognathism. J Dent Res 81(11):752-756.
- Klingenberg CP, Leamy LJ, Routman, EJ, Cheverud JM. (2001). Genetic architecture of mandible shape in mice: effects of quantitative trait loci analyzed by geometric morphometrics. Genetics 157:785-802.
- Klingenberg CP. (2002). Morphometrics and the role of the phenotype in studies of the evolution of developmental mechanisms. Gene 287:3-10.
- Klingenberg CP. (2010). Evolution and development of shape: integrating quantitative approaches. Nature Reviews:Genetics 11:623-635.

- Kneib JL., Cray Jr. J, Vecchione L, Craft T, Byron C, Cooper G, Hamrick M, Losee J, Sciote J, Mooney MP. (2011). Postweaning onset of craniofacial dysmorphology in GDF-8 (myostatin) deficient mice. *Journal of Dental Research*: 90A:2328.
- Maki K, Nishioka T, Shioiri E, Takahashi T, Kimura M. (2002). Effects of dietary consistency on the mandible of rats at the growth stage: computed X-ray densitometric and cephalometric analysis. *Angle Orthod* 72:468-475.
- Marshall DS and Snow CE. (1956). An evaluation of Polynesian craniology. *Am J Phys Anthropol* 14(3): 405-427.
- McIntyre GT, Mossey PA. (2003). Size and shape measurement in contemporary cephalometrics. *Eur J Orthod* 25:231-242.
- McPherron AC, Lawler AM, Lee SJ. (1997). Regulation of skeletal muscle mass in mice by a new TGF- β superfamily member. *Nature* 387:83-90.
- Menegaz RA, Sublett SV, Figueroa SD, Hoffman TJ, Ravosa MJ, Alderidge K. (2010). Evidence for the influence of diet on cranial form and robusticity. *Anat Rec* 293:630-641.
- Mooney M, Kneib J, Cray J, Vecchione L, Schroeder S, Byron C, Cooper G, Hamrick M, Losee J, Sciote J. Ontogeny of craniofacial dysmorphology in hypermuscular, GDF-8 (myostatin) deficient mice. Poster presented July 17, 2010. IADR. Barcelona, Spain.
- Moore WJ. (1973). An experimental study of the functional components of growth in the rat mandible. *Acta Anat (Basel)* 85:378-385.
- Moss JP, Chalmers CP. (1974). An electromyographic investigation of patients with a normal jaw relationship and a Class III jaw relationship. *Am J Orthod* 66(5):538-556.
- Moss ML. (1969). Functional cranial analysis of the mandibular angular cartilage in the rat. *Angle Orthod* 39(3):209-214.
- Moss ML, Rankow RM. (1968). The role of the functional matrix in mandibular growth. *Angle Orthod* 38(2):95-103.
- Moss ML, Salentijn L. (1969). The primary role of functional matrices in facial growth. *Am J Orthod* 55(6):566-77.
- Moss ML, Simon MR. (1968). Growth of the human mandibular angular process: a functional cranial analysis. *Am J Phys Anthropol* 28(2):127-138.
- Moyers RE, Bookstein FL. (1979). The inappropriateness of conventional cephalometrics. *AJO* 75(6):599-617.

- Murray PDF. (1936). *Bones: a study of the development and structure of the vertebrate skeleton*. Cambridge: Cambridge University Press.
- Nanda SK, Merow WW, Sassouni V. (1967). Repositioning of the masseter muscle and its effect on skeletal form and structure. *Angle Orthod* 37(4):304-308.
- Oshikawa M, Sugano N, Ishigaki R, Ito K. (2004). Gene expression in the developing mandible: a gene array study. *Arch Oral Biol* 49:325-329.
- Pepicelli A, Woods M, Briggs C. (2005). The mandibular muscles and their importance in orthodontics: A contemporary review. *Am J Orthod Dentofacial Orthop* 128(6):774-779.
- Poliachik SL, Bain SD, Threet D, Huber P, Gross TS. (2010). Transient muscle paralysis disrupts bone homeostasis by rapid degradation of bone morphology. *Bone* 46:18-23.
- Pratt LW. (1974). Experimental masseterectomy in the laboratory rat. *J Mammal* 24:204-211.
- Profitt WR, Fields HW. (1983). Occlusal forces in normal- and long-face children. *J Dent Res* 62(5):571-574.
- Profitt WR, Fields HW, Sarver DM. (2007). Contemporary Orthodontics: Fourth Edition. St. Louis: Mosby Elsevier, 1997.
- Raadsheer MC, van Eijden TMGJ, van Ginkel FC, Pahl-Andersen B. (1999). Contribution of jaw muscle size and craniofacial morphology to human bite force magnitude. *J Dent Res* 78(1):31-42.
- Ravosa MJ, Klopp EB, Pinchoff J, Stock SR, Hamrick MW. (2007). Plasticity of mandibular biomineralization in myostatin-deficient mice. *J Morphology* 268:275-282.
- Renaud S, Auffray JC, de la Porte, S. (2010). Epigenetic effects on the mouse mandible: common features and discrepancies in remodeling due to muscular dystrophy and response to food consistency. *BMC Evol Biol* 10:28.
- Riesenfeld A. (1969). The adaptive mandible: an experimental study. *Acta Anat (Basel)* 72:246-262.
- Sabashi K, Saitoh I, Hayasaki H, Iwase Y, Kondo S, Inada E, Takemoto Y, Yamada C, Yamasaki Y. (2009). A cross-sectional study of developing resting masseter activity in different angle classifications in adolescence. *J Craniomandibular Practice* 27(1):39-45.
- Sassouni V. (1969). A classification of skeletal facial types. *AJO* 55(2):109-123.
- Schendel SA, Walker G, Kamisugi A. (1980). Hawaiian craniofacial morphometrics: average Mokapuian skull, artificial cranial deformation, and the “rocker” mandible. *Am J Phys Anthropol* 52(4):491-500.

- Schmitt D, Zumwalt AC, Hamrick MW. (2010). The relationship between bone mechanical properties and ground reaction forces in normal and hypermuscular mice. J Exp Zool 313A:339-351.
- Siegel MI, Mooney MP. (1990). Appropriate animal models for craniofacial biology. Cleft Palate J 27(1):18-25.
- Szabó G, Dallmann G, Müller G, Patthy L, Soller M, Varga L. A deletion in the myostatin gene causes the compact (Cmpt) hypermuscular mutation in mice. (1998). Mamm Genome 9(8):671-672.
- Tecco S, Caputi S, Festa F. (2007). Electromyographic activity of masticatory, neck and trunk muscles of subjects with different skeletal facial morphology- a cross sectional evaluation. J Oral Rehab 34:478-486.
- Thongudomporn U, Chongsuvivatwong V, Geater AF. (2009). The effect of maximum bite force on alveolar bone morphology. Orthod Craniofac Res 12:1-8.
- Tuominen M, Kantomaa T, Pirttiniemi P. (1993). Effect of food consistency on the shape of the articular eminence and the mandible. Acta Odontologica Scandinavica 51:65-72.
- Ueki K, Takazakura D, Marukawa K, Shimada M, Nakagawa K, Yamamoto E. (2006). Relationship between the morphologies of the masseter muscle and the ramus and occlusal force in patients with mandibular prognathism. J Oral Maxillofac Surg 64:1480-1486.
- Van Limborgh, J. (1982). Factors controlling skeletal morphogenesis. Factors and mechanisms influencing bone growth. New York: Alan R. Liss, Inc., p.1-17.
- Vecchione L, Byron C, Cooper GM, Barbano T, Hamrick MW, Sciote JJ, Mooney MP. (2007). Craniofacial morphology in myostatin-deficient mice. J Dent Res 86(11):1068-1072.
- Vecchione L, Miller J, Byron C, Cooper GM, Barbano T, Cray J, Losee JE, Hamrick MW, Sciote JJ, Mooney MP. (2010). Age-related changes in craniofacial morphology in GDF-8 (myostatin)-deficient mice. Anat Rec 293:32-41.
- Vogl C, Atchley WR, Cowley DE, Crenshaw P, Murray JD, Pomp D. (1993). The epigenetic influence of growth hormone on skeletal development. Growth, Dev, Aging 57:163-182.
- Wall, N. (2006). Orthodontics in 3 millennia. Chapter 9: Functional appliances to midcentury. Am J Orthod Dentofacial Orthop 129: 829-33.
- Walsh FS, Celeste AJ. (2005). Myostatin: a modulator of skeletal-muscle stem cells. Biochem Society Transactions 33(6):1513-1517.
- Weinberg, SM, Naidoo SD, Bardi KM, Brandon CA, Neiswanger K, Resick JM, Martin RA, Marazita ML. (2009). Face shape of unaffected parents with cleft affected offspring:

combining three-dimensional surface imaging and geometric morphometrics. Orthod Craniofac Res 12:271-281.

Welle S, Cardillo A, Zanche M, Tawil R. (2009). Skeletal muscle gene expression after myostatin knockout in mature mice. *Physiol Genomics* 38:342-350.

Yamaoka M, Okafuji N, Furusawa K, Hasumi-Nakayama YH, Hayama H, Yamada AS, Kurihara S. (2001). Alteration of the angle of the coronoid process in prognathism. *J Oral Rehab* 28:479-484.

Yonemitsu I, Muramoto T, Soma K. (2007). The influence of masseter activity on rat mandibular growth. *Arch Oral Biol* 52:487-493.

Zelditch ML, Swiderski DL, Sheets HD, Fink WL. (2004). *Geometric morphometrics for biologists: a primer*. Amsterdam: Elsevier Academic Press.

Zepa K, Urtane I, Krisjane Z, Krumina G. (2009). Three-dimensional assessment of musculoskeletal features in Class II and Class III patients. *Stomatologija* 11:15-20.