

Technique of Renal Homotransplantation

Experience With 42 Cases

THOMAS E. STARZL, MD; THOMAS L. MARCHIORO, MD; THEODORE C. DICKINSON, MD;
DAVID RIFKIND, MD; OLIVER G. STONINGTON, MD; AND WILLIAM R. WADDELL, MD, DENVER

Purely technical considerations play an important role in successful renal homotransplantation. Minimization of homograft ischemia is critical. Additional important factors involve the site of placement of the homograft, provision for uninked vascular channels, selection of a method of ureteroneocystostomy which permits early removal of the urethral catheter, and use of a one-stage operation incorporating bilateral nephrectomy and splenectomy in addition to homotransplantation.

In the present study, the methods used to meet these purely surgical requirements will be described as they have evolved in the course of caring for the first 42 patients treated with renal homografts from living donors. Consideration will not be given to patients receiving cadaveric kidneys¹ or two who received homografts from identical twins,² since the circumstances in such cases are different than those which obtained with our major experience.

The prerequisites and techniques of the donor operation have recently been fully doc-

umented by Marchioro and his associates. It should be noted that the homograft is cooled and heparinized in every case in order to minimize the ischemic injury during transfer of the kidney.³ The following description will treat only of the procedures which are directly applied to the recipient patient.

Surgical Techniques

General Considerations.—A description of the surgical techniques employed involves considerably more than just the homografting procedure, since bilateral nephrectomy and splenectomy are an integral part of the total therapy,⁴ and are usually performed at the same time as homotransplantation (Table 1). The additional adjuvant procedure of thymectomy⁵ which was used in eight patients early in the series has been discontinued, at least until long term follow ups are obtained on those patients already so treated.

The technical problems are no different from those encountered in any major surgical operation. Nevertheless, the predictably poor healing processes, caused by the metabolically depleted state of the

TABLE 1.—Comparison of Results with Staged Versus One-Stage Surgical Treatment*

	No.	Alive	Dead
One-Stage	31	19	12
Two or more stages	11	5	6
	42	24	18

* All patients had transplantation 95 days or longer prior to Feb 27, 1964. The average survival in the living patients is 217 days, ranging from 95 to 461. The average survival of those who died was 66 days, with a range of 1 to 208.

Read before the 21st Annual Meeting of the Central Surgical Association, Rochester, Minn, Feb 27-29, 1964.

Markle Scholar (Dr. Starzl).
From the departments of surgery and medicine, University of Colorado Medical Center and Veterans Administration Hospital.

Aided by grants A-6283, A-6344, HE 07735, AM 07772, AI041542, and OG 27 from the United States Public Health Service.

Starzl et al

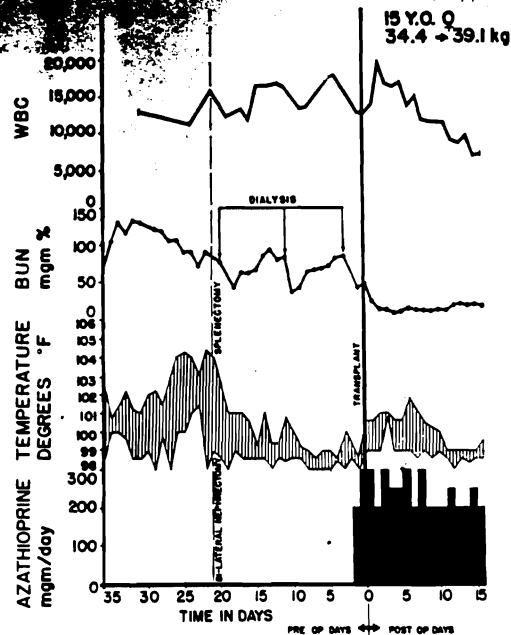


Fig 1.—Course of a patient who received staged surgical care because of urinary tract infection. The child had polycystic kidney disease with coliform and fungal infection within multiple cysts of each kidney. Bilateral nephrectomy and splenectomy were carried out at a first stage, resulting in prompt relief of the preexisting hyperpyrexia. Three weeks later, renal transplantation was performed. She is now eight months postoperative.

patients and by the necessity for immunosuppressive therapy, reduce the margin of safety which may permit success in other operations in spite of the commission of small errors. It is mandatory to obtain primary wound healing. Wound drains or cystostomies are never used, and urethral catheters which are inserted at the time of operation are extracted within 24 hours.

Interrelationship of Operation and Incisions.—Originally it was thought that multiple operations would be required, but subsequent experience has shown that this is not the case. Bilateral nephrectomy, splenectomy, and homotransplantation are well tolerated in one stage (Table 1), and unless there is a specific contraindication, this is the method now used except for those patients in whom an upper urinary tract infection is present. In the latter circumstances, splenectomy and bilateral nephrectomy are carried out initially (Fig 1), and transplantation is performed two or three weeks later after good wound healing from the original operation has occurred.

A variety of exposures have been used for patients receiving one-stage therapy, depending in some cases upon the location planned for the homotransplant. The most versatile and most commonly used at the present time is an upper midline incision, through

which both kidneys and spleen are removed transperitoneally, in combination with an extraperitoneal transplantation to either the right or left iliac fossa (Fig 2C). If transplantation is planned of a donor left kidney to the right iliac fossa, both transplantation and right nephrectomy can be done extraperitoneally through an oblique right lower abdominal incision, and left nephrectomy and splenectomy performed transperitoneally through a separate left subcostal incision (Fig 2A). In transplanting a donor right kidney to the left iliac fossa, three incisions may be used—one for the extraperitoneal transplantation, another for transperitoneal left nephrectomy and splenectomy, and a third for either extra or intraperitoneal right nephrectomy (Fig 2B). In three children of 3 to 8 years,⁶ the entire operation was performed transperitoneally through a total midline abdominal incision (Fig 2D), using relatively oversized homografts from adult donors.

Homotransplantation.—The donor kidneys are usually but not necessarily placed in the contralateral iliac fossa after the method described by Küss,⁷ and popularized by Murray and Harrison⁸ and Hume.⁹ The anteroposterior relationships of the hilar structures are thereby usually reversed, placing the pelvis anteriorly and the renal vein posteriorly in the new location. There are no important differences in technique with transplantation to one as opposed to the other side, so the following description in which the homograft is placed on the right applies equally to the comparable operation on the left. In the usual case, the splenectomy and nephrectomies have already been completed as described above, and the upper abdominal incision or incisions have been closed. In four cases, donor right kidneys were placed in the right iliac fossa with good results, so the use of contralateral homografts as described below is not mandatory. Deviations from the standard technique to be described constitute a special problem, and have been described in detail elsewhere.^{6,10}

An oblique lower abdominal incision is made, and deepened to the extraperitoneal plane (Fig 3 and 4). The inferior epigastric vessels (Fig 4C) and the spermatic cord (Fig 4D) are quadruply ligated and divided. If the recipient's right kidney is to be removed through this incision, this is done now.

The lymphatic and areolar tissue overlying the external iliac vein is incised, ligating all filaments of tissue (Fig 5E) in order to prevent postoperative lymph leakage. The presence of valves in the external iliac vein is noted, and when possible the venous anastomosis is performed either above or below these structures. If this is inconvenient, the valves are excised at the time of the anastomosis.¹⁰ The hypogastric artery is then denuded of surrounding tissue and cleaned to the point of its first division (Fig 5F and 5G). Since kidneys are no longer used which do not have a single renal artery,⁸ dissection

removed trans-
 an extraperitoneal
 or left iliac fossa
 planned of a donor
 both transplanta-
 e done extraperi-
 t lower abdominal
 splenectomy per-
 a separate left
 In transplanta-
 e left iliac fossa,
 for the extraperi-
 or transperitoneal
 y, and a third for
 right nephrectomy
 3 to 8 years,⁶ the
 l transperitoneally
 incision (Fig 2D),
 grafts from adult

onor kidneys are
 in the contralateral
 ribed by Küss,⁷ and
 rison⁸ and Hume.⁹
 s of the hilar struc-
 d, placing the pelvis
 steriorly in the new
 ant differences in
 o one as opposed to
 escription in which
 ight applies equally
 he left. In the usual
 recotomies have al-
 bed above, and the
 ncisions have been
 ight kidneys were
 with good results, so
 afts as described be-
 ns from the standard
 tute a special prob-
 detail elsewhere.^{6,10}

ncision is made, and
 plane (Fig 3 and 4).
 (Fig 4C) and the
 e quadruply ligated
 ight kidney is to be
 this is done now.

tissue overlying the
 ating all filaments of
 prevent postoperative
 of valves in the ex-
 i when possible the
 ned either above or
 is inconvenient, the
 of the anastomosis.¹⁰
 lended of surround-
 int of its first division
 ys are no longer used
 al artery,⁸ dissection

RENAL HOMOTRANSPLANTATION

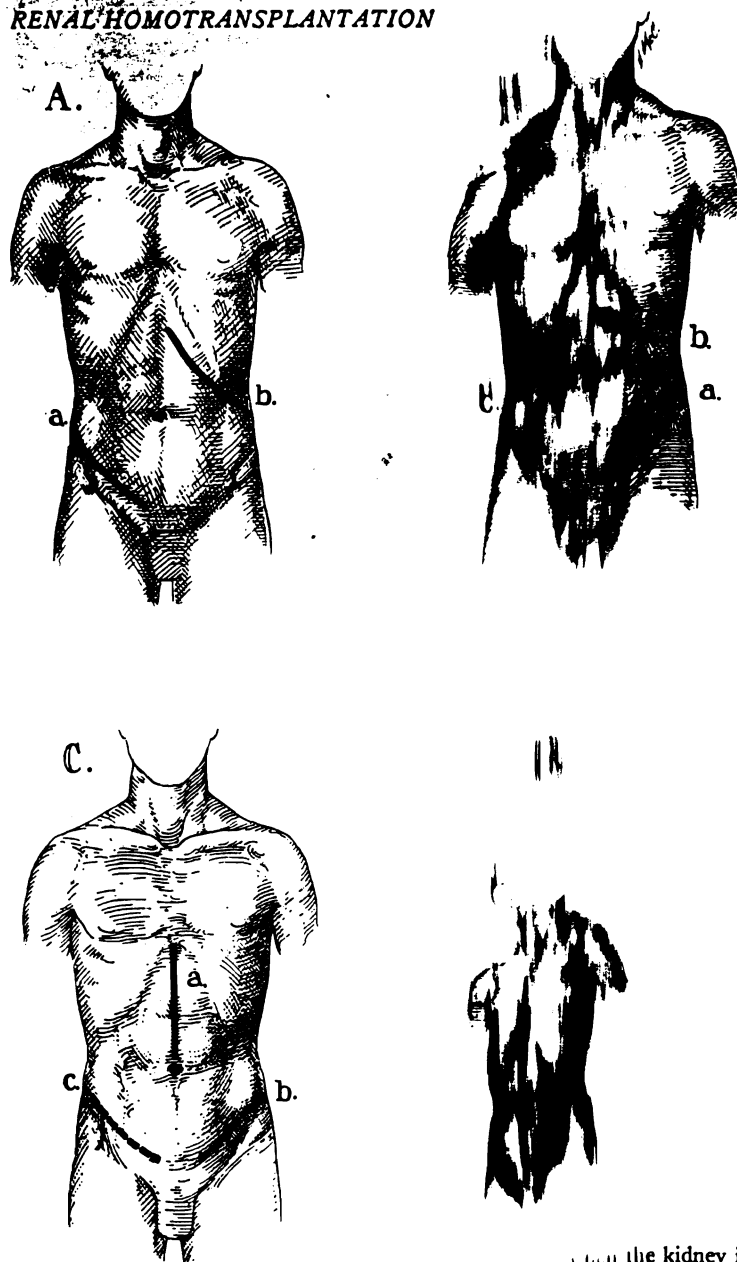


Fig 2.—Various combinations of incisions used for one-stage renal transplantation, bilateral nephrectomy, and splenectomy. A, incision commonly employed when transplantation is to the right side; B, combination of incisions which may be used when transplantation is to the left side; C, most commonly used incisions at the present time (see text); D, total abdominal incision used for the treatment of infants.

of the branches of the hypogastric artery for the
 in multiple vessel anastomoses is not necessary.

When it has been ascertained that the donor kidney will be available within a few minutes, a portion of the external iliac vein is isolated between Brown¹¹ sponge rubber, noncrushing clamps (Fig 6A and 6B). A disc of tissue is excised from the anterolateral wall of the vessel (Fig 6B) and three stay sutures of 5-0 arterial silk are placed (Fig 6C). Exposure is maintained and all activity sus-

the kidney is delivered, it is oriented in the
 tonic position as existed in the donor pa-
 (Fig 6C). The previously placed guide sutures
 are tied to the appropriate portions of the renal
 the kidney is guided into position until the
 layers of the two vessels are coated (Fig
 the kidney is then rolled laterally and a
 stay suture placed in the midportion of the
 wall of the renal vein (Fig 7E). Traction
 medial and lateral stay sutures helps in pre-
 accidental grasping of the opposite wall
 performing the venous anastomosis. One of
 wide sutures is then used to perform a con-
 anastomosis using an over-and-over tech-

* Edward Weck & Co., Long Island, NY.

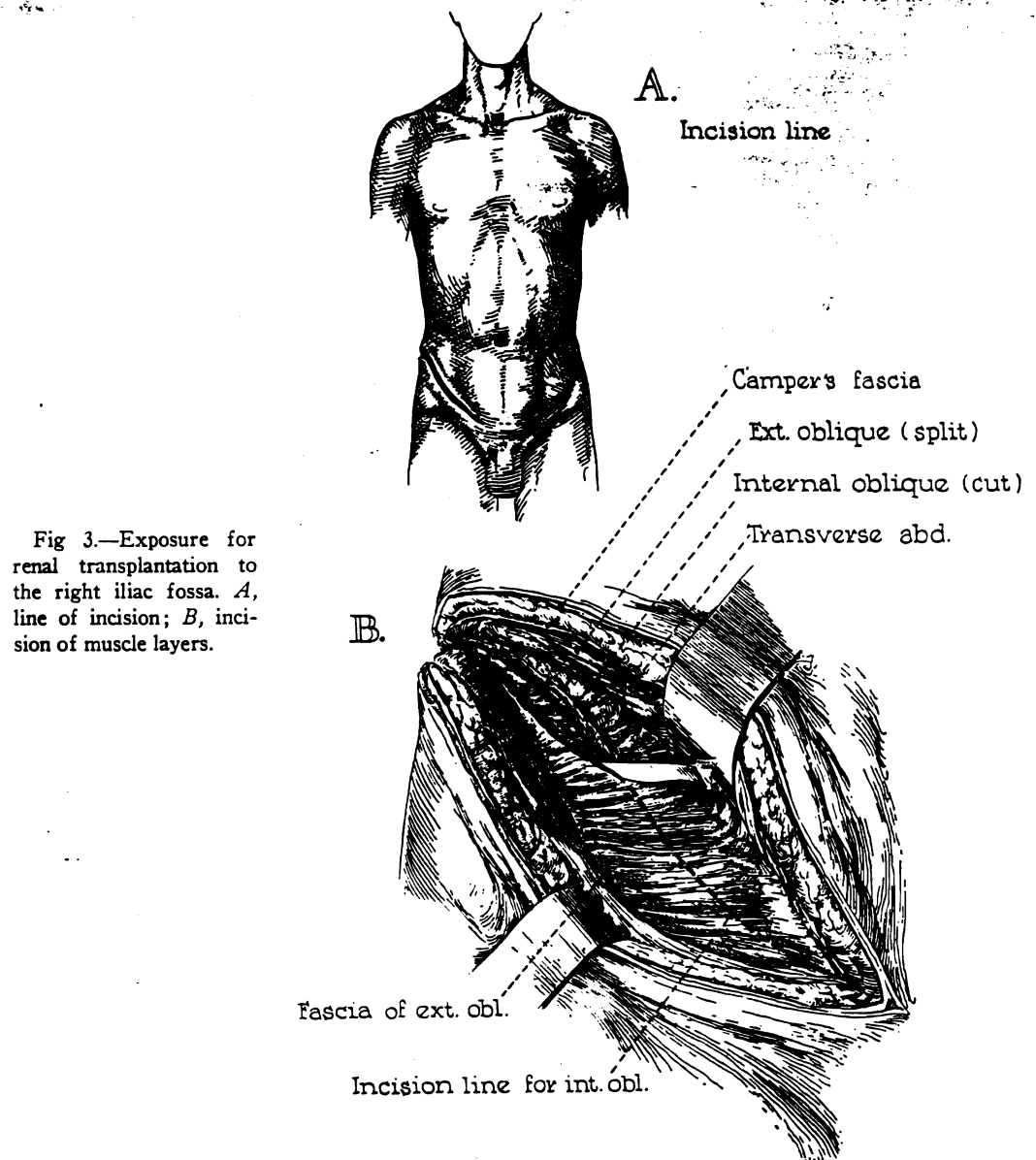


Fig 3.—Exposure for renal transplantation to the right iliac fossa. *A*, line of incision; *B*, incision of muscle layers.

nique. It is usually easier to sew the anterior row first, then reflecting the kidney medially in order to obtain access to the posterior surface (Fig 7E and 7F).

After completion of the venous anastomosis, the kidney is placed into what appears to be the most comfortable position in the iliac fossa. The distal hypogastric artery is ligated at this time, and after placement of a noncrushing clamp across the origin of this vessel from the common iliac artery, it is transected. The cut is made with an angulation (Fig 8A) to allow the subsequent formation of a smooth curve at the site of anastomosis. After placement of stay sutures in the hypogastric and renal arteries

(Fig 8B), an anastomosis is performed with 6-0 silk, using a continuous everting technique (Fig 8C-E).

After completion of both anastomoses, the clamps are released, taking care that arterial and venous occlusion are relieved simultaneously. The clamps are released abruptly rather than in a graduated fashion. The suture lines are scrutinized for leak and are systematically repaired with additional sutures. Under no circumstances is the blood supply to the kidney ever interrupted again. It is always possible to repair the small suture line leaks without reoccluding the circulation.

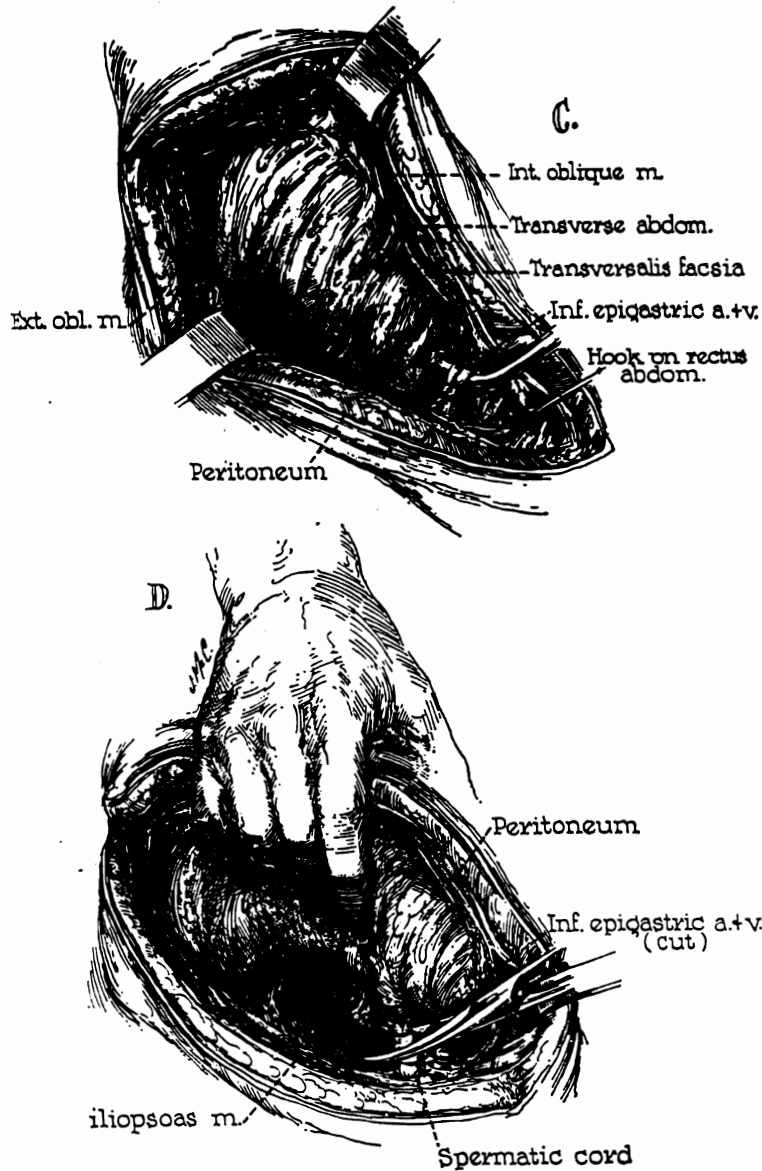


Fig 4.—Exposure of retroperitoneal space. C, ligation and division of inferior epigastric artery and vein; D, quadruple ligation and division of the spermatic cord (or round ligament in females).

At this time, experimentation is again conducted to determine the most comfortable position of the homograft. The most consistently useful rule to be followed is that the kidney will usually seek the position which is most suitable. A location which requires extensive capsular fixation is not desirable, and no restraining sutures of any sort are used to prevent movement. The ultimate location of the kidney has varied considerably (Fig 9). Usually the hollow of the ilium is adequate to accommodate the organ, but in some cases, most or all of the homograft is extrapelvic.

Having settled the location of the homograft, the ureter is anastomosed to the bladder by a modification of the method of Pacquin and Marshall.¹³ As

little mobilization of the bladder as possible is carried out. If possible, the retropubic space is not entered, thereby preventing the formation of a post-operative dead space. A small incision is made in the dome of the bladder near the peritoneal reflection. By appropriate manipulation of thin-bladed deep retractors, an adequate view can be obtained of the interior of the bladder (Fig 10A).

A site is selected 2 or 3 mm above the ipsilateral ureteral orifice for the location of the new ureteral tip. After making a small mucosal incision at this point, a similar counterincision is made 1 or 2 cm higher on the lateral wall (Fig 10B), and the intervening mucosa is tunneled by blunt hemostat dissection (Fig 10C). A right angle clamp is then

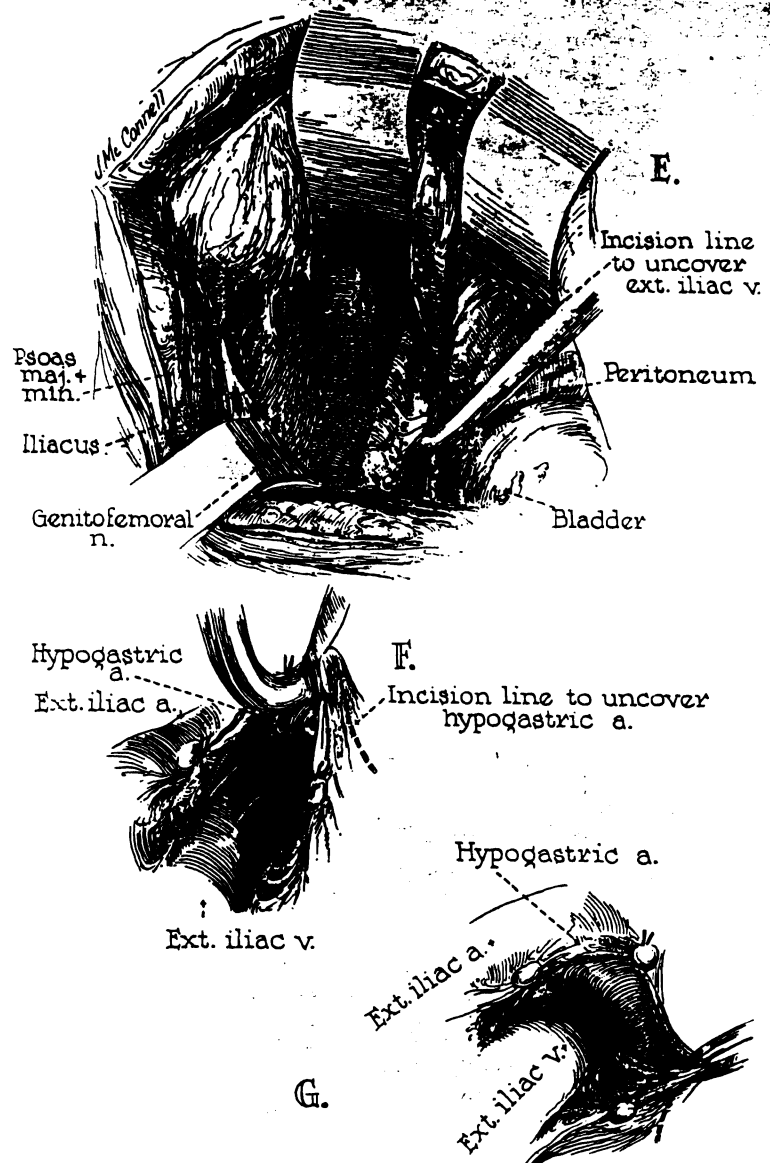
Starzl et al

ascia
 ue (split)
 blique (cut)
 2 abd.

formed with 6-0
 erting technique

omoses, the clamps
 rial and venous oc-
 y. The clamps are
 graduated fashion.
 for leak and are
 tional sutures. Un-
 ood supply to the
 is always possible
 eaks without reoc-

Fig 5.—Exposure of the iliac vessels. *E*, dissection of the external iliac vein. Note that all tissue in this area is doubly ligated before division in order to prevent the subsequent development of lymphatic leak. *F*, the external iliac vein is freed to the point where it is crossed by the hypogastric artery. *G*, the hypogastric artery is denuded distally to its major division.



thrust through the upper mucosal incision and out the lateral bladder wall (Fig 10D). The tip of the ureter is brought into the bladder (Fig 10D), and then through the previously formed submucosal tunnel (Fig 10E).

The upper mucosal incision is closed (Fig 11F) and attention directed to the formation of a ureteral nipple with a mucosal-to-mucosal anastomosis. The excess ureter is drawn up with a clamp (Fig 11G and 11H) and partially transected with formation of a fish mouth in the posterior or most inaccessible portion (Fig 11H). The principal ureteric blood vessels are identified near the site of transection and suture ligated with 5-0 plain catgut. Three 5-0 plain catgut sutures are then placed, catching first

the bladder mucosa, then the ureteral adventitia 3 or 4 mm proximal to the cut end, and finally grasping the edge of the ureteral mucosa (Fig 11I). When these three sutures are tied, a nipple is formed (Fig 11J). Transection of the excess ureter is then completed, fashioning an eccentric flap (Fig 11, J-L) which forms the rest of the nipple. After tacking the rest of the ureteral nipple into position (Fig 11L), a three-layer closure of the cystotomy is carried out. The mucosal layer is closed with continuous 4-0 chromic catgut, with eversion of the bladder mucosa in order to prevent intraluminal bleeding from the raw mucosal surface, and in order to obtain a reliable watertight closure. The second layer is also with continuous 4-0 chromic

RENAL HOMOTRANSPLANTATION

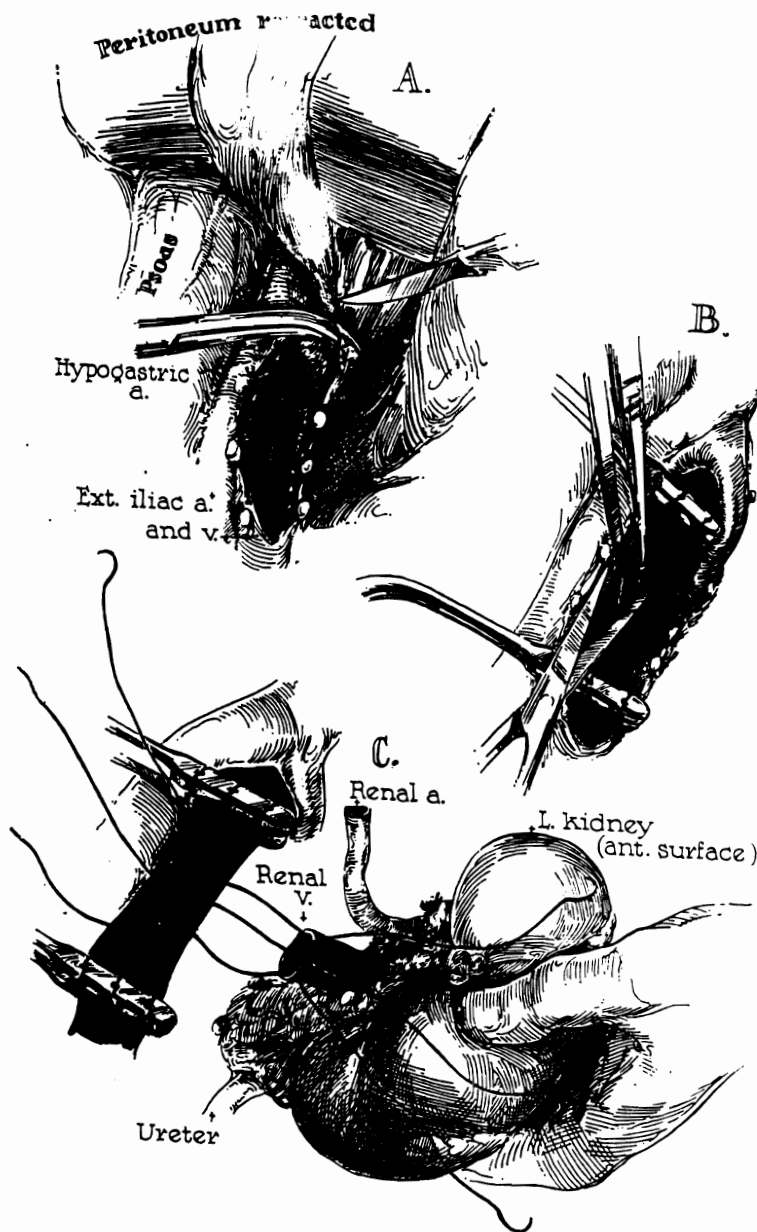


Fig 6.—Venous anastomosis. *A*, general operative field; *B*, excision of an ellipse of the anterolateral wall of the external iliac vein; *C*, placement of guide sutures connecting the renal and external iliac veins.

catgut, catching the detrusor muscle. An external layer of interrupted 4-0 silk is employed.

Many of the details of the bladder and ureteral manipulation are planned to achieve two specific objectives: first, the procurement of a clean dry wound which can be closed without drainage, and secondly, the establishment of a situation in which the urethral catheter can be safely removed within 12 to 24 hours after operation. The precautions that are exercised to obtain complete and reliable closure of all mucosal rents, to protect the blood supply of the ureter, to obtain the flap valve action provided by a long submucosal tunnel, and to obtain a watertight

closure of the cystotomy are all designed to remove the need for prolonged postoperative decompression of the bladder.

Prior to closure, a check is made for absolute hemostasis, and then the wound is irrigated with 1,000 to 2,000 cc saline solution. Before closure with fine silk technique, an antibiotic solution of 0.5 gm neomycin and 50,000 units of bacitracin suspended in 50 cc isotonic saline is instilled.

Results

The Influence of Homograft Quality.—As described in previous publications,^{8,12} all

Staral et al

E.
Incision line
to uncover
ext. iliac v.

Peritoneum

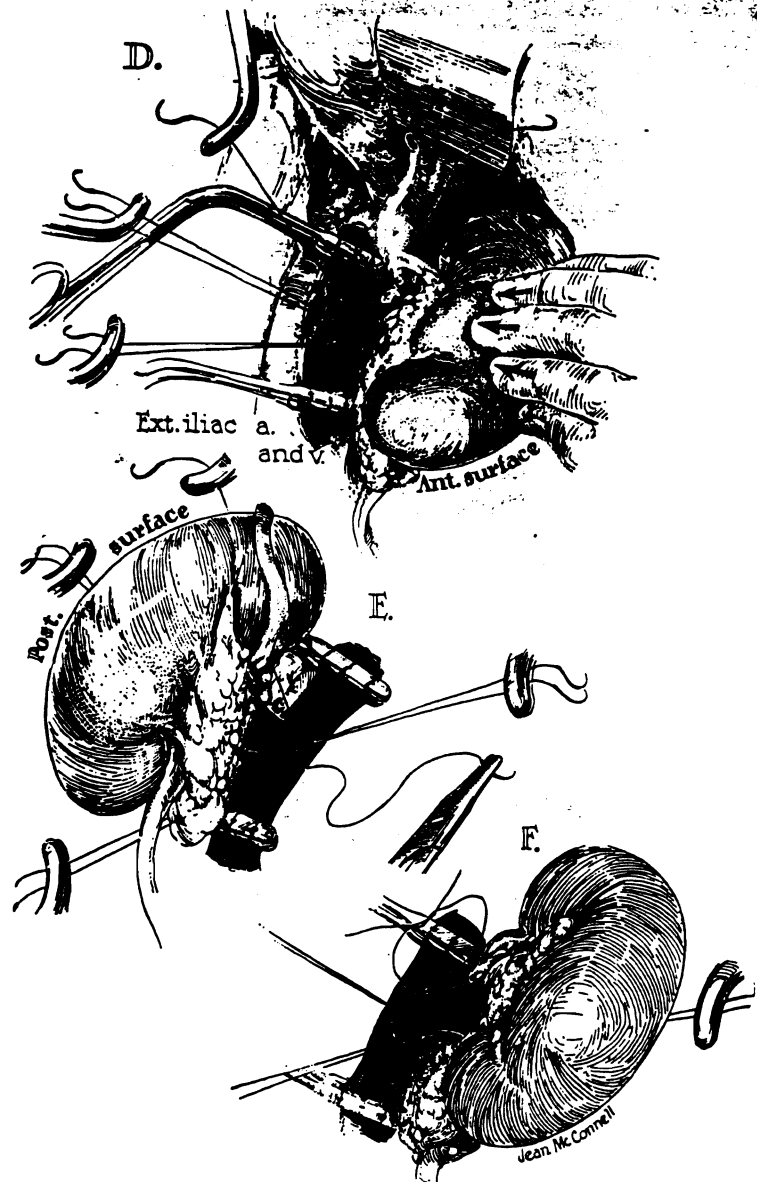
der

uncover
a.

C a.

eral adventitia 3
and finally grasp-
cosa (Fig 11I).
nipple is formed
ess ureter is then
ap (Fig 11, J-L)
After tacking
to position (Fig
the cystotomy is
closed with con-
version of the
ent intraluminal
surface, and in
ht closure. The
ous 4-0 chromic

Fig 7.—Venous anastomosis (continued). *D*, fixation of the venous anastomosis by tying the guide sutures; *E*, performance of circumferential anastomosis using continuous silk suture which is carried around the entire 360°; *F*, completion of anastomosis.



homografts were cooled and heparinized either by systemic heparinization and the induction of total body hypothermia in the donor patient, or by intra-arterial infusion of chilled lactated Ringer's solution to which heparin and procaine were added. Despite these precautions, evidence of acute tissue injury was often observed despite relatively short periods of ischemia. The analysis below concerns the function obtained from 44 homografts used in the treatment of 42 patients; excluding two additional homografts

which had to be removed immediately after their revascularization because of an acute hemagglutination reaction.^{13,14}

With 24 of the homografts, time from occlusion of the donor renal artery to restoration of blood flow in the recipient ranged from 17 to 30 minutes, the mean being 25.4 ± 0.7 (SE) minutes. Homograft function was generally prompt in these cases and a massive diuresis ensued, the hourly volumes for the first half day being 511 ± 56 (SE) ml/hour (Table 2). Within 48 hours,

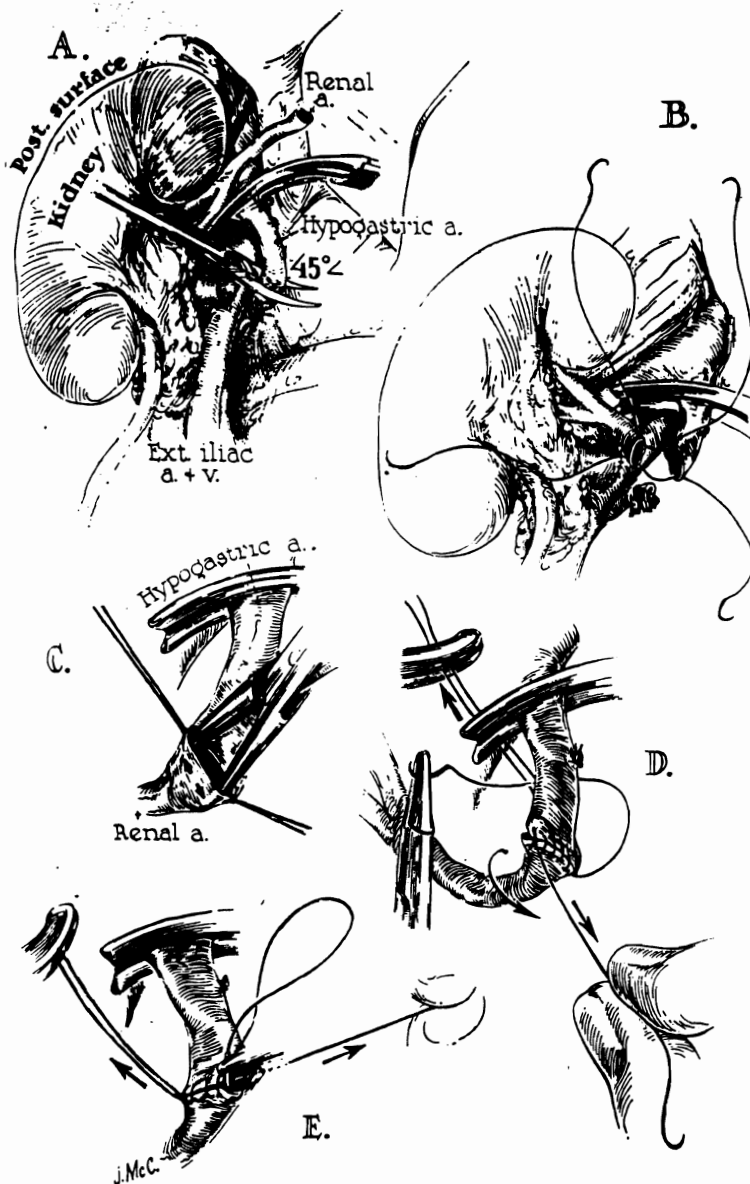


Fig 8.—Arterial anastomosis. *A*, the hypogastric artery has been ligated distally and is cut. Note bevel of incision line which makes a smoother curve of the reconstructed vessels. *B*, fixation sutures connecting the two vessels; *C*, dilatation of the smaller of the two vessels, the renal in this instance; *D*, completion of the anterior row and beginning rotation of the anastomotic line; *E*, continuous suture of the posterior suture line.

mediately after
of an acute

time from oc-
currence to restora-
tion ranged
mean being
nongraft func-
tional cases and
the hourly
being 511 ± 56
ml in 48 hours,

89, July, 1964

the mean BUN fell from 71.2 ± 4.8 (SE) mg% to 24.5 ± 3.0 (SE) mg%. Creatinine clearance rose to 97.9 ± 7.7 (SE) ml/min. The mean interval between revascularization and the beginning of urinary excretion was 33.7 ± 7.6 (SE) minutes.

Ischemia times of 31 to 43 minutes were inflicted upon 17 homografts with a mean of 38.1 ± 0.8 (SE) minutes. In these cases, early function was also obtained, the hourly urine volume for the first 12 hours being 393 ± 47 (SE) ml/hour. The average in-

terval between the times of revascularization and urine excretion was 30.7 ± 8.3 (SE) minutes. BUN's fell from 97.9 ± 11.9 (SE) mg% to 38.4 ± 6.7 (SE) mg%. The mean creatinine clearance was 53.4 ± 5.6 (SE) ml/min.

Three additional homografts required 61, 71, and 84 minutes of ischemia for transfer. Times from revascularization to notation of the first urine flow were 30 minutes, 60 minutes, and never, respectively. The hourly urine volumes for the first 12 hours were

Starzl et al

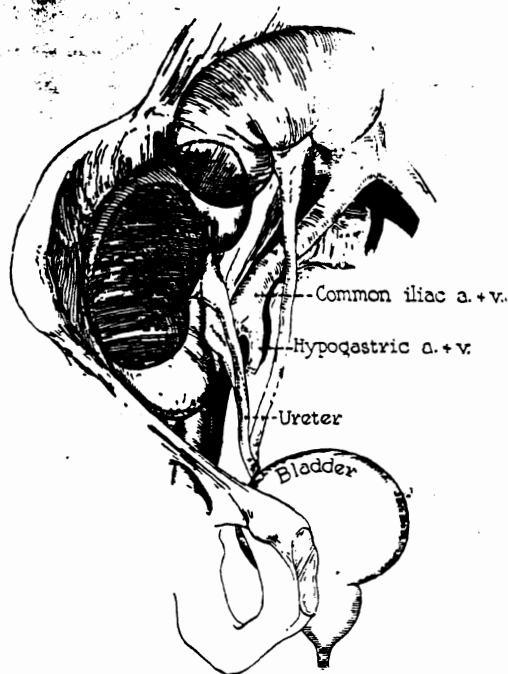


Fig 9.—Various positions assumed by the homografted kidney. The placement selected is the one which appears at the time of operation to be the most comfortably accommodated.

202, 63.4, and 0 ml. After 48 hours, BUN's in these three cases went from 63.5 to 60 mg%, 84 to 87 mg%, and 100 to 118 mg%, respectively. Creatinine clearances were 22, 15.6, and 0 ml/min.

Analysis was conducted of the significance of differences observed in those homografts receiving less than 30 minutes of ischemia and those with 31-43 minutes of ischemia. On the average, it will be noted (Table 2) that the performance of the kidneys with lesser degrees of ischemia was superior in all parameters except for the time of onset of urine flow which was equal in both groups. Statistically, the most easily demonstrable effect of ischemia was observed in measurements of creatinine clearance in which the differences in the two groups was highly significant ($P < 0.001$). Even within the group ischematized less than 30 minutes, rank order analysis demonstrated a positive correlation between ischemia time and early postoperative creatinine clearance ($\rho = 0.494$), the confidence level being 5%.

Noninfectious Complications.—Vascular Anastomoses: There were 97 blood vessel anastomoses, five homografts requiring reconstruction of a double arterial renal blood supply. No known anastomotic failures occurred. Although closure of an arterial anastomosis would certainly become clinically evident, there is no assurance that a venous occlusion would be detectable without examining the specimen, as illustrated by the following case:

Five weeks after homotransplantation, a patient (Denver Veterans Administration Hospital, A-15442) had a massive pulmonary embolus which was treated by cardiopulmonary bypass and pulmonary embolectomy.²⁸ Two days later, a Spencer vena caval plication²⁹ was performed. The patient recovered from these operations and had good renal function until his death from sepsis almost three months later. At autopsy it was found that the entire ilio caval system was completely thrombosed, including that segment into which the renal vein was anastomosed. Furthermore, the renal vein itself was occluded out to its smaller branches. There were extensive collateral veins in the surrounding tissue which had provided adequate drainage.

Ureteral Anastomoses: Ureteral implantation was also singularly free of technical complications (Table 3). In one case, a ureteral fistula at the ureteroneocystostomy site developed six days after operation. Reimplantation was carried out immediately with an apparently satisfactory early result. Nevertheless, the patient ultimately died of a perinephric abscess surrounding the homograft.⁴

In a second case, a small area of necrosis developed on the anterior surface of the pelvis of a renal homograft which had functioned satisfactorily for almost three weeks after operation. The patient had entered a rejection crisis a few days previously. At reoperation the interior of the ureteropelvic junction had patchy necrosis and the extra-renal collecting system was filled with debris and tissue which appeared to have blocked the distal ureter. It was not possible to be certain if this complication represented thrombosis of the blood supply to the ureter and pelvis, if it was secondary to a technical error resulting from obstruction of the ureter, or if it was the consequence of the

RENAL HOMOTRANSPLANTATION

ions.—Vascular
7 blood vessel
s requiring re-
rial renal blood
otic failures oc-
of an arterial
become clinically
e that a venous
le without ex-
strated by the

entation, a patient
on Hospital, A-
y embolus which
bypass and pul-
s later, a Spencer
med. The patient
nd had good renal
psis almost three
nd that the entire
rombosed, includ-
e renal vein was
nal vein itself was
ches. There were
urrounding tissue
nage.

eteral implanta-
ee of technical
n one case, a
oneocystostomy
operation. Re-
ut immediately
ry early result.
imately died of
ding the homo-

area of necrosis
surface of the
which had func-
ost three weeks
had entered a
previously. At
e ureteropelvic
and the extra-
led with debris
o have blocked
possible to be
n represented
ly to the ureter
y to a technical
uction of the
equence of the

ol 89, July, 1964

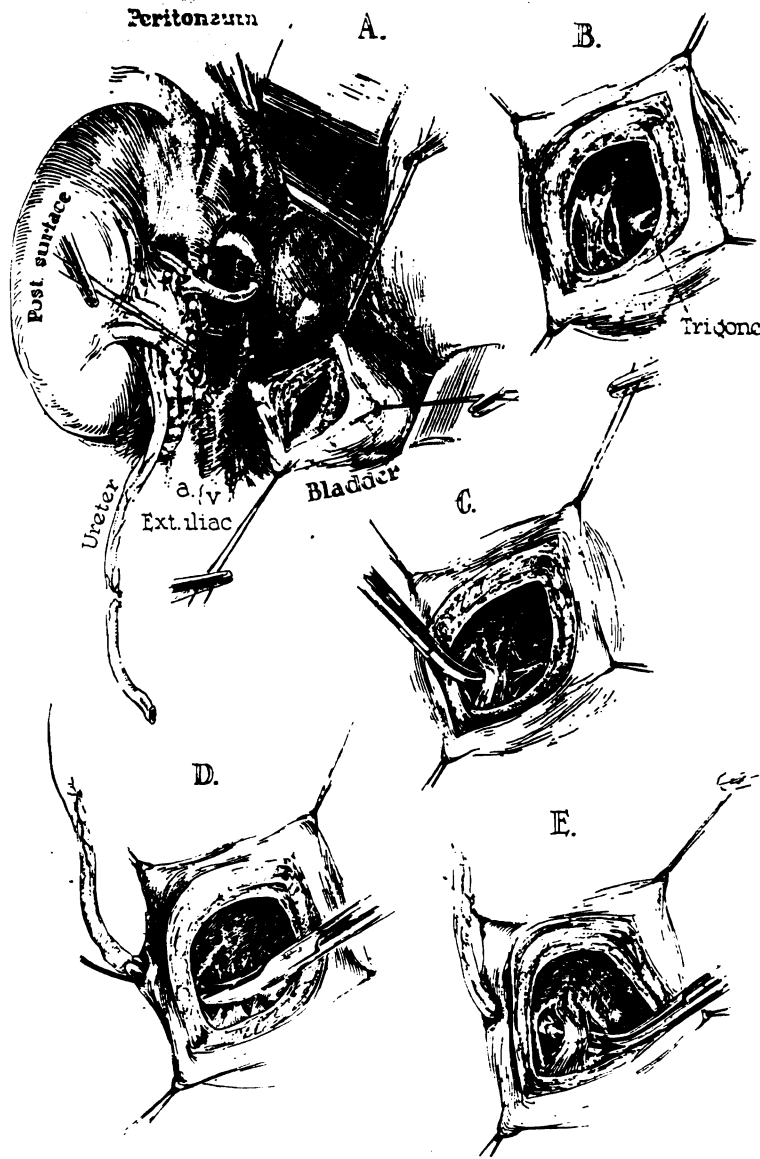


Fig 10.—Ureteroneocystostomy. A, bladder cystostomy performed. B, beginning of creation of the submucosal tunnel by performance of two mucosal incisions. Note proximity of lower incision to trigone. C, completion of tunnel with blunt hemostat dissection; D, the ureter is pulled through the bladder wall at an angle so that an additional tunnel effect is created. E, extraction of the intravesicle ureter through the preformed submucosal tunnel.

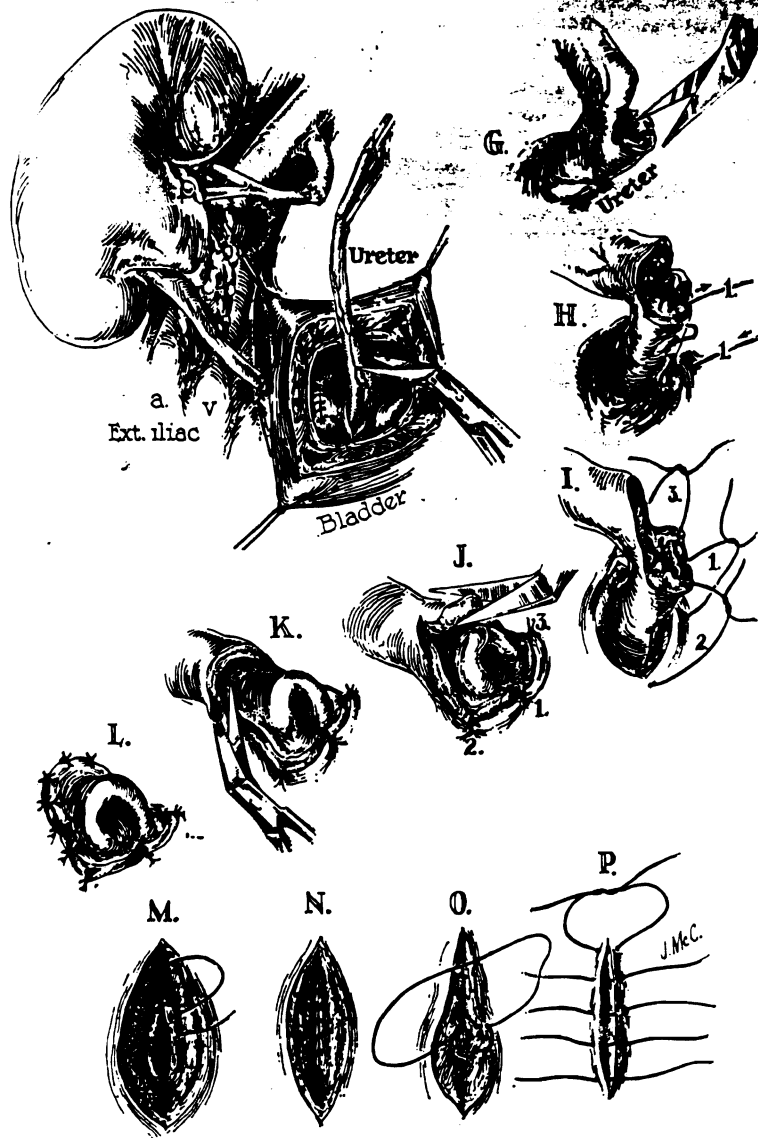
tissue injury incurred during the rejection crisis. The homograft was removed.

Genitourinary Hemorrhage: Serious hemorrhage was encountered from the lower urinary tract in four of the 42 cases (Table 3). In each case, the hemorrhage began a few hours after operation after an early period of relatively clear urinary excretion. Once initiated, the tempo of the hemorrhage increased progressively until transfusions were required in two cases. In each instance, the urethral catheter was removed, and the hemorrhage ceased within minutes. In sub-

sequent cases, it was noted at the time of operation that the area of the trigone had sometimes developed a beefy red area of hemorrhagic cystitis near contact with the Foley catheter. This finding, combined with the observation that removal of the catheter resulted in cessation of bleeding, has made it appear likely that such a focus of hemorrhagic cystitis was responsible for this disquieting complication.

Ileus: In 36 of the 42 cases, it was possible to remove the gastric tube and resume alimentation within 24 hours after operation.

Fig 11.—Ureterocystostomy (continued). *F*, the upper mucosal incision has been closed and the ureteral length decided upon. Note that the vascular bundle of the ureter has been ligated. *G*, the ureter has been hemitranssected and a fish-mouth is being created. Note that the latter cut is made at the most recessed and inaccessible portion of the ureter. *H*, a 5-0 or 6-0 catgut suture is placed from the bladder mucosa to the ureteral adventitia and to the apex of the fish-mouth incision. *I*, placement of similar corner sutures catching the tips of the fish-mouth flaps; *J*, the three anchoring sutures have been tied and a flap of ureteral mucosa is fashioned for the ultimate formation of a hood. *K*, continuation of flap incision; *L*, the eccentric flap is completed and sutured in place. *M-P*, bladder closure; note that the inner two layers are of continuous catgut, insuring a water-tight closure. The external layer is of interrupted black silk.



Incision in bladder closed

In the other six, gastric suction was required for two to eight days (Table 3). During this time, therapy with azathioprine was provided with an intravenous solution,¹⁷ and steroid therapy was given, if required, with intramuscular prednisolone. Two patients had operation for intestinal obstruction, 29 and 32 days after transplantation, both requiring adhesiolysis.

Thromboembolic Complications: Nine patients had clinical evidence of thrombophlebitis during convalescence, and in five of

these, the presence of one or more pulmonary emboli was proved either at the time of pulmonary embolectomy or at autopsy. Pulmonary embolization was not the direct cause of death in any of these five patients, and it was recognized clinically in only two instances. In two of the nine patients, heparin therapy was begun but had to be discontinued because of serious hematuria.

Gastrointestinal Hemorrhage: The immunosuppressive regimen employed involves the almost invariable use of large doses of

TABLE 2.—Effect of Duration of Ischemia on Function in 44 Homografts

	Less Than 30 Min			
	No	Mean	SD	SE
1. Time urine onset (min)	24	33.7	36.9	7.6
2. Diuresis/hr for first 12 hr, ml	24	511	275.0	56
3. Preop BUN, mg %	24	71.2	23.7	4.8
4. Lowest BUN within 2 days, mg %	22	24.5	14.3	3.0
5. Highest Cr, ml/min with- 2 days	22	97.9	36.2	7.7
	31 to 43 Min			
1. Time urine onset, min	17	30.7	34.2	8.3
2. Diuresis/hr for first 12 hr, ml	17	393	183	47
3. Preop BUN, mg %	17	97.9	49.4	11.9
4. Lowest BUN within 2 days, mg %	17	38.4	27.7	6.7
5. Highest Cr, ml/min with- in 2 days	15	53.4	21.6	5.6

Sixty-one, 71, and 84 minutes (3 cases) (see text). Cr indicates creatinine clearance.

TABLE 3.—Noninfectious Complications in First 42 Cases

Urinary fistula	2
Testicular necrosis	1
Bladder hemorrhage	4
Renal hemorrhage (on heparin Rx)	2
Paralytic ileus	6
Intestinal obstruction	2
Operative cardiac arrest	1
Thrombophlebitis	9
with pulmonary emboli	6 (5 proved)
without pulmonary emboli	3
Diabetes mellitus	13
Pancreatitis	5
Hepatitis	2
Gastrointestinal hemorrhage	7
Coronary occlusion	1
Aseptic bone necrosis	1
Neurologic complications	
Neuropathy and/or myopathy	18*
Coma	3
Convulsions	4
Stroke	1
Brain abscess	3
Psychosis	4
Arthralgia	5

* The complication was present before operation in all 18 patients.

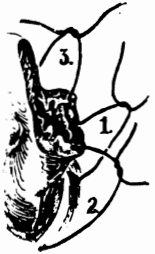
prednisone at some time during the post-operative period in order to reverse a rejection crisis. During maximum steroid therapy, 80% of the patients developed guaiac positive stools. In seven cases (Table 3), the hemorrhage was of sufficient magnitude to require transfusions. The most massive bleeding occurred in a 46-year-old man who required eight units of blood in one 12-hour period. The hemorrhage ceased abruptly just as he was being transferred to the operating room. Unfortunately, he sustained a coronary occlusion during this time, with eventual recovery. Another patient died six months and 23 days post-transplantation, ten days after suture ligation of a bleeding duodenal ulcer, combined with pyloroplasty and vagotomy. At autopsy, multiple fungal brain abscesses were also found.

Pancreatic Complications: All patients treated with prednisone developed some evidence of steroid-induced diabetes mellitus. The tendency to hyperglycemia or glycosuria was progressive, usually requiring several weeks to develop. In the most severe examples polydipsia, polyuria, weight loss, acidosis, and ketosis were present. In the majority of cases, therapy with insulin was not necessary, and the alterations in carbo-

hydrate metabolism were quickly reversed as the steroid doses were subsequently reduced. In 13 instances, however, the diabetes was severe and required the institution of a program of active management (Table 3). As much as 120 units daily of isophane insulin suspension was administered, although the usual maintenance doses were 30 to 50 units per day. In all but two cases, the need for insulin was eliminated when the quantity of prednisone was dropped to less than 30 mg per day. In these two exceptional patients, who were possibly latent diabetics to begin with, there has been a continued need for insulin despite reduction of prednisone to 5 and 15 mg per day respectively.

Five patients developed biochemical evidence of pancreatitis (Table 3), and in three of these the diagnosis was confirmed at autopsy. In one case,⁴ this complication, which can be induced with steroids in man¹⁸ or experimental animals,¹⁹ was the only post-mortem explanation for death (Fig 12).

Neurologic Complications: The most frequent of all complications involved the central or peripheral nervous systems (Table 3), the neurologic disability frequently



re pulmonary
e time of pul-
autopsy. Pul-
e direct cause
patients, and it
only two in-
ents, heparin
discontinued

re: The im-
oyed involves
arge doses of

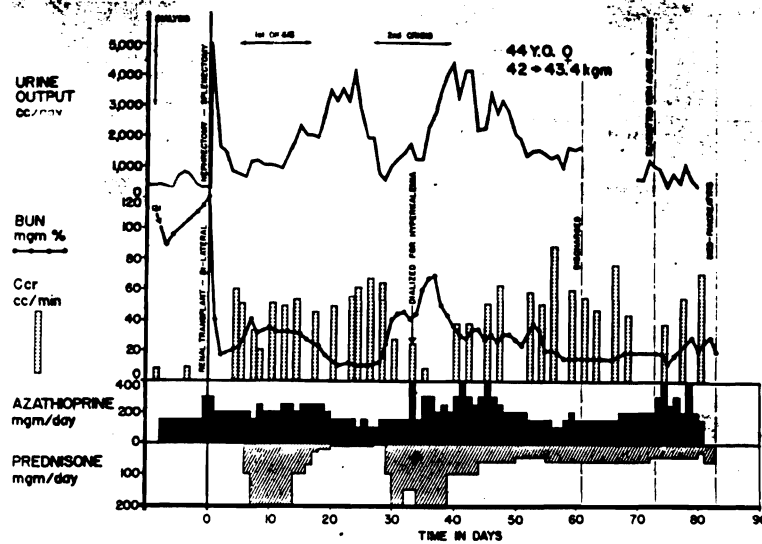


Fig 12.—Course of a 44-year-old woman who died of acute and chronic pancreatitis 83 days after homotransplantation. Prednisone schedule was unusually protracted because of two rejection episodes. The pancreatitis was thought to have been steroid induced.

originating in the preoperative period. Advanced neuropathy or myopathy, which were much more common in older patients, proved to be bad prognostic omens. If such changes were severe enough to prevent effective ambulation during the postoperative period, prolonged survival was not attained in a single case. Such bedridden patients frequently developed decubiti, could not eat well, and were unusually susceptible to drug toxicity.

The relative irreversibility of uremic neuropathy is of interest. Two patients with relatively advanced foot drop have now been followed for 7 and 13 months with almost no improvement. The correction of the original metabolic abnormalities cannot, therefore, restore the neurologically crippled patient to a state of health in the case of advanced neuropathy.

Acute neuropsychiatric disorders such as convulsions, behavioral disorders, or coma occurred both in the pre- and postoperative periods (Table 3), and these did not have a grave prognostic significance except when the underlying cause was brain abscess (three cases) or a massive stroke (one case). In two patients with postoperative convulsions, the seizures occurred during the acute post-transplant diuresis, and were probably due to rapid shifts in body water composition.

Miscellaneous: One patient had a cardiac arrest during transplantation and died ten

days later. Another developed testicular necrosis postoperatively, necessitating orchiectomy. There were two cases of nonfatal hepatitis. Five patients developed postoperative arthralgia which seemed to be related to the use of antihypertensive drugs. One patient had aseptic necrosis of the first lumbar vertebra, necessitating operation for spinal fusion.

Infectious Wound Complications. Failure of primary healing of a wound or subsequent dehiscence, following initial skin healing, occurred at 14 sites in ten patients (Table 4). *Staphylococcus aureus*, coagulase positive, was involved in nine instances and was accompanied by other pathogens in only one.

TABLE 4.—Clinical Wound Infections in 42 Patients

	Controlled	Uncontrolled
Transplant wound		
Superficial	5	0
Deep	1	1
Thymectomy wound		
Superficial	1	0
Deep	1	1
Splenectomy-Nephrectomy		
Superficial	3	0
Deep	0	0
Other wounds (deep)		
Cardiac arrest, thoracotomy wound	1	1
Previous flank nephrectomy	1	1
Intestinal obstruction	1	1
Total	14	5

RENAL HOMOTRANSPLANTATION

In three wounds in which only *S. albus*, coagulase negative, was isolated, the delayed wound closure was primarily the result of hematoma formation. Further, this same situation undoubtedly obtained in the two other wounds in which cultures, taken prior to antibiotic therapy, remained sterile.

The significance of the extent of wound involvement is apparent from the fact that the four patients who had five deep wound abscesses eventually died from failure to control these infections. In contrast, all superficial infections responded promptly to local drainage and systemic antibiotic therapy. More inclusive epidemiologic studies, details of infections other than those found in surgical wounds, and a description of antibiotic management and infectious disease care have recently been published by Rifkind.^{20,21}

Comment

Certain complications which have been observed are not unique to renal homotransplantation, but they appear to occur with a much higher frequency in this than in other major surgical procedures. The operation itself and the therapy necessary to achieve chronic function of the homograft impose an increased danger in several pathophysiologic areas.

The cyclic course which follows renal homotransplantation has been fully described elsewhere.^{4,17,22} Briefly, a technically successful operation is followed by a temporary period of good renal function and restoration of well-being. At a varying interval postoperatively, ranging from 1 to 40 days, it has almost invariably been necessary to pass through a rejection crisis, at which time the homograft is threatened with repudiation. The acute illness which occurs at this time, with fever and with evidence of acute functional deterioration of the homograft, can usually be reversed with the addition of massive doses of steroids and actinomycin C to the regimen of azathioprine already in use. Many of the complications which have had their inception at this critical time are probably related to the presence in the retro-

peritoneal space of foreign tissue, which is under immunologic assault, as well as to the pharmacologic agents which must be used in high doses at this time.

For example, the high incidence of gastrointestinal bleeding was closely related temporally to the rejection crisis. At least two ulcerogenic mechanisms are present at this time. One results from the administration of large doses of prednisone, a drug which is necessary for control and reversal of the rejection process, but which is also a well-known cause of acute gastrointestinal ulceration. In addition, the secondary uremia which occurs temporarily during this phase of recovery may be an important contributory factor. Fortunately, the gastrointestinal bleeding was controllable in all but one case with conservative measures. In the patient requiring gastric surgery, bleeding was first noted early in the postoperative period, although operation was not ultimately required until six months after transplantation.

In addition to gastrointestinal hemorrhage, other complications are attributable either directly or indirectly to the temporary high dose prednisone therapy. These include the development of moon facies and abnormal fat distribution, steroid-induced diabetes mellitus, osteoporosis or aseptic bone necrosis,²³ and pancreatitis.^{18,19} One patient (Fig 12), who died of pancreatitis 83 days after operation, had passed through two rejection episodes and had good renal function until the day of death.

The high incidence of thrombotic complications is also of interest. Virtually all the recipients were in the terminal phase of uremia at the time of first consideration of homotransplantation. Their degree of muscle wasting, debility, and inactivity was usually extreme. During the early postoperative period, accentuation of weight loss was frequently seen, some patients losing as much as 50 or 60 lb (22.7 or 27.2 kg). Such patients would be expected to have a heightened incidence of thrombophlebitis, after any surgical operation.

With renal transplantation, specific dangers are added. There is the necessity for

2.—Course of a old woman who acute and chronic tis 83 days after nsplantation. ne schedule was protracted be- two rejection The pancreatitis ght to have been duced.

testicular ne- tating orchiec- s of nonfatal ned postopera- o be related to rugs. One pa- he first lumbar ion for spinal

tions. Failure or subsequent in healing, oc- ts (Table 4). lase positive, s and was ac- s in only one.

ns in 42 Patients

Controlled	Uncontrolled
0	0
1	1
0	0
1	1
0	0
0	0
1	1
1	1
1	1
8	8

direct manipulation and anastomosis of the external iliac vein. Postoperatively, there are major changes in body fluid composition during the diuretic phase, with a sudden relative dehydration. Finally, the use of the adjuvant procedure, splenectomy, is known to cause thrombocytosis and may accentuate a clotting tendency.

In the care of patients with renal transplantation, the control of infectious disease constitutes a special problem which has been analyzed in detail in other publications.^{4,20,21} Lethal infections were involved in more than 80% of the failures encountered in the first 45 cases, septicemia and pneumonia accounting for most of the septic complications.⁴ It is encouraging to note, however, that an uncontrollable infection in either the splenectomy-nephrectomy or transplant wounds occurred on only one occasion in the presently reported series, and that superficial infections could be effectively treated.

Nevertheless, the risk of wound sepsis is predictably increased by the relative immunoparalysis necessary to prevent homograft rejection. If healing is to be expected, it is mandatory that all wounds be clean and biologically sealed by the time of the rejection crisis. It is toward this end that many of the technical features of the operation are directed. In order to prevent retrograde bacterial contamination, no drains or cystostomies are employed, and even the use of indwelling urethral catheters is limited to the first few postoperative hours. Vigorous antibiotic therapy is instituted before or after operation on the basis of specific culture data in order to eradicate foci of pathogenic bacteria before it becomes necessary to embark on the excessive pharmacologic regimen required for reversal of rejection. The use of a one-stage procedure makes it unnecessary to impose further operative trauma upon the patient during this phase of recovery.

In an undertaking as inherently hazardous as renal homotransplantation, the need to obtain good immediate homograft function is obvious. In the present study, an effort was made to define the spectrum of renal ischemia

within which this objective could be consistently met. Even when the period of devascularization was reasonably short, there appeared to be a correlation between the quality of function and the time required for transfer of the homograft. These findings emphasize the need to develop facility in performance of vascular anastomoses before attempting clinical homotransplantation procedures. The data support the view that predictably good function can be obtained if the period of ischemia can be kept to less than 40 minutes, but they also suggest that even within this interval early excretory capacity is roughly related to the time expended in revascularization.

Before accepting 40 minutes as a permissible time of renal ischemia, it must be emphasized again that some form of homograft hypothermia was invariably applied in the series from which this figure was derived. It is probable that inconsistent results would follow even shorter ischemic periods under normothermic conditions.

In the final analysis of the reasons for success or failure of renal homotransplantation, there is often an urge to ascribe failure to poor control of rejection. It is important to suggest that there may be a significant interrelationship between the ease with which this process can be managed and the degree of anoxic injury inflicted upon the transplanted kidney. The clarity with which complications can be tabulated as technical or nontechnical may not be as great as with other kinds of surgery. Without question, many homotransplantation procedures have failed as the result of rejection in which a complex chain of events was initiated and rendered unmanageable by the use of less than optimal homografts. Acceptance of these failures as essentially nontechnical may not be justified.

Summary

Purely technical considerations play a significant role in successful renal homotransplantation. Minimization of homograft ischemia is critical. If blood supply to the

ould be consist-
 eriod of devas-
 7 short, there
 n between the
 ne required for
 These findings
 lop facility in
 tomoses before
 plantation pro-
 the view that
 an be obtained
 be kept to less
 so suggest that
 y excretory ca-
 the time ex-

es as a permis-
 it must be em-
 n of homograft
 applied in the
 e was derived.
 t results would
 periods under

he reasons for
 motransplanta-
 ascribe failure
 It is important
 e a significant
 ease with which
 and the degree
 on the trans-
 ith which com-
 as technical or
 great as with
 hout question,
 ocedures have
 on in which a
 s initiated and
 he use of less
 Acceptance of
 ntechnical may

ations play a
 renal homo-
 of homograft
 supply to the

l 89, July, 1964

cooled homograft can be restored within 40 minutes, prompt urinary excretion can be expected to follow. Longer periods of devascularization result in inconsistent early function. Even with ischemic intervals of less than 40 minutes, there is an inverse correlation between the times necessary for vascular reconstruction and the quality of early renal function.

Additional important technical factors involve the site of placement of the homograft, provision for unknicked vascular channels, selection of a method of ureteroneocystostomy which permits early removal of the urethral catheter, avoidance of all drains, and use of a one-stage operation incorporating bilateral nephrectomy and splenectomy in addition to the homotransplantation. The methods by which these objectives are met are described in detail.

Certain postoperative complications which have been observed are not unique to renal homotransplantation, but they appear to occur with a much higher frequency in this than in other major surgical procedures. These include infections, gastrointestinal hemorrhage, diabetes mellitus, pancreatitis, thromboembolism, and neurologic disorders. The high incidence of such complications appears to be due to the high dose immunosuppressive therapy necessary to maintain viability of the homograft during the rejection crisis, to the terminal uremia from which all patients are suffering at the time of operation, and to specific elements of the total operative care such as splenectomy and instrumentation of the pelvic veins.

Thomas E. Starzl, MD, Department of Surgery, University of Colorado Medical Center, Denver, Colo 80220.

Generic and Trade Names of Drugs

- Neomycin—Mycifradin, Myciguient, Neomycin.
- Bacitracin—Baciguient, Bacitracin.
- Heparin sodium—Heparin sodium, Liquaemin sodium.
- Azathioprine—Imuran.
- Prednisolone—Delta Cortef, Hydeltra, Meticortelone, Meti-Derm, Paracortol, Sterane, Sterolone.
- Prednisone—Deltasone, Deltra, Meticorten, Paracort.

Starzl et al

Isophane insulin suspension—NPH Insulin.
 Insulin.

Addendum

May 15, 1964.—Twenty-three of the 24 patients who were alive in February are still living, all now 6 to 18 months postoperative. All are residing at home. The single additional death occurred 295 days after homotransplantation as a consequence of late rejection.

REFERENCES

1. Marchioro, T. L., et al: Use of Extracorporeal Perfusion for Obtaining Postmortem Homografts, *Surgery* 54:900, 1963.
2. Starzl, T. E., et al: Renal Transplantation in Identical Twins, *Arch Surg* 86:600, 1963.
3. Marchioro, T. L., et al: Use of Living Donors for Renal Homotransplantation, *Arch Surg* 8:711-720, 1964.
4. Starzl, T. E., et al: Factors in Successful Renal Transplantation, *Surgery*, to be published.
5. Starzl, T. E., et al: Splenectomy and Thymectomy in Human Renal Homotransplantation, *Proc Soc Exp Biol Med* 113:929, 1963.
6. Starzl, T. E., et al: Technique for Use of Adult Renal Homografts in Children, *Surg Gynec Obstet*, to be published.
7. Küss, R.; Teinturier, J.; and Milliez, P.: Some Notes on Renal Homotransplantation in Man, *Mem Acad Chir (Paris)* 77:755, 1951.
8. Murray, J. E., and Harrison, J. H.: Management of 50 Patients With Kidney Transplants Including 18 Pairs of Twins, *Amer J Surg* 105:205, 1963.
9. Hume, D. H., et al: Renal Homotransplantation in Man in Modified Recipients, *Ann Surg* 158:608, 1963.
10. Starzl, T. E.: *Transplantation of the Kidney*, Philadelphia: W. B. Saunders Co, 1964.
11. Brown, L.: Vascular Clamp Utilizing Sponge Rubber, *Arch Surg* 83:645, 1961.
12. Paquin, A. J.: Ureterovesical Anastomosis: Description and Evaluation of Technique, *J Urol* 82:573, 1959.
13. Starzl, T. E., et al: Renal Homografts in Patients With Major Donor-Recipient Blood Group Incompatibilities, *Surgery* 55:195, 1964.
14. Starzl, T. E., et al: Incidence, Cause and Significance of Immediate and Delayed Oliguria or Anuria After Human Renal Transplantation, *Surg Gynec Obstet* 118:819, 1964.
15. Marchioro, T. L., et al: Pulmonary Embolectomy in Patient With Recent Renal Homotransplantation, *Surgery* 55:505, 1964.
16. Spencer, F. C., et al: Plication of Inferior Vena Cava for Pulmonary Embolism: Report of 20 Cases, *Ann Surg* 155:825, 1962.

17. Starzl, T. E., et al: Problems in Renal Homotransplantation, JAMA 187:734, 1964.

18. Carone, F. A., and Liebow, A. A.: Acute Pancreatic Lesions in Patients Treated With ACTH and Adrenal Corticoids, New Eng J Med 257:690, 1957.

19. Bencosme, S. A., and Lazarus, S. S.: Pancreas of Cortisone-Treated Rabbits, AMA Arch Path 62: 285, 1956.

20. Rifkind, D., et al: Infectious Diseases Associated With Renal Homotransplantation: I. Incidence, Types and Predisposing Factors, JAMA, to be published.

21. Rifkind, D., et al: Infectious Diseases Associated With Renal Homotransplantation: II. Differential Diagnosis and Management, JAMA, to be published.

22. Starzl, T. E.; Marchioro, T. L.; and Waddell, W. R.: Reversal of Rejection in Human Renal Homografts With Subsequent Development of Homograft Tolerance, Surg Gynec Obstet 117:659, 1963.

23. Boksenbaum, M., and Mendelson, C. G.: Aseptic Necrosis of Femoral Head Associated With Steroid Therapy, JAMA 184:262, 1963.

DISCUSSION

CLAUDE R. HITCHCOCK, MD, Minneapolis: During recent months my colleagues and I have increasingly appreciated the outstanding and monumental contributions of Dr. Starzl and his group to the overall field of homografting. I believe they have moved the whole program along to a new level of accomplishment within the short span of 18 months.

It is well known that the terminal uremic patient is a very poor operative risk and that hemorrhagic diatheses, for example, are frequently frightening. Dr. Starzl and his colleagues have blazed a trail of technical surgical excellence that is an inspiration to all surgeons. This has been exemplified for us strongly of late as our two teams have joined forces to collaborate in a joint study for heterografting baboon kidneys into humans.

An initial group of six patients has been operated on. Each patient has had a strong compelling reason why a heterograft should be tried; commonly a suitable donor was not available. The technical aspects of these operations are of great importance. While it is difficult to homograft kidneys successfully in the human, I assure you it is even more difficult to heterograft with the smaller size organs from subhuman primates. The ureters of the subhuman primate are particularly difficult to implant into the recipient's bladder. Our groups have learned several important things and we would like to pass them on to you at this time.

While blood grouping, as has been shown in Dr. Starzl's laboratory and in his clinic, is very im-

portant in homografting, it appears to be equally important in heterografting. The baboon has weak red cell antigens, however, and this animal's kidneys may ultimately be more readily accepted than those from some other subhuman primates with more potent antigens as demonstrated by present techniques.

However, with familiarity with the subhuman primate which you are going to use (in this case, the baboon), and with careful control of the animal's health, and with proper anesthesia and management during surgery, and with perfection in all technical details of the organ harvesting and of the recipient surgery, we now can say that the immediate rejection of these heterografted tissues from the baboon can be controlled.

It is a singular fact that, even in those three of our six cases where a deliberate mismatch of the blood groups was performed, immediate success was achieved. The organs took and functioned although we have lost several of these patients up to this time.

We now believe the crucial problem revolves around prolonged control of the rejection reaction, with particular reference to the exceptionally heavy therapeutic artillery that is necessary to provide the immunosuppressive effect.

The drugs azathioprine and prednisone, and later regional x-ray to the kidney itself, seem to work well, but the dosages must be high and the patient does pay the price of greatly suppressed immune response on a broad scale. Slow and insidious rejection is still a real and perplexing problem.

At this time, our two groups wish to advise prudence and caution regarding heterografts into humans. Following the pattern for homografting, as popularized by the Denver group, homografts can become increasingly successful especially when ischemia time is reduced by using good-quality living donors.

We believe we have a moral obligation to our patients to advise homografting whenever possible; this is as we see the problem today. At this point in time, we wish to emphasize that for homografting the road is treacherous, but success is improving; for heterografting the pitfalls are many but the potential is great, and the future of heterografting beckons with hope and rich rewards for many patients needing organ replacement of several kinds.

THOMAS E. STARZL, MD, Denver: I would like to thank Dr. Hitchcock for his discussion and state our feeling even more strongly. We are not planning to do any more heterografts.

Despite this, the heterografts, in view of what might have been expected from an historical point of view, have done extraordinarily well. There may be some indirect social consequences in which we humans may have to reevaluate our own exalted view of our phylogenetic status.