

## RENAL HETEROTRANSPLANTATION FROM BABOON TO MAN: EXPERIENCE WITH 6 CASES<sup>1</sup>

T. E. STARZL,<sup>2</sup> T. L. MARCHIORO, G. N. PETERS, C. H. KIRKPATRICK,<sup>3</sup>  
W. E. C. WILSON,<sup>4</sup> K. A. PORTER, D. RIFKIND, D. A. OGDEN, C. R. HITCHCOCK,  
W. R. WADDELL

*Departments of Surgery and Medicine, University of Colorado School of Medicine  
and Denver Veterans Administration Hospital, Denver; Department of  
Pathology, St. Mary's Hospital Medical School, London; and  
Department of Surgery, Hennepin County General  
Hospital, Minneapolis*

### SUMMARY

Six patients with terminal uremia due to glomerulonephritis or pyelonephritis were treated with heterografts from East African baboons. Immunosuppressive therapy was provided both before and after operation with azathioprine and prednisone and postoperatively local transplant irradiation and actinomycin C were administered intermittently. The individual rejection episodes in the post-transplant period could be reversed relatively easily but these recurred vigorously and repetitively, making it impossible to relax the stringent requirements of antirejection therapy. The continued need for high-dose immunosuppressive therapy precipitated lethal infections in the majority of cases.

The patients lived for 19 to 98 days after heterotransplantation. Four died with the baboon kidneys still in place after 19, 23, 35, and 49 days. In the other two cases the heterografts were removed after 60 and 49 days respectively, at a time when urine excretion was still present, and homografts from volunteer convict donors were placed on the opposite side. Both the latter recipients died of septic complications following the second operation, after 39 and 44 days. Complete cessation of heterograft urine excretion appeared only in two cases, although renal function was failing in the remainder prior to death or before removal of the heterografts. The relation of renal function to changes in heteroagglutinin and hemagglutinin titers is described.

After residence in the host for 19 to 60 days, all the heterotransplants were heavily infiltrated with plasma cells and large lymphoid cells with pyroninophilic cytoplasm. There was also disruption of peritubular capillaries, interstitial edema, widespread tubular damage, swelling of endothelial cells lining arterioles, fibrinoid necrosis of the walls of arterioles and interlobular arteries, and narrowing and obstruction of interlobular arteries by fibrin and platelet deposits on the

---

<sup>1</sup> Aided by Grants A-6283, A 6344, HE 07735, AM 07772, AI 01452 and FR-0005 from the USPHS, by a Grant in Aid from the Western Foundation, Minneapolis, Minnesota, and by a grant from the Medical Research Council of Great Britain.

<sup>2</sup> Markle Scholar.

<sup>3</sup> Special post-doctoral Fellow, United States Public Health Service.

<sup>4</sup> Research Fellow of the American College of Physicians, 1962-1965.

intima. The pre-glomerular vascular lesions were accompanied by focal infarcts and extensive interstitial hemorrhages. All the pathologic changes were more severe than those seen by Reemtsma in a comparable series of chimpanzee-to-man heterotransplants, where cellular infiltration was slight and vascular lesions uncommon in the presence of major blood group incompatibility between donor and recipient.

During the developmental era of vascular surgery, five clinical renal heterotransplantations are known to have been tried, each with a different type of animal donor (4, 7, 16, 19). Significant renal function was not obtained in any instance, and the longest survival was 9 days. No additional attempts at heterotransplantation were made in the ensuing 40 years, and the tacit assumption became firmly entrenched that such avenues of investigation presented insurmountable biologic difficulties.

In 1963, Reemtsma (12, 14)<sup>5</sup> and Hitchcock (2) and their associates re-examined the possibility that heterograft function could be obtained and sustained with the aid of various immunosuppressive agents. It was established that immediate urine excretion of chimpanzee (12-14), rhesus monkey (12), and baboon kidneys (2) followed after transplantation to the human, and that maintenance of relatively protracted chimpanzee heterograft function could be expected at least in the occasional case<sup>5</sup>.

The present study is an account of a clinical study of renal heterotransplantation carried out at the University of Colorado Medical Center in December, 1963, and January, 1964, using baboons for donors. By comparison of the results with those previously obtained with homotransplantation (17) it was hoped to define the differences and similarities of homograft and heterograft behavior in the human host. In addition, it became possible as the result of an exchange of functional and pathologic data with Reemtsma<sup>5</sup> to arrive at tentative conclusions concerning the biologic suitability for human heterograft donation of different subhuman primates.

#### METHODS

*Case material.* Features of the recipient patients are shown in Table 1. Suitable familial donors were not available in any case. For all six patients, cadaveric kidneys were unsuccessfully sought during the period of preoperative observation, in one case for as long as 2 months. All patients were in the terminal phase of their disease. The blood types of the patients and their donors are listed in Table 2.

*Baboon donors.* Two East African female and four male baboons (*Papio doguera*) were used,<sup>5</sup> weighing 15.7 to 24.8 kg (Table 1). Of special interest were previous studies done by Doctor S. S. Kalter on the entire Southwest Foundation baboon population (5). An occasional animal had evidence of previous exposure to enteroviruses, arboviruses and respiratory viruses. Kalter

<sup>5</sup> Obtained from the Southwest Foundation for Research and Education, San Antonio, Texas. Studies were carried out for the detection of pathogenic bacteria, parasites, fungi and viruses. At subsequent autopsy, the only abnormality in any animal (that used for Case 1) was an encapsulated intrahepatic pocket of *Hepaticystis kochii* (malaria) in megaloschizont form.

TABLE 1  
*Recipient patients. All were male.*

Case	Wt.	Age	Wt.-Sex of donor	Renal disease <sup>a</sup>
1	61.6 kg	40	20.9 kg male	CGN
2	62 kg	46	17.3 kg male	CGN
3	47.2 kg	17	16.4 kg male	CGN
4	53.6 kg	18	24.8 kg male	CGN
5	46.3 kg	35	15.7 kg female	Pyeloneph
6	69.8 kg	35	16.4 kg female	CGN

<sup>a</sup> CGN—Chronic glomerulonephritis.

TABLE 2  
*Function and survival of heterografts, and relation to blood group matching*

Case	Ischemia	Donor blood type	Recipient blood type	First urine	Duration urine excretion	Survival with heterograft in place
1	Rt-29 min Lt-37 min	A	A+	4.5 min	23 days	23 days
2	44 min	B	O-	10 min	25 days	35 days
3	34.5 min	B	AB+	8 min	60 days	60 days <sup>a</sup>
4	29 min	B	B+	90 min	49 days	49 days <sup>a</sup>
5	27.5 min	AB	O-	8 min	10 days	19 days
6	37 min	AB	O+	90 min	49 days	49 days

<sup>a</sup> Heterografts removed. Homografts placed.

found that only a small percentage of the animals had serologic evidence of prior exposure to the B virus, an important observation since the human disease caused by this agent is invariably fatal. Twenty percent of the baboons had antibodies to Q fever antigen.

*Baboon donor operations.* Hypothermia of 28–30 C was employed. The heterografts were removed transabdominally through a complete midline incision, reflecting the ascending and descending colon off the respective kidneys. In Case 1, each organ was removed individually, small ellipses of aortic wall being included with the specimens in order to facilitate the arterial anastomoses in the recipient. The heterografts were each perfused with the cold, low molecular weight dextran to be described below.

For Cases 2–6, Reemtsma's method was used (13), removing the skeletonized aorta and vena cava in continuity with the renal vessels, kidneys, and ureters, avoiding dissection in the central hilar areas. Just before removal, a cannula was inserted proximally into the aorta through the common iliac artery and perfusion commenced at a pressure of 70–120 mm Hg with cold (10–15 C) 10% low molecular weight dextran<sup>6</sup> in normal saline to which 50 mg heparin and 1 gm procaine chloride per liter had been added. The entire vascular complex was immediately excluded from the general circulation by appropriate placement of clamps allowing egress of the perfusate through the transected upper

<sup>6</sup> Supplied as Rheomacrodex by Pharmacia Laboratories, Inc., New York, New York.

vena cava. Approximately 250 ml solution were used in each instance. The kidneys and attached vessels were then removed, oriented in a flat pan, immobilized to prevent twisting during transit, and delivered to the recipient room.

*Recipient operations.* In all cases, splenectomy and bilateral nephrectomy were performed transperitoneally through a separate upper midline incision. The homografts were placed retroperitoneally through an oblique lower abdominal incision. In Case 1, the individual kidneys were placed in the contralateral recipient retroperitoneal spaces with end-to-side vascular anastomoses to the external iliac artery and vein. In Cases 2-6, the heterograft complex was placed in a right extraperitoneal space (13) and revascularized through the distal donor aorta and inferior vena cava (Fig. 1), folding the posterior surfaces of the organs together in order to occupy less space (Fig. 1). In all

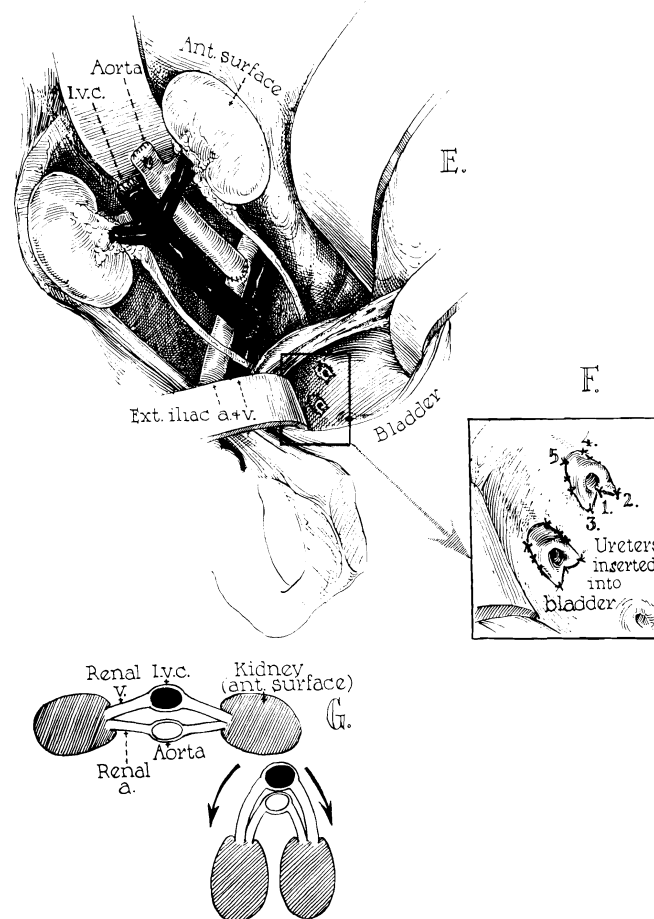


FIGURE 1. Insertion of heterografts after technique of Reemtsma. E. Anastomosis of distal aorta and vena cava to external iliac vessels. F. Parallel ureteroneocystostomies. G. Folding back of kidneys in order to occupy less space.

cases, the ureters were implanted by a modification (17) of the Paquin-Marshall technique (8), placing the ureteroneocystostomies approximately 1 cm apart in Cases 2-6 (Fig. 1E). The ischemic intervals are indicated in Table 2. Drains were not used.

*Postoperative care.* During the acute diuretic phase, which lasted 24 to 48 hr, urine volumes were 70% replaced with 5% G/0.45% saline and with lactated Ringer's solution to which small amounts of potassium chloride (4 to 12 mEq/liter) were added in Cases 2, 5, and 6. Alimentation, which consisted of a low salt, high caloric diet was resumed within 48 hours in each instance. The urethral catheters were removed after 12 to 24 hours. After confinement to bed for 2 days, the patients were allowed to leave the hospital during the daylight hours. A semisterile reverse isolation procedure was maintained for the in-hospital intervals. Preventive antibiotics were administered, based upon multiple culture data.

*Immunosuppressive therapy.* The therapy used for all cases was similar to that shown in Figures 2 to 4. Azathioprine was started 7 to 10 days preoperatively, and 150-200 mg/day prednisone (divided into 6 hourly doses) later

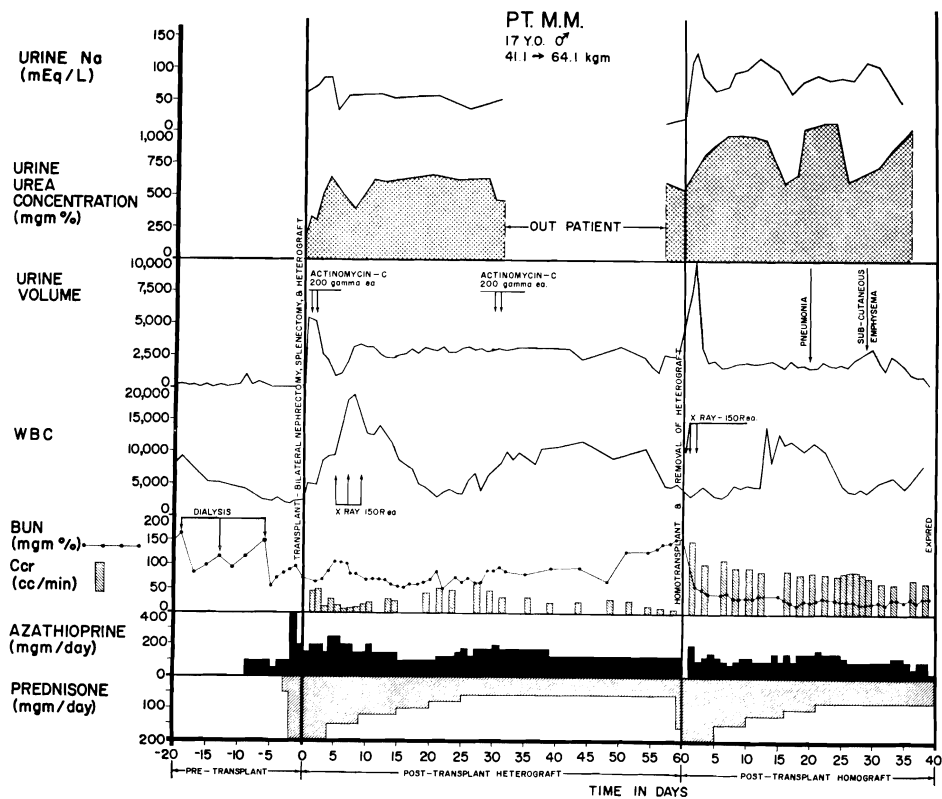


FIGURE 2. Case 3. Recipient was AB+ blood group, and donor was B. The patient was anuric preoperatively. The difference in quality of function with the heterografts, compared to the secondarily placed homograft, is evident. Heterotransplant rejection crises occurred after 5 and 50 days. Urine function continued until heterografts were removed.

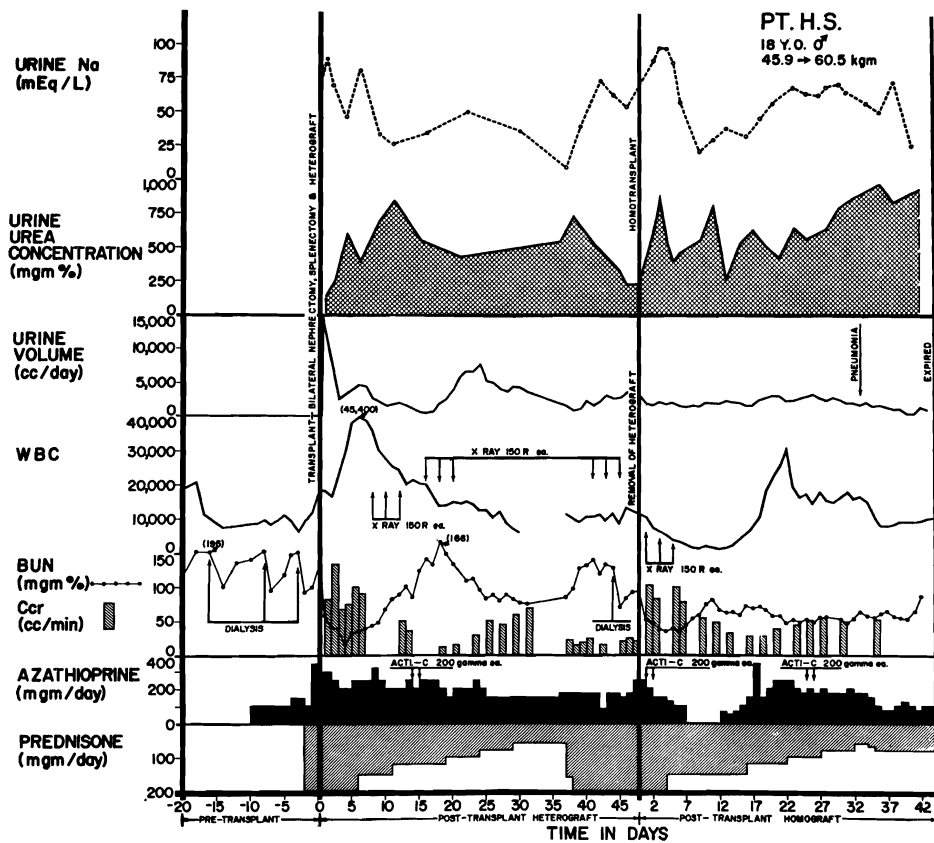


FIGURE 3. Case 4. Course after heterotransplantation (left) and subsequent homotransplantation (right). The patient was B+ blood type and received donations from a B baboon and an O human volunteer. The cause of death was pneumonia. Note sharp falls in urine sodium concentration with heterograft rejection episodes, as well as with the rejection that occurred after subsequent homotransplantation.

was added to the pretreatment regimen. After operation, these drugs were continued. In addition, 200–400 micrograms/day i.v. actinomycin C and local irradiation to the transplant site were either given prophylactically or for the treatment of rejection. When used, irradiation was given every other day for 3 or 4 times. The individual doses were 150 r, at depth, delivered with a 250 K.V. machine, 30 MA, total skin distance 70 cm, using a Thaurus II filter. Output was 31.8 r per minute. The fields were approximately  $16 \times 12$  cm.

It was attempted to administer as much azathioprine as could be tolerated without causing leukopenia. An effort was made to reduce the quantity of steroids as quickly as possible later in the postoperative course, but as will be described, this did not prove to be feasible since repudiation of the heterograft occurred even with the very high level of prednisone therapy.

*Renal function.* Clearance of creatinine (CCr) and of para-aminohippurate ( $C_{PAH}$ ) was determined 6 and 18 hours post-transplant with the catheter still

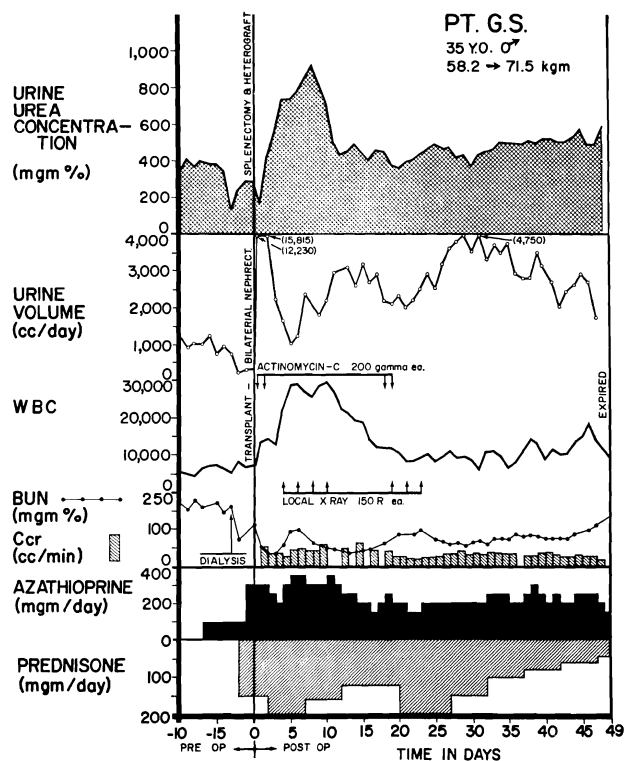


FIGURE 4. Case 6. Patient was O+ blood type and received AB baboon heterografts. Rejections occurred at 4, 18, and 48 days. Direct cause of death was pneumonia. Note gradual falls of creatinine clearance and slow progression of azotemia between partially reversible rejection crises.

in place, using 2 or 3 collection periods of 20 min each. Subsequent creatinine clearances during continuation of the early diuresis were based on timed spontaneously voided single specimens. After diuresis had abated, measurements were made of pooled 24-hr urines. At all times, mid-collection blood determinations were used in calculating clearances.

Fractional urine specimens were collected each 4 hr until the catheter was removed, every 6 hr for the following 48 to 60 hr, each 12 hr until the fifth postoperative day, and every 24 hr thereafter. Urines and daily plasmas were analyzed for sodium, potassium, chloride, urea, creatinine and osmolarity.

*Immunologic studies.* Recipient blood typing was done with standard procedures using commercially prepared antisera.<sup>7</sup> The "blood group substances" of the donor animals were determined by two methods. Saliva was studied for its ability to inhibit the activity of specific antisera and the sera of the animals was examined for the ability to agglutinate human erythrocytes.<sup>8</sup>

The baboons were exsanguinated after the kidneys were removed and the

<sup>7</sup> Thirteen erythrocyte subgroups were also typed and will be provided upon request.

<sup>8</sup> These determinations were done in the laboratory of Doctor J. Moor-Jankowski, Bethesda, Maryland.

erythrocytes were stored in ACD solution in 5 ml aliquots at 4 C. Under these conditions, the cells retain their immunologic properties for approximately 2 months. In one instance (Case 5), the baboon cells were collected in ethylenediaminetetraacetic acid (EDTA) and these cells deteriorated rapidly under storage. The late samples in some of the patients (Cases 3, 4, and 6) were checked for heteroagglutinin activity against freshly collected baboon erythrocytes in addition to the stored cells of their donor.

Blood was obtained from the patients preoperatively and serially during the postoperative period. The samples were allowed to clot for 2 hr at room temperature and were then centrifuged at 2000 rpm for 15 min. The serum was removed, divided into aliquots, and stored at -20 C until use.

The serum samples were stored until a large series from a single patient could be examined at the same time. When all samples from one patient were not examined simultaneously, sera from the first set were included with the second to provide control for variation in the method.

Serial two-fold dilutions of each serum sample were prepared. The baboon erythrocytes were washed and 0.05 ml of a 2% suspension in saline were added to 0.1 ml volumes of the serum dilutions. With the exception of Patient 5, the sera were examined for agglutinins directed against the erythrocytes of the donor. The sera from Patient 5 were tested against the red cells of the baboon used in Case 6, an animal of the same blood type (AB) as that used for Case 5. After incubation at 25 C for 60 min, the tubes were centrifuged at 1000 rpm for 2 min. The sediment was gently agitated and agglutination read macroscopically and microscopically.

Anti-A and anti-B agglutinin titers were determined for each serum sample from the kidney recipients. Normal human type A and type B erythrocytes were washed and diluted to 2% suspensions. A volume of 0.05 ml of this suspension was added to each dilution of patients' sera.

In two patients (Cases 1 and 3), the survival of transfused donor baboon erythrocytes was measured during the early postoperative period. Twenty-five ml donor blood, collected in ACD, was incubated with 150  $\mu$ c Cr<sup>51</sup> <sup>9</sup> for 30 min at 37 C. Ascorbic acid, 500 mg, was added to the incubation mixture. One ml volumes of the tagged erythrocytes, diluted in 3 ml saline, were injected i.v. Blood samples were collected at 5-min intervals and 3 ml aliquots were counted in a well-type scintillation counter.

*Pathologic studies.* Sections were cut at 3 microns and stained routinely with hematoxylin and eosin, periodic acid Schiff reagent, Weigert's for elastic tissue (counterstained with hematoxylin and van Gieson), picro-Mallory 5, Martius scarlet blue, Mallory's phosphotungstic acid hematoxylin (PTAH) and methyl green pylonin. Other special stains such as Sudan 3 and Masson 44/41 were used when indicated.

## RESULTS

*Clinical course.* Survival is recorded in Table 2. Four patients died with the baboon kidneys still in place. In Cases 3 and 4, the heterografts were

<sup>9</sup> Chromatope, E. R. Squibb and Sons, New Brunswick, New Jersey.



TABLE 3

Case	Became anuric	Direct cause of death	Ultimate heterograft function
1	No	Pulmonary emboli with abscess formation	Failing
2	Yes	Rejection	Failed
3	No	Regrafted <sup>a</sup>	Failing
4	No	Regrafted <sup>a</sup>	Failing
5	Yes	Rejection	Failed
6	No	Pneumonia: poor renal function	Failing

<sup>a</sup> Died of sepsis 39 and 44 days respectively after the secondarily performed homotransplantation (see text).

TABLE 4

*Features of rejection and its reversibility*

Case	Onset (days)	Duration before reversal	Agent used for reversal therapy	Degree of reversal
1	None definite	—	—	—
2	5 days	2 days	Actinomycin C	Excellent
	9 days	3 days	Actinomycin C: local X ray	—
	15 days	Irreversible	Actinomycin C: local X ray	None
3	5 days	4 days	Local x-ray	Good
	50 days	—	Not attempted	—
4	8 days	21 days	Actinomycin C: local X ray	Fair
	37 days	6 days	Actinomycin C: local X ray	Fair
5	4 days	2 days	Local x-ray	Fair
	7 days	Irreversible	Actinomycin C: local X ray; increased steroid	None
6	4 days	3 days	Local X ray	Good
	18 days	5 days	Actinomycin C: local X ray	Fair
	48 days	—	Not attempted	—

<sup>a</sup> Complete reversal was not achieved in any instance since improvement ceased before pre-existing renal function had been reached. The consequence was a progressive deterioration of function, interrupted by partial remissions.

removed after 60 and 49 days respectively, and homografts from volunteer convict donors were placed on the opposite side. Survival after the second operation was 39 days in Patient 3 and 44 days in Patient 4. Complete cessation of heterograft excretion occurred only in Cases 2 and 5 (Table 3), although renal function was failing in the remainder prior to death (Patients 1 and 6) or before removal of the transplant (Patients 3 and 4).

All patients exhibited a marked early clinical improvement at the time of initial diuresis and for varying periods thereafter. Recovery was, however, interrupted in each instance except Patient 1 by early rejection crises, which were characterized by transplant site tenderness, and by multifaceted evidence of acute renal failure. The timing of the rejection episodes is indicated in Table 4 and the influence upon renal function is graphically portrayed in Figures 2-4.

Ultimately, each of the last five cases became unmanageable because of the repetitive and closely-spaced rejections. Although the individual crises could

be at least partially controlled in most instances, with local transplant irradiation, actinomycin C or increases in steroid dosage, the adverse consequences could not be completely reversed before the onset of the next assault. The cumulative effect was progressive deterioration, interrupted by incomplete remissions. In Patients 3 and 4, removal of the heterografts was precipitated by the sudden formation of masses in the transplant areas, of such magnitude in Case 3 as to produce massive edema of the right leg which was apparently due to local compression of the venous and lymphatic systems. At the time of extirpation, the swollen and boggy heterografts were surrounded with 500 to 1000 cc serosanguineous fluid under considerable pressure.

Because of the intensity and perseverance of rejection, it was not possible to successfully relax the magnitude of immunosuppressive measures. Every attempt to reduce prednisone was followed by serious rejection. The prolonged use of doses in excess of 100 mg/day resulted in profound hypercorticism. Three of the six patients developed steroid diabetes and one required treatment with insulin. The extraordinary degree of immunosuppression required to maintain even mediocre renal function undoubtedly contributed to the septic complications which played a role in the unfavorable outcome of all but Patient 5. In Cases 3 and 4, in which homografts were ultimately used to replace the excised baboon kidneys, the protracted initial course of stringent antirejection therapy appeared to have jeopardized the prognosis for the same reason, since sepsis was a terminal event in both patients.

Patients 1 and 2 had early pulmonary emboli with infarction and abscess formation. Resection of the left lower lobe and lingula was performed in Case 2 in an attempt to eliminate this septic focus. The sources of the thrombi were not found at autopsy. There were no clots at or near the venous anastomoses.

*Matched versus unmatched AB blood types.* Those patients receiving heterografts from baboons with compatible blood types had more sustained function than those which did not (Table 2).

*Early heterograft function (D. A. O.).* Table 5 indicates 24-hr urine volumes, changes in BUN and clearances of PAH and endogenous creatinine for the

TABLE 5

*Changes in urine volume, BUN, and renal clearances for the first three postoperative days*

Case no.	Urine volume, ml			Pre-transplant	BUN mg% <sup>a</sup> Hrs post transplant				C <sub>er</sub> ml/min. <sup>a</sup> Hrs post transplant				C <sub>PAH</sub> ml/min. <sup>a</sup> Hrs post transplant	
	1st 24 hr	2nd 24 hr	3rd 24 hr		6	18	42	64	6	18	42	64	6	18
	1	8710	5790		2770	93	102	98	74	78	15	43	—	—
2	24290	4390	2575	59	48	31	18	16	50	45	—	—	150	257
3	8915	2555	2895	92	83	67	68	62	25	37	22	35	74	130
4	20250	3540	2780	132	105	62	39	37	39	58	38	46	80	333
5	12345	3700	3800	81	73	48	54	60	39	34	—	30	139	—
6	24510	6000	2060	111	80	55	—	58	59	61	93	37	216	241
Mean	16500	4330	2810	95	82	60	51	52	37.9	46.3	51	37	123	255

<sup>a</sup> BUN = Blood urea nitrogen; C<sub>er</sub> = Endogenous creatinine clearance; C<sub>PAH</sub> = para-aminohippurate clearance.

TABLE 6<sup>a</sup>  
 Minimum and maximum values of urinary composition for each patient  
 in the first six postoperative days

Case	Urine flow rate ml/min		Urine sodium conc. mEq/L		Urine potassium conc. mEq/L		Urine chloride conc. mEq/L		Urine urea conc. mg%		Urine osmolality mOsm/L		C <sub>osm</sub> ml/min		C <sub>H<sub>2</sub>O</sub> ml/min	
	Min.	Max.	Min.	Max.	Min.	Max.	Min.	Max.	Min.	Max.	Min.	Max.	Min.	Max.	Min.	Max.
1	1.53	9.00	22	54	24	45	13	72	236	925	272	517	1.78	8.03	-0.98	1.17
2	0.98	25.5	47	113	4.0	28	30	100	68	310	238	349	0.98	21.4	-0.02	4.10
3	0.38	9.25	32	114	8.0	55	33	105	182	840	254	449	0.69	7.04	-0.47	2.21
4	1.03	19.4	53	109	12	58	43	94	150	485	254	437	1.18	17.6	-1.08	2.70
5	0.65	12.7	85	115	10	24	58	99	126	322	262	345	0.62	10.3	-0.15	2.40
6	0.69	24.0	34	165	10	68	34	110	160	792	297	580	1.04	23.0	-1.42	1.60
Mean	0.88	16.7	46	112	11	46	35	97	153	612	263	446	1.05	14.6	-0.69	2.37

<sup>a</sup> C<sub>osm</sub> = osmolal clearance; C<sub>H<sub>2</sub>O</sub> = free water clearance.

first 3 postoperative days. Table 6 lists for each patient minimum and maximum values of urine flow rate; urinary sodium, potassium, chloride and urea concentrations; urinary osmolality; and osmolal and free water clearances. Figure 5 depicts these findings in detail for Patient 2. A massive diuresis was

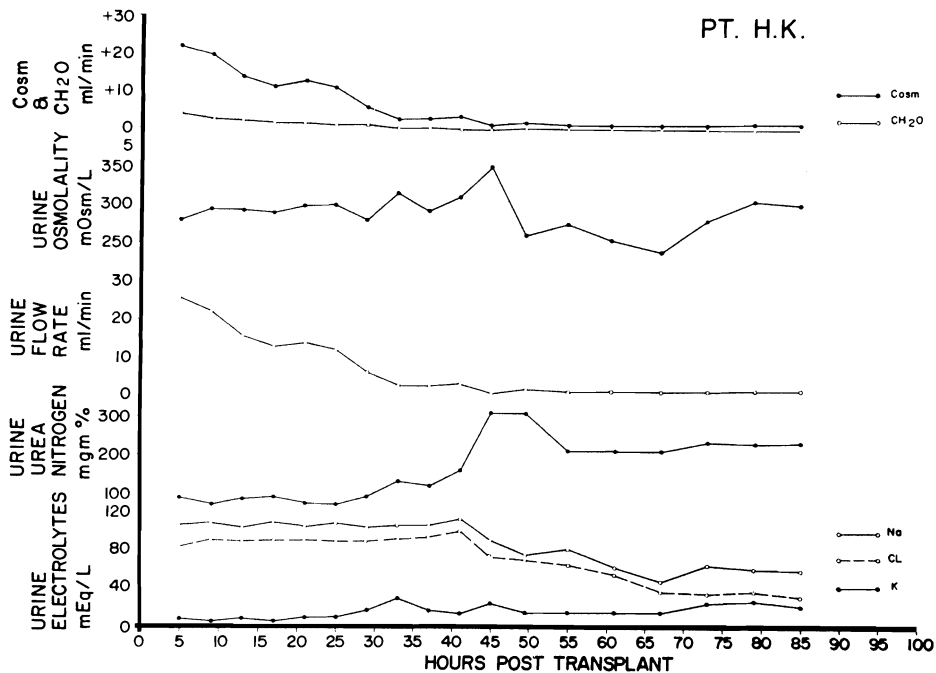


FIGURE 5. Urine constituents in Case 2, during massive postoperative diuresis which totaled 24,290 cc in first 24 hours, initially being 1,500 cc per hour. Note low urine osmolality and limited free water clearance. The urine electrolyte composition is similar to that usually seen after homotransplantation.

observed in every instance. The electrolyte composition in Cases 2, 3 and 4 was similar to that usually seen after homotransplantation (17) but was variable in the other three patients.

In each patient, urinary osmolality was less than plasma osmolality for 24 to 48 hr. Osmolal clearance was, therefore, less than urine flow rate during this time and free water clearance was positive (Fig. 5).

*Later heterograft function* (D. A. O.). Figures 2-4 portray 24-hr urinary output, BUN and CCr in the three cases with the most sustained heterograft function. In Cases 3 and 4, comparison with the subsequent behavior of secondarily-placed homografts was possible (Figs. 2, 3). Since the recipient's diseased kidneys were removed in each case, the function studied was entirely that of the transplanted tissue.

The early renal function described in the preceding section was not normal, but it was sufficient to produce immediate clinical benefit. Unfortunately, acute deterioration of function was noted in all but Case 1 within 8 days, with the onset of the first of multiple rejection episodes (Table 4). The episodic depression of heterograft performance, which was the most important measurement in defining the timing and intensity of rejection, was shown by exclusion not to be due to technical factors either at the time of autopsy or surgical re-exploration.

The alterations in renal function (Figs. 2-4) were similar to those which characterize homograft repudiation (17). Urine volume fell. Sudden rises in BUN and serum creatinine occurred with declines in creatinine clearance. The partial reversibility of these changes was encouraging. In many instances (Table 4), this was accomplished with the combined use of actinomycin C and local irradiation. The efficacy of each of these agents alone was also demonstrated on other occasions (Table 4), the most clear-cut benefit being with local X-ray therapy (Figs. 2, 4). In Cases 4 and 6, secondary diuresis occurred with volumes as high as 7870 and 4750 ml (Figs. 3, 4).

The relative ease with which partial remission could be achieved was misleading. Functional restoration was either short-lived or incomplete. The shortest interval between the first and subsequent rejection crisis was 3 days; the longest was 45 days (Fig. 2). Between these dramatic occurrences, there was frequently a subtle diminution in function (Figs. 2-4). Patients 2 and 5 ultimately became anuric. The last creatinine clearances measured in Cases 1, 3, 4 and 6 before removal of the heterografts or death of the patients were 59.8, 16.1, 25, and 14.8 ml/min.

In addition to the other features of rejection described above, a consistent alteration of urinary composition was observed. A sharp decrease in urinary sodium and chloride concentration accompanied the relative oliguria of the rejection episode (Figs. 2, 3) in every instance (Table 7). A concomitant increase in urinary urea nitrogen concentration was usually observed. With reversal of rejection, the diminished sodium excretion tended to return to the previous level at the same time as improvement occurred in urine volume, creatinine clearance, and BUN. That none of these alterations is a unique feature of heterografts was evident from the fact that similar changes were

TABLE 7  
*Changes in urine volume, urine sodium concentration, and urine chloride concentration with rejection*

Case	Rejection no.	Sodium fall mEq/L	Chloride fall mEq/L	Vol. decrease ml
1	No rejection			
2	First	107-27	91-19	2050-1435
	Second	60-46	42-42	1880-1385
	Third	58-50	71-34	2980-0
3	First	88-35	72-23	2340-960
	Second	51-19	30-20	3320-1355
4	First	82-27	84-30	4650-1215
	Second	37-10	35-7	4400-1590
5	First	106-83	85-18	3995-820
	Second	76-47	58-14	3090-0
6	First	129-15	58-35	2555-1075
	Second	70-2	56-19	3240-2040
	Third	61-22	59-24	2915-1710

observed in Case 4 during a single rejection episode after placement of a homograft (Fig. 3).

#### *Infectious Complications (D. R.)*

A variety of infections were observed before and after heterotransplantation (Table 8). Those occurring before immunosuppression was started were effectively treated. Those occurring after institution of immunosuppression were not affected by antibiotic therapy, the infectious complication contributing to 5 of the 6 deaths (Table 8).

It has been pointed out previously (15) that several consequences of immunosuppressive therapy summate to render the patient abnormally susceptible to infectious complications. These effects were apparently magnified in the heterotransplantation cases in which maximal suppressive therapy was required for even temporary survival of the grafted organ. The extreme degree of immunosuppression was reflected by the presence of significant leukopenia (3000/mm<sup>3</sup> or less) in three patients, hypogammaglobulinemia (600 mg% or less) in two, and glycosuria in three. It is probably for these reasons that only one of the six known bacterial infections occurring after the institution of immunosuppression was controlled. Antibiotic therapy may have contributed to the development of the systemic fungal infections.

#### *Immunologic Studies (C.H.K. & W.E.C.W.)*

*Heteroagglutinins.* The preoperative sera of the six recipients contained heteroagglutinins for baboon erythrocytes. In each case, the titer fell following transplantation (Figs. 6-11), and in Patients 2-6, it subsequently rose in association with rejection attempts (Figs. 7-11).

*Anti-A and anti-B isoagglutinins.* Patients 2, 4, 5 and 6 had anti-A agglutinins preoperatively. Patient 4 (blood group B) received the kidneys from a type B baboon and no change in anti-A activity was noted during the early

TABLE 8  
*Infectious diseases occurring in renal heterograft recipients*

Case No.	Time of occurrence	Type of infection	Etiology	Result of therapy	Relation to death
1	Post-heterograft	Pneumonia following emboli	Escherichia coli and Pseudomonas aeruginosa	Not cured	Contributory
2	Post-heterograft	Pneumonia, empyema, and abscess following pulmonary emboli	Escherichia coli and Pseudomonas aeruginosa	Not cured	Contributory
		Septicemia	Pseudomonas aeruginosa	Not cured	Contributory
3	Pre-heterograft	Multiple septic pulmonary emboli	Staphylococcus aureus	Cured	Unrelated
	Post-heterograft	Urinary tract	Escherichia coli	Cured	Unrelated
		Pneumonia with brain abscess	Aspergillus fumigatus	Not cured	Cause
4	Pre-heterograft	Pneumonia	Staphylococcus aureus	Cured	Unrelated
	Post-heterograft	Nasal abscess	Staphylococcus aureus	Cured	Unrelated
	Post-homograft	Otitis media	Staphylococcus aureus	Cured	Unrelated
5	Post-heterograft	Pneumonia	Unknown	Not cured	Cause
		Esophagitis	Candida albicans	Not cured	Unrelated
6	Post-heterograft	Zoster	Herpesvirus varicella	Regressed	Unrelated
		Urinary tract	Klebsiella-Aerobacter	Not cured	Contributory
		Pneumonia	Klebsiella-Aerobacter	Not cured	Cause

postoperative period (Fig. 9). Patient 2 (blood group O), received a transplant from a baboon of type B, and a delayed fall in anti-A activity was observed (Fig. 7). The two remaining patients were type O; and following transplantation of kidneys from baboons of type AB, a gradual fall in anti-A activity occurred (Figs. 10, 11). In one of these two patients (Case 5), a subsequent rise in anti-A agglutinin titer was demonstrated during a final rejection reaction (Fig. 10). The titer remained elevated throughout the period of anuria that preceded death. In association with the rise in agglutinin titer, hemolytic activity for the type A test cells was observed.

Anti-B agglutinins were present in the sera of four patients (1, 2, 5 and 6) preoperatively (Figs. 6, 7, 10, 11). Patient 1 received kidneys from a type A baboon and no change in anti-B activity was observed postoperatively (Fig. 6). The remaining three patients received kidneys from baboons of type B or AB and a prompt fall in anti-B titer occurred (Figs. 7, 10, 11). In all three

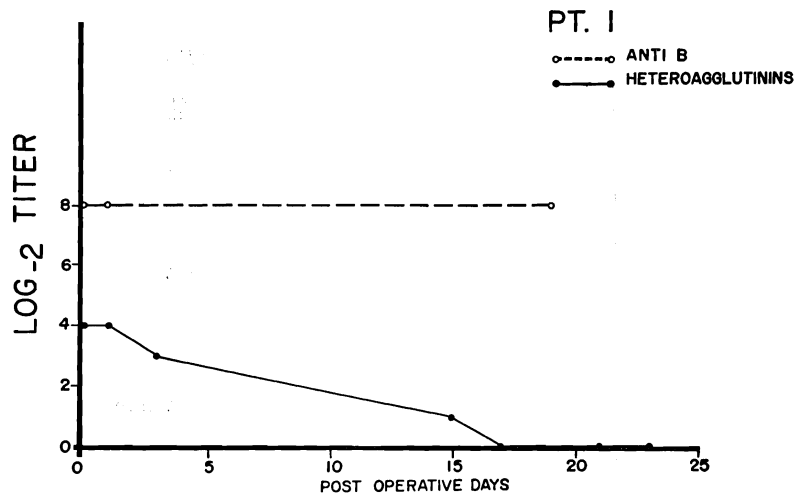


FIGURE 6. Titers of human anti-B isoagglutinin and heteroagglutinin for baboon erythrocytes observed after transfer of a renal heterograft from a type A baboon to a type A+ patient. The levels of anti-B isoagglutinin remained unaltered. In contrast, there was a progressive fall in heteroagglutinin activity throughout the entire course.

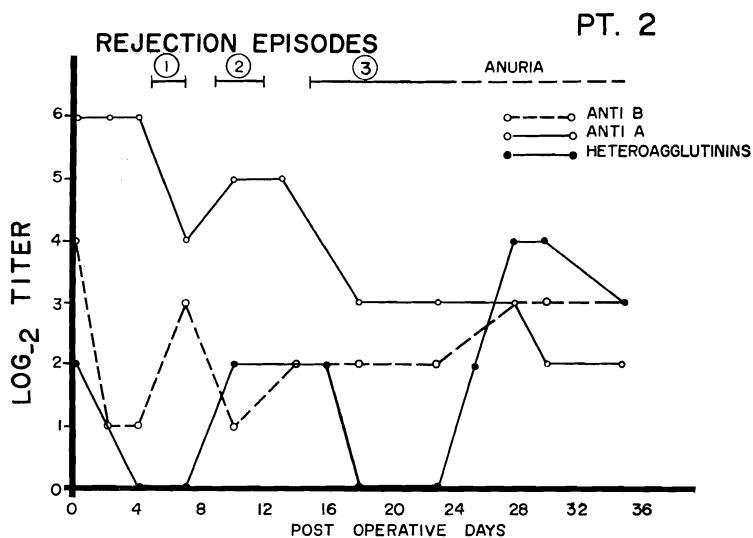


FIGURE 7. Levels of human anti-A and anti-B isoagglutinins and heteroagglutinins in Case 2. Transfer was from a type B donor to an O- recipient. Note the slightly delayed fall in anti-A titer. There was a prompt fall in anti-B levels, followed by transient elevations. Heteroagglutinin activity roughly paralleled the anti-B isoagglutinin curve. The fluctuations in antibody titer do not correlate well with the rejection episodes; however, a marked rise in titer was observed during the period of anuria.

patients the titers increased, usually during the rejection reaction, and in Patient 5 hemolytic activity against type B cells also became apparent.

*Erythrocyte survival studies.* Two patients (1 and 3) received i.v. infusions of  $Cr^{51}$ -labeled donor erythrocytes between 4 and 6 hr following kidney transplantation. These heterologous erythrocytes were removed from the circula-

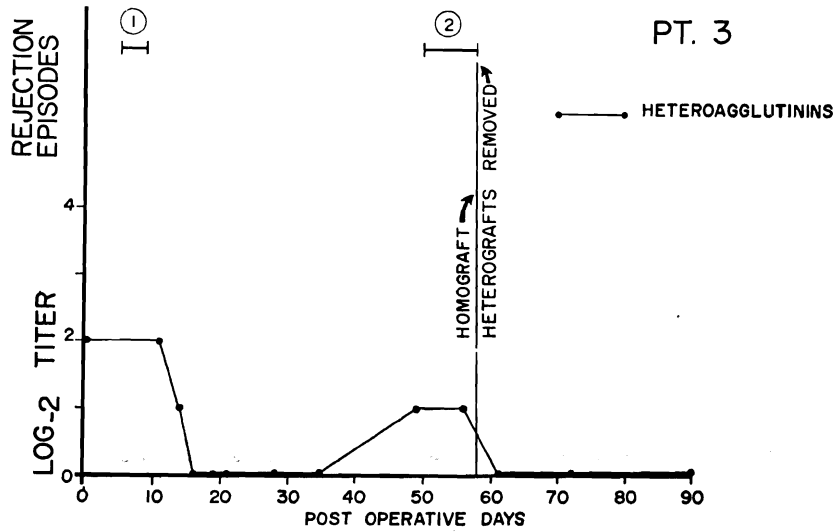


FIGURE 8. Heteroagglutinin levels in Case 3. The titer fell only after reversal of the first rejection crisis. Increased activity was again demonstrated during the second episode of rejection. Removal of the heterograft was followed by total disappearance of heteroagglutinin activity. The recipient patient was AB+ and therefore had no isoagglutinins. The baboon was B.

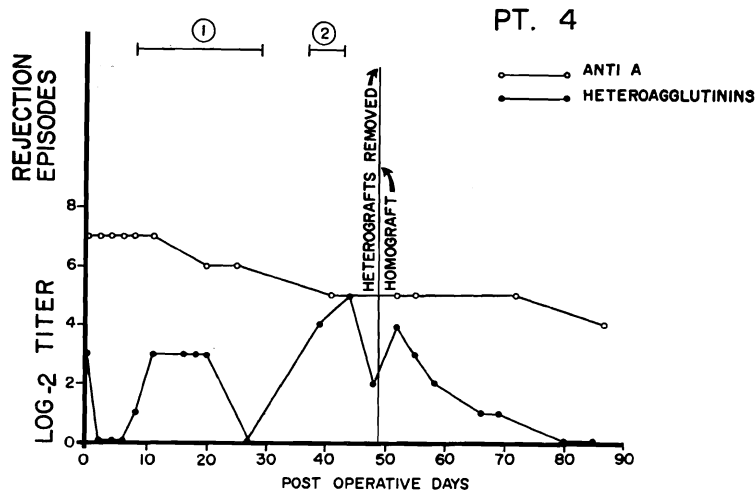


FIGURE 9. Changes in human anti-A isoagglutinin and heteroagglutinin titers observed after transfer of B heterograft to a B+ recipient. There was a gradual decline in anti-A levels after 10 days. Heteroagglutinin activity fell initially, then increased and decreased with the onset and reversal of rejection crises.

tion with 50% clearance times of 12 min, an observation which suggests biologic function of the host heteroagglutinins.

*Gross Pathologic Studies (K.A.P.)*

The baboon kidneys were all enlarged, with a mean weight of 108 gm. This increase was greatest (180 gm) in Case 2, where function ceased at 25 days



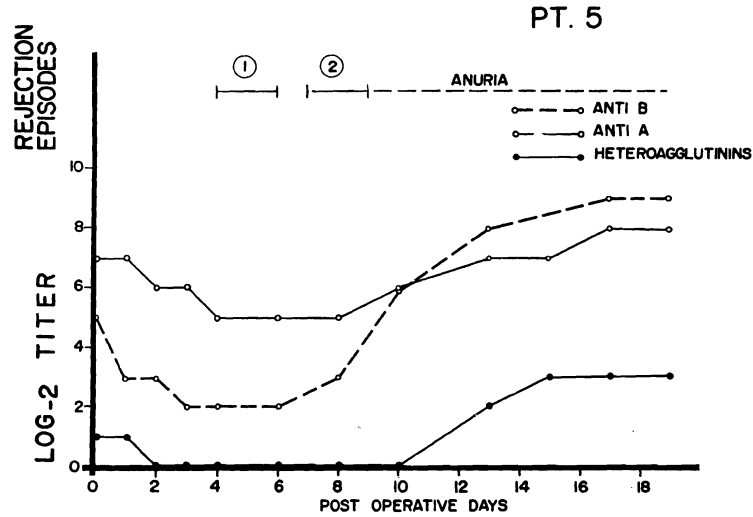


FIGURE 10. Pattern of anti-A and anti-B isoagglutinin and heteroagglutinin activity of Case 5. The heteroagglutinin titer fell following operation and subsequently rose during the terminal, irreversible rejection episode. Similar changes were observed in both isoagglutinin titers. The donor was AB and the recipient O-.

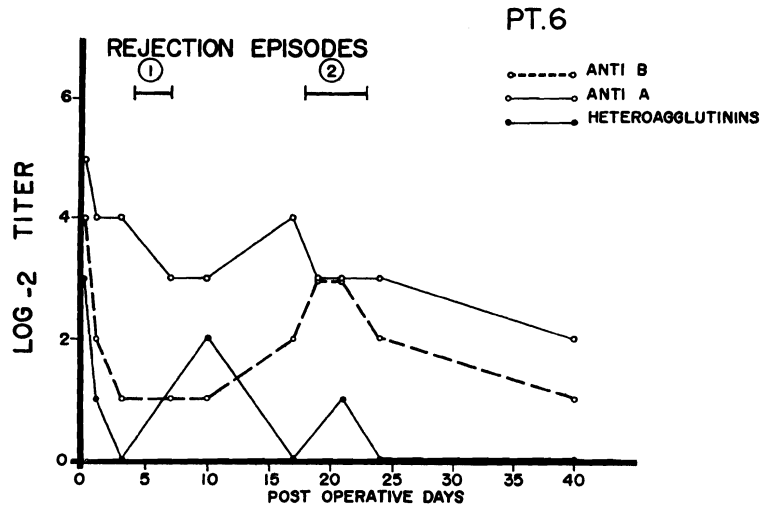


FIGURE 11. Alterations in anti-A and anti-B isoagglutinins and heteroagglutinins in Case 6. An AB heterograft was placed into an O+ recipient. Note the slow decline in anti-A activity. In contrast, both anti-B levels and titers of heteroagglutinin fluctuated throughout the course, tending to rise with rejection episodes and to recede with reversal.

following an irreversible rejection phase, and least (65 gm) in Case 1, where the patient had never experienced a clinically recognizable rejection episode and where the creatinine clearance was still 59.8 ml/min shortly before the patient died from a pulmonary embolus.

The capsules were a little thickened and stripped easily. In Case 1 the sub-capsular surfaces were smooth, light brown and speckled with petechial hemor-

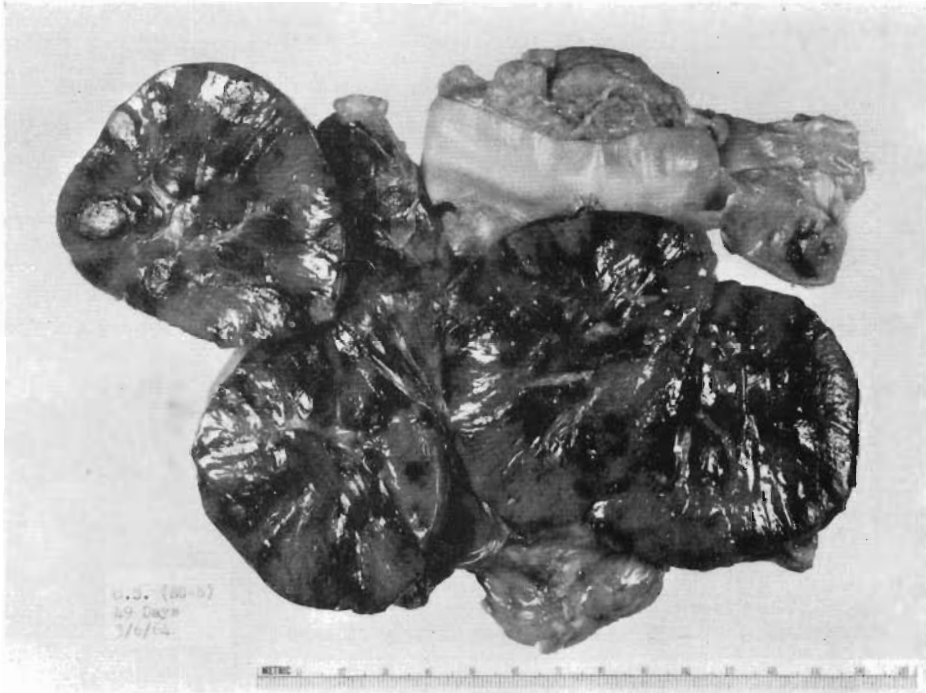


FIGURE 12. Heterografts recovered at autopsy in Case 6. Each kidney weighed 80 grams. Note swollen hemorrhagic appearance of both heterografts. The lighter wedge-shaped areas (far left) are small infarcts of the cortex.

rhages; when cut, the kidneys bulged slightly and there was some blurring of the corticomedullary junction. The kidneys from Case 5 were a uniform reddish purple and it was not possible on the cut surface to differentiate between cortex and medulla. However, the other four pairs of transplants were mottled with irregular blotchy hemorrhages, measuring up to 0.5 cm in diameter, and paler yellowish infarcted areas which were each surrounded by a bright red zone several millimeters wide (Fig. 12). There were also scattered petechial hemorrhages. The cut surfaces of these kidneys bulged and similar hemorrhagic and paler areas were seen in the cortex and extending into the deep red medulla. The main renal artery and vein were patent in all cases, although the blind pouch of baboon aorta was filled with laminated thrombus in Case 2. The right kidney from Patient 1 was surrounded by a large hematoma which might have caused some compression of the renal artery on that side. The ureters had swollen, often hemorrhagic walls, with narrowed but patent lumens. There were petechiae in the calyces and renal pelves.

#### *Microscopic Pathologic Studies (K.A.P.)*

*Cellular infiltration.* All the transplanted kidneys were heavily infiltrated by cells (Figs. 13, 14). This was most pronounced in Cases 1 and 3 and least obvious in Case 6. The cells, which were found predominantly in the cortex,

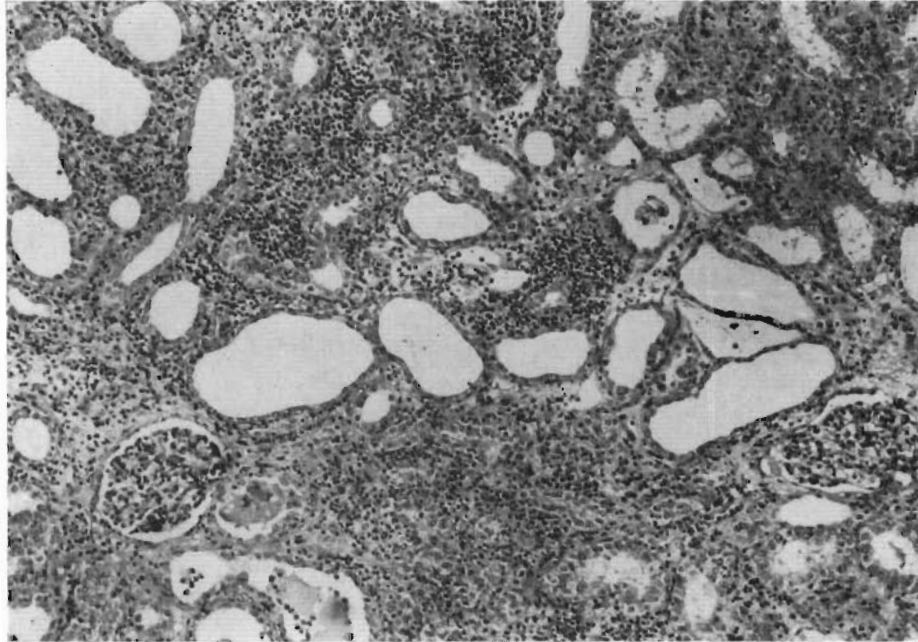


FIGURE 13. Case 3. Baboon renal heterotransplant from patient who was in rejection for the second time when the specimen was removed at 60 days. Many tubules had been destroyed. Those surviving are dilated and lined by flattened epithelium. The interstitium is edematous and heavily infiltrated with cells. H & E ( $\times 150$ ).

were distributed in a patchy fashion in four of the pairs of transplants, but in Patients 1 and 4 they were scattered diffusely throughout the interstitium. Many were plasma cells and some of these possessed two or even three nuclei. Others were cells with varying amounts of pyronin-positive cytoplasm and large pale nuclei, with prominent nucleoli. In Case 1 occasional such cells were in mitosis. There were also a few small lymphocytes, and in Cases 1 and 3 eosinophils were frequent. Phagocytic cells which looked like lupus erythematosus (LE) cells, were present in small numbers in the interstitium of Cases 2 and 3. Some erythrophagocytosis was seen in the transplants from Patient 1.

*Edema.* Interstitial edema was a feature of all these heterotransplants (Fig. 14). It was most severe in the heaviest kidneys which were those from Cases 2 and 3.

*Hemorrhages.* Scattered focal interstitial hemorrhages were present in all of the heterotransplants and accounted for many of the red blotches seen grossly. Although they were infrequent and small in the kidneys from Case 1, they were widespread and large in Cases 3 and 4.

*Infarcts.* Focal small infarcts, while present in all the transplants, were least apparent in Patients 1, 3, and 4 where function terminally had been fair and whose last creatinine clearances ranged from 16.1 ml to 59.8 ml/min. Some of the infarcts were hemorrhagic (Fig. 15). Almost total infarction was present in Case 5.

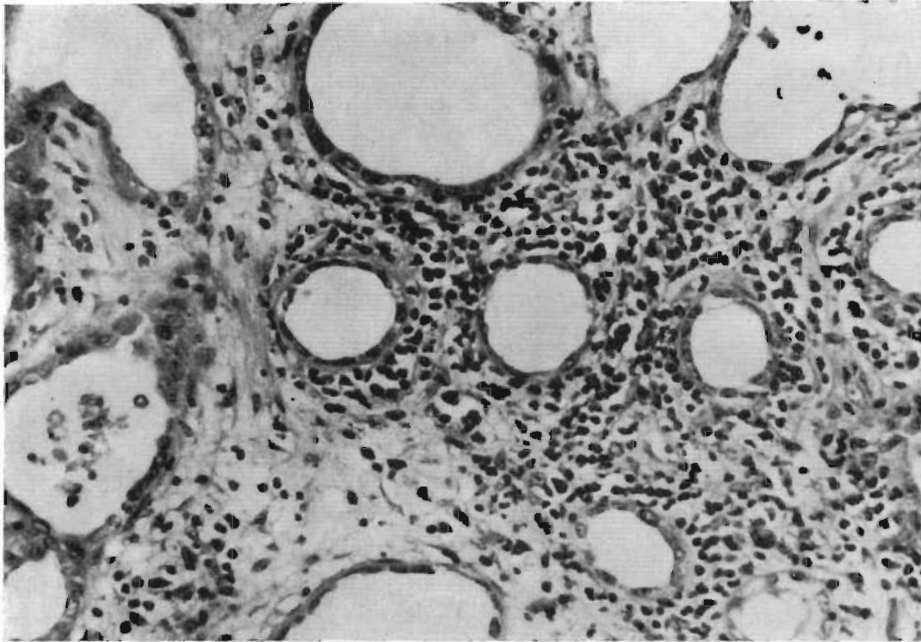


FIGURE 14. Higher power view of baboon heterotransplant from patient 3. Dilated damaged tubules are lined by flattened epithelium. The interstitium is edematous and infiltrated with plasma cells, other pyroninophilic cells, some lymphocytes and a few eosinophils. Many peritubular capillaries have been destroyed. H & E ( $\times 350$ ).

*Vascular changes.* Peritubular capillary destruction was widespread in all the cases (Fig. 14). Surviving capillaries usually contained marginating pyroninophilic and lymphoid cells. Swelling of the endothelial cells lining the afferent arterioles was obvious in three of the pairs of kidneys.

In four of the transplants there was focal fibrinoid necrosis of the walls of the interlobular arteries and arterioles (Fig. 16). There may also have been similar changes in Case 5 but widespread infarction made interpretation of vessel changes impossible. Rupture of the internal elastic lamina of affected vessels was common. Case 1 showed no vasculonecrotic lesions.

Fibrin and platelet deposits on the intima of interlobular arteries were seen in all the transplants and caused narrowing of a variable number of the vessels. Blockage of some lumens was completed by superimposed thrombus. In Case 2 replacement of the fibrin-platelet deposits by fibroblasts had occurred with breakdown of the platelets to leave fat droplets in the deeper parts of the occluding layer.

Obvious secondary thrombosis of large arteries and veins was present in the two pairs of heterotransplants which ceased functioning many days before death of the patient (Cases 2 and 5).

*Tubular damage.* Tubular necrosis with evidence of regeneration was present in all the cases. This was most severe and widespread in Patients 2, 3 and 6. Casts of protein and cell debris were frequent. There were also some red cell and pigment casts.

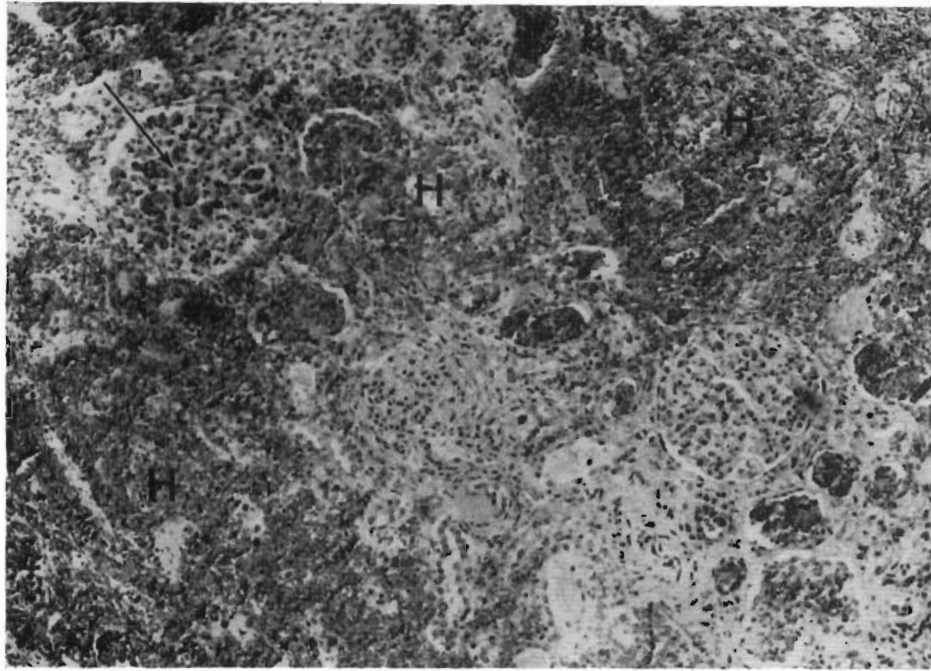


FIGURE 15. Case 6. Baboon renal heterotransplant from patient who was in rejection for the third time when he died at 49 days. Hemorrhagic infarction (H) is shown. The glomerulus indicated with an arrow is necrotic. H & E ( $\times 150$ ).

*Glomerular changes.* The glomeruli were relatively well preserved. There was some hypertrophy of the tufts and prominent granularity of the juxtaglomerular cells in the pair of transplants that functioned for 60 days (Case 3). Hyperplasia and increased granularity of the juxtaglomerular body was present in the one case (Patient 4) in which hypertension had been present during the postoperative course.

#### DISCUSSION

The present study was designed to thoroughly test the feasibility of renal heterotransplantation from baboon to man, with the best therapeutic regimen currently available. This objective was met. There were no surgical mishaps. Each of the heterografts was inserted under ideal technical conditions. Although the transplanted tissue was not weighed at the time of operation, it was predicted from previous ratio determinations<sup>10</sup> of renal weight/total body weight that the total renal mass ranged from 32 to 82 gm, half or less than that of a single human kidney.

The primary cause of failure in all but one case was inability to control rejection. When other nonrenal complications supervened, most were related

<sup>10</sup> By Doctor Tom Vice of the Southwest Foundation for Research and Education, San Antonio, Texas.

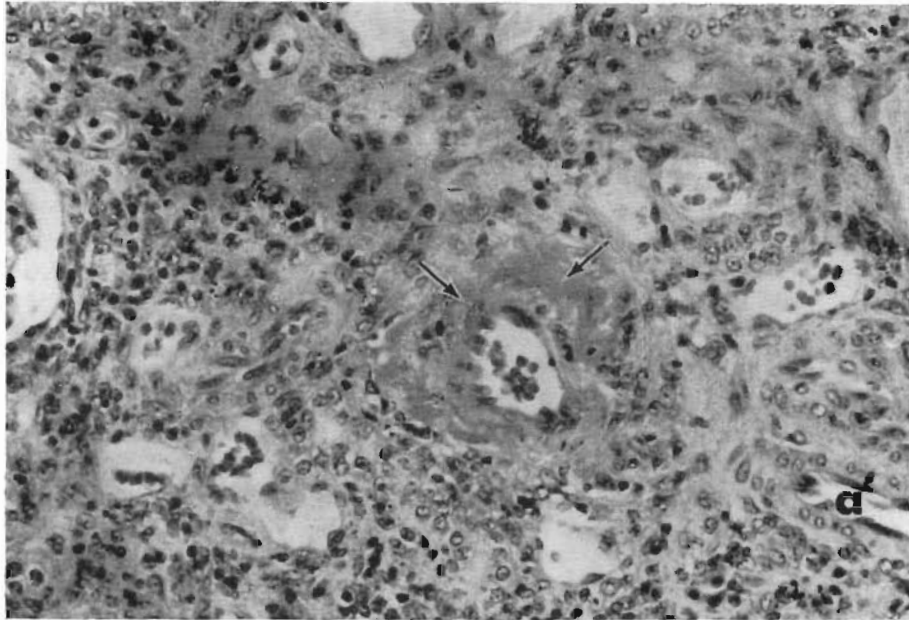


FIGURE 16. Case 4. Baboon renal heterotransplant from patient who was in rejection for the second time when the specimen was removed at 49 days. There is marked fibrinoid necrosis (arrows) of the whole wall of an interlobular artery. An arteriole showing swelling of its lining endothelial cells, but no fibrinoid necrosis, is seen at *a*. There is also tubular atrophy and cellular infiltration of the interstitium. H & E ( $\times 350$ ).

to the need for continuous high-dose immunosuppressive measures. Generally severe pathologic changes were present in the heterotransplants. The cellular infiltration was heavier than that seen in any of the homografts from the University of Colorado renal homotransplantation series (9), which were removed or recovered at autopsy. In Cases 1 and 3 the infiltrate approached in severity that seen in canine homotransplants. The accompanying widespread damage to peritubular capillaries had resulted in extensive tubular necrosis. Arterial and arteriolar lesions were also present and had led to multiple focal infarcts and scattered interstitial hemorrhages. Even the kidneys from Case 1, where no rejection episode was detected, showed heavy cellular infiltration, damage to peritubular capillaries and early patchy tubular necrosis. Under the circumstances of this study, chronic survival after baboon-to-man transplantation seems, therefore, to be a virtual impossibility. Unless improved methods of management become available, further trials do not seem justified and none are contemplated by us until that time.

The recent use of other subhuman primates allows some tentative conclusions concerning the relative biologic suitability of different simian donors for human heterotransplantation. From a pathologic point of view, the vigor of the immunologic reaction has seemed to be much less with chimpanzee tissue, in contrast to baboon and rhesus monkey heterotransplants which evoke a fierce

response on the part of the human host (9). In this connection, it is noteworthy that one patient treated by Reemtsma with paired chimpanzee heterografts has essentially normal renal function 22 weeks after operation.<sup>11</sup>

It was pointed out earlier that baboon heterograft rejection was not overtly different in many respects from that commonly observed with homografts. The differences were quantitative in that repudiation of the alien tissue was more vigorous and insistent. Despite the similarities it is pertinent to consider that the rejection of heterografts may involve immunologic pathways different from those of homografts. Specifically, it might be expected that circulating free antibodies could play a dominant role. In laboratory experiments with cross species transplantation, destruction of whole organ heterografts has been observed to occur with such rapidity (within minutes or hours) that only a humoral mechanism could provide a satisfactory explanation (1). The immediate consequences in these experiments were indistinguishable from those which have been observed in two human cases in which homografts were transplanted between donors and recipients of incompatible blood types (17), and in an A to O chimpanzee-to-human heterotransplantation performed by Reemtsma (14). Since all six patients in the present study had preformed heteroagglutinins directed against baboon erythrocytes, it is surprising that a similar immediate repudiation did not occur, particularly since measurable heteroagglutinins disappeared entirely from the peripheral blood at some time during the postoperative course in each case.

Except as a general index of immunologic activity, the significance of the changes in host heteroagglutinins, and their cyclic variations during rejection episodes, is not known. The disappearance of heteroagglutinins from the peripheral blood indicates that antigenic determinants specific for this serum antibody were present on the renal cells. The later rises in titer could be explained by an intensification of antibody formation accompanied by saturation of all available binding sites within the kidney. The possibility receives some support from the fact that the increases in heteroagglutinin titers tended to occur at the same time as the acute rejection episodes.

There are a number of possible explanations for the failure to observe immediate rejection in the presence of a preformed antibody directed against the heterograft. Stetson and Demopolous (18) have postulated that an intrarenal Arthus reaction is the effector pathway mediating humoral rejection. Since the intensity of the Arthus reaction is a function of the concentration of bivalent antibody (10), it is conceivable that the quantity of recipient heteroagglutinin was insufficient to saturate all the antigenic sites on the kidney cells. The total disappearance of heteroagglutinins is evidence in favor of this. Finally, it is possible that the antigen-antibody union in the baboon did not precipitate the consequences of the release of the chemical effectors of rejection, perhaps because a final step of the reaction was blocked by immunosuppressive therapy.

It is impossible to be certain from present evidence if there is any fundamental difference in the mechanism of rejection in these heterografts as op-

<sup>11</sup> Reemtsma, K. Personal Communication. July 1, 1964.

posed to homografts. With heterografts, both humoral and cellular elements seem to play a role. With homografts, the principal emphasis in the past 2 decades has been directed to the concept of cell-mediated rejection, primarily because of the paucity of evidence implicating measurable serum factors. More recently the potential role of a humoral component of homograft rejection has received increasing support from several lines of evidence (3, 6, 11, 17). The differences between heterograft and homograft rejection may, therefore, be more apparent than real.

Another hemagglutination system was studied which has immediate practical importance since it influences donor selection. It was pointed out in the "methods" section that A and B antigens are not detectable in baboon erythrocytes for which reason the animals were blood typed with salivary tests and by the presence of reciprocal hemagglutinins (21). The alterations in specific anti-A and anti-B titers provide evidence that these antigens do exist in renal tissue despite their absence on the red cells, a situation comparable to that described by Weiner and his associates (20) for the Rhesus monkey.

The marked changes in titer after heterotransplantation of AB blood type mismatches and the absence of this finding in the compatible cases is strong evidence of hemagglutinin binding by the heterograft. As with the heteroagglutinins, this did not prevent immediate function, which in one such patient (Case 6) lasted for 49 days. Nevertheless, average patient survival was not as long and the quality of renal function was at a slightly lower level in the mismatched group. It would, therefore, be considered inadvisable in future clinical investigations of heterotransplantation to accept such incompatible donor-recipient combinations.

#### REFERENCES

1. CALNE, R. Y. 1963. *Renal transplantation*. Williams and Wilkins Co. Baltimore.
2. HITCHCOCK, C. R., KISER, J. C., TELANDER, R. L., AND SELJESKOG, E. L. 1964. *JAMA* 189: 934.
3. HOROWITZ, R. E., BURROWS, L., PARONETTO, F., DREILING, D., KARK, A. E. AND POPPER, H. 1964. *Transplantation* (in press).
4. JABOULAY, M. 1906. *Lyon Med.* 39: 575.
5. KALTER, S. S.: Virological studies on the normal baboon (*Papio doguera*). First International Symposium on the Baboon and its Use as an Experimental Animal. Southwest Foundation for Research and Education, San Antonio, Texas, 1963, p 11.
6. NAJARIAN, J. S. AND FELDMAN, J. D. 1962. *Surg. Forum* 13: 71.
7. NEUHOF, H. 1923. *The transplantation of tissues*. D. Appleton and Co. New York, pp 260-263.
8. PAQUIN, A. J. 1959. *J. Urol.* 82: 573.
9. PORTER, K. A. 1964. In Starzl, T. E., *Experience in renal transplantation*. W. B. Saunders Co. Philadelphia.
10. RAFFEL, S. 1961. *Immunity*. Appleton-Century-Crafts Inc. New York, Ed. 2, p 282.
11. RAMOS, M. R., CHIBA, C., SCHOLLMAYER, P. L., PEARSON, B. AND BING, R. J. 1963. *Transplantation* 1: 284.
12. REEMTSMA, K., MCCracken, B. H., SCHLEGEL, J. U. AND PEARL, M. 1964. *Science* 143: 700.
13. REEMTSMA, K., MCCracken, B. H., SCHLEGEL, J. U., PEARL, M. A., DEWITT, C. W. AND CREECH, O., JR. 1964. *JAMA* 187: 691.
14. REEMTSMA, K., MCCracken, B. H., SCHLEGEL, J. U., PEARL, M. A., PEARCE, C. W., DEWITT,



- C. W., SMITH, P. E., HEWITT, R. L. AND CREECH, O., JR. 1964. Renal heterotransplantation in man. (Presented before the American Surgical Association. Hot Springs, Virginia, April 1, 1964) *Ann. Surg.* 160: 384.
15. RIFKIND, D., MARCHIORO, T. L., WADDELL, W. R. AND STARZL, T. E. 1964. *JAMA.* 189: 397.
  16. SCHÖNSTADT, cited by Morel and Papin. 1913. *Biol. Med.* 10: 397.
  17. STARZL, T. E. 1964. *Experience in renal transplantation.* W. B. Saunders Co. Philadelphia.
  18. STETSON, C. A., JR. AND DEMOPOULOS, R. 1958. *Ann. N. Y. Acad. Sci.* 73: 687.
  19. UNGER, E. 1910. *Berlin Klin. Wehnschr* 47: 573.
  20. WIENER, A. S., CANDELA, P. B. AND GOSS, L. J. 1942. *J. Immunol.* 45: 229.
  21. WIENER, A. S. AND MOOR-JANKOWSKI, J. 1963. *Science* 142: 67.

Received July 8, 1964.