

RADIOISOTOPE SCANNING IN AUXILIARY LIVER TRANSPLANTATION

TANOUS D. FARIS, M.D., F.A.C.S., ALFRED J. DICKHAUS, M.D.,
THOMAS L. MARCHIORO, M.D., F.A.C.S., and THOMAS E. STARZL, M.D., F.A.C.S.,
Denver, Colorado

DURING RECENT YEARS scintillation scanning has proved to be an important tool in the diagnosis of liver disease. This study was undertaken to evaluate this technique for determining the viability and function of canine and human auxiliary hepatic homografts.

METHODS

The same general techniques were used in both the canine and human studies. Intravenously administered rose bengal I^{131} was administered to dogs in a dose of 50 microcuries and to patients in a dose of 150 microcuries; scans were obtained at 5 minutes. In the canine experiments employing gold, 50 microcuries of Au^{198} were used with scanning at 15 minutes; in 2 adult human beings 200 microcuries were administered and scans obtained at 45 minutes. In a third patient, a 6.4 kilogram child, 11 microcuries of Au^{198} were administered and the scan started immediately.

Scans were obtained with a 5 by 2 inch crystal and a 5 inch broad focus collimator. The spectrophotometer was set at 0.345 to 0.395 million electron volts for the I^{131} and 0.355 to 0.455 million electron volts for the Au^{198} . Scan speed was 90 cubic centimeters per minute, with a line spacing of 0.45 cubic centimeter. Density was adjusted according to the counts per minute. Background cutoff was 15 per cent plus or minus 5 per cent,

and the range differential 60 per cent plus or minus 10 per cent. The time constant was 0.1 second.

Canine studies. Liver scans were performed under a variety of circumstances. In all groups of dogs, serum glutamic oxalacetic transaminase, serum glutamic pyruvic transaminase, bilirubin, and alkaline phosphatase were determined at regular intervals, and the patency of the vessels to the homograft and the autologous liver was ascertained at autopsy or before death by angiography. The ischemic interval for the cold-perfused homotransplanted livers was never greater than 1 hour. The dogs with homografts all received 1 to 8 milligrams per kilogram per day of azathioprine.

Group 1.—Eleven normal dogs were studied.

Group 2.—In 5 of the dogs from group 1, scintillation scans were carried out 14 to 29 days after a subsequently constructed Eck fistula.

Group 3.—Nine dogs, including 3 from group 2, had an auxiliary liver transplant to a recipient whose own liver was damaged with an Eck fistula. The portacaval anastomosis was performed in advance in 3 experiments and at the same time as the transplant in the other 6. The common bile duct of the host dog was ligated. The auxiliary liver was rearterialized from the right common iliac artery and received its portal venous inflow from the terminal inferior vena cava (Fig. 1A).

Group 3A.—In 7 of the 9 dogs, it was found both by angiography and at autopsy that both homograft vessels were patent.

From the Departments of Surgery, University of Colorado School of Medicine, and Denver Veterans Administration Hospital and The Department of Radiology, Denver Veterans Administration Hospital.

Aided by Grants AM 06283, AM 06344, HE 07735, AM 07772, AI 04152, FR 00051, and FR 00069 from the U. S. Public Health Service.

Reprint from SURGERY, Gynecology & Obstetrics, December, 1966, Vol. 123, 1261-1268

Copyright, 1966, by The Franklin H. Martin Memorial Foundation

Group 3B.—In 2 of the 9 dogs the portal venous inflow had become thrombosed; in these animals only an arterial inflow was present in both the autologous and homografted livers.

Group 4.—Six dogs received the auxiliary transplant originally described by Welch, with the additional feature that the recipient common bile duct was ligated (Fig. 1B).

Group 4A.—Three dogs were later shown to have an intact double blood supply to the homograft.

Group 4B.—In the other 3 dogs in this group, the portal venous inflow had become thrombosed.

Group 5.—In 10 other dogs, the hepatic arterial supply was derived from the proximal part of the iliac artery. The portal venous inflow was obtained from the distal, low pressure iliac artery (Fig. 1C).

Group 5A.—Both homograft vessels remained patent in 5 dogs. In 3 of these dogs, the recipient common duct was ligated at transplantation while in the other 2 it was left permanently intact.

Group 5B.—In 5 dogs, thrombosis occurred in the distal portion of the iliac artery which had been anastomosed to the portal vein. In 1 of the 5 dogs, the recipient common duct was left intact. In another, the autologous common duct was ligated at transplantation. In the other 3, the duct was ligated from 76 to 153 days after transplantation.

Clinical studies. Three patients, aged 50 years, Patient 1, 47 years, Patient 2, and 16 months, Patient 3, received auxiliary hepatic homotransplantation as described elsewhere in detail (2, 7). In the first 2 patients, the homografts were placed in the right paravertebral gutter, arterialized from the aorta or hypogastric artery, and provided with a venous inflow from the terminal inferior vena cava or the external iliac vein, respectively. These 2 patients had received portacaval shunts 1 and 3 days previously. The intervals between death and revascularization of the homografts were 262 and 180 minutes, during most of which time the

organs were hypothermic. In addition, a 16 month old child had a homograft placed in the splenic fossa, with the hepatic arterial and portal venous supply being derived from the iliac artery and the splenic vein, respectively. The ischemic interval in the last patient was 153 minutes, but, unfortunately, thrombosis of the hepatic artery necessitated reanastomosis, adding a normothermic ischemic injury of at least 30 additional minutes.

RESULTS OF CANINE STUDIES

Group 1.—All 11 unaltered dogs had normal liver function and visualization of the livers was excellent with rose bengal I¹³¹.

Group 2.—In all 5 dogs, elevations occurred in either serum glutamic oxalacetic transaminase, serum glutamic pyruvic transaminase, or alkaline phosphatase after an Eck fistula. Rose bengal I¹³¹ liver scans performed from 24 to 29 days later showed reduced isotope concentration in 2 of 3 dogs. In the 2 others, scans after 14 and 20 days were unchanged from the preoperative controls. Histologic studies indicated that the 2 dogs with the reduced dye uptake had the most severe hepatic injury.

Group 3.—Scans with rose bengal I¹³¹ or Au¹⁹⁸, or both, were obtained from one-half hour to 49 days after homotransplantation.

Group 3A.—The dogs that survived beyond 1 day with patent homograft vessels had posttransplant rises in serum glutamic oxalacetic transaminase, serum glutamic pyruvic transaminase, and alkaline phosphatase. Four of the dogs rapidly became jaundiced after transplantation. Since the host common duct had been ligated in all of these dogs, the failure of jaundice to develop until just before death in 2 dogs suggested that at least some function of the homograft was present in these dogs. Three dogs were sacrificed at 25, 29, and 50 days and the other 4 died after 1 to 42 days, either of pulmonary complications, liver failure, or sepsis.

In 1 dog, a gold scan obtained immedi-

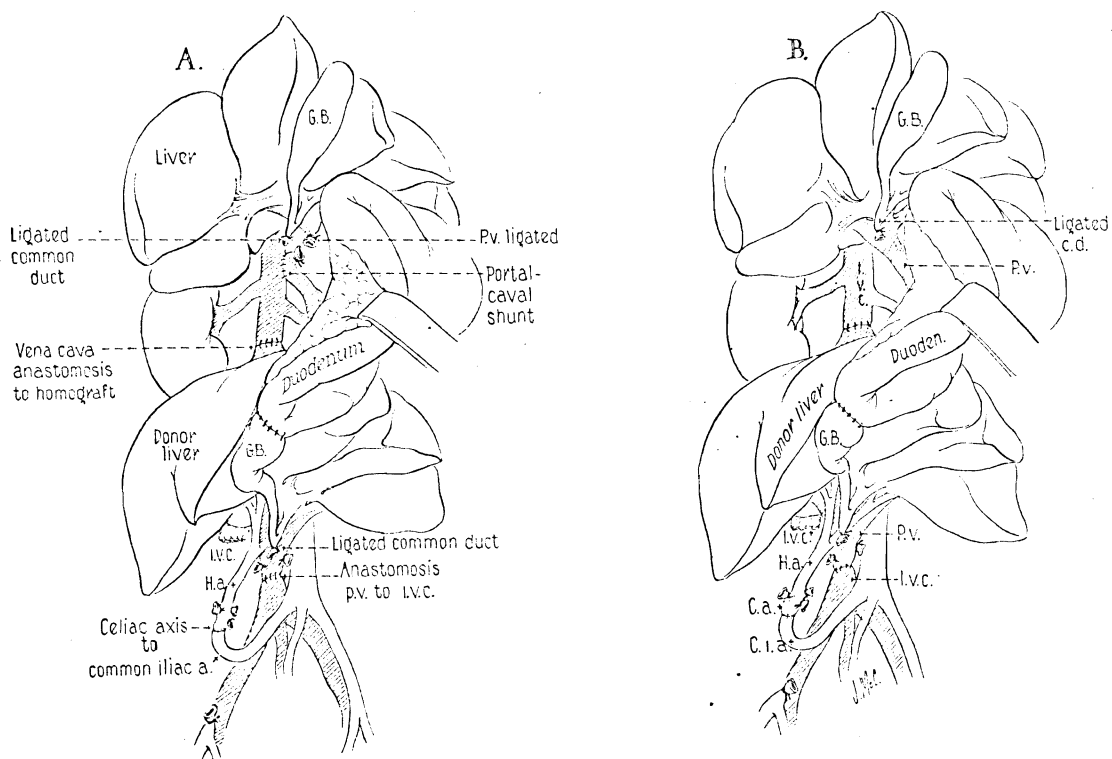
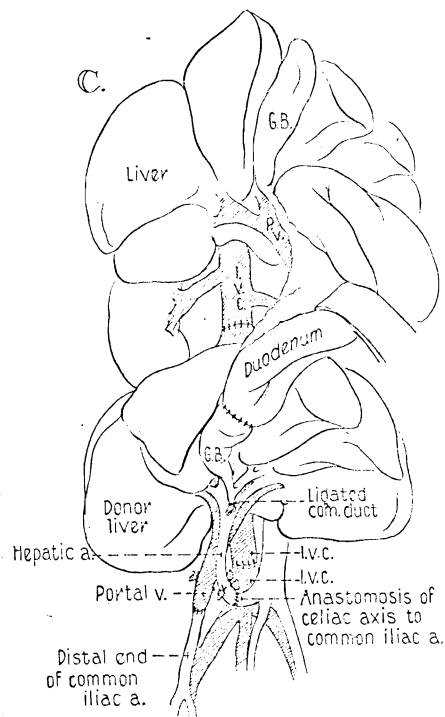


FIG. 1. Methods of revascularization of canine auxiliary homografts of the liver. A, The homograft is provided with a double blood supply—group 3A. The hepatic artery receives an inflow from the iliac artery. The portal vein is supplied with systemic venous blood from the terminal inferior vena cava. Note that the host liver has a portacaval shunt and that the common bile duct is ligated. B, Auxiliary transplantation procedure of Welch—group 4A. Note that a host portacaval shunt was not performed, but that the dog's own common bile duct was ligated. C, Revascularization of homograft with a double arterial supply—group 5A. Note that the proximal iliac artery is used to supply the hepatic artery and that the distal portion of the iliac artery is anastomosed to the homograft portal vein.

ately after operation illuminated both the homograft and the autologous liver equally well. In another, there was excellent homograft concentration of rose bengal (Fig. 2a). In 2 of the 4 dogs tested between the first and tenth postoperative days, the homograft picked up rose bengal approximately as well as the autologous liver. With the further passage of time, 3 of the 5 dogs tested had a loss of isotope concentration in the homograft. The ability to concentrate Au^{198} was, however, selectively preserved. In Figure 2c,



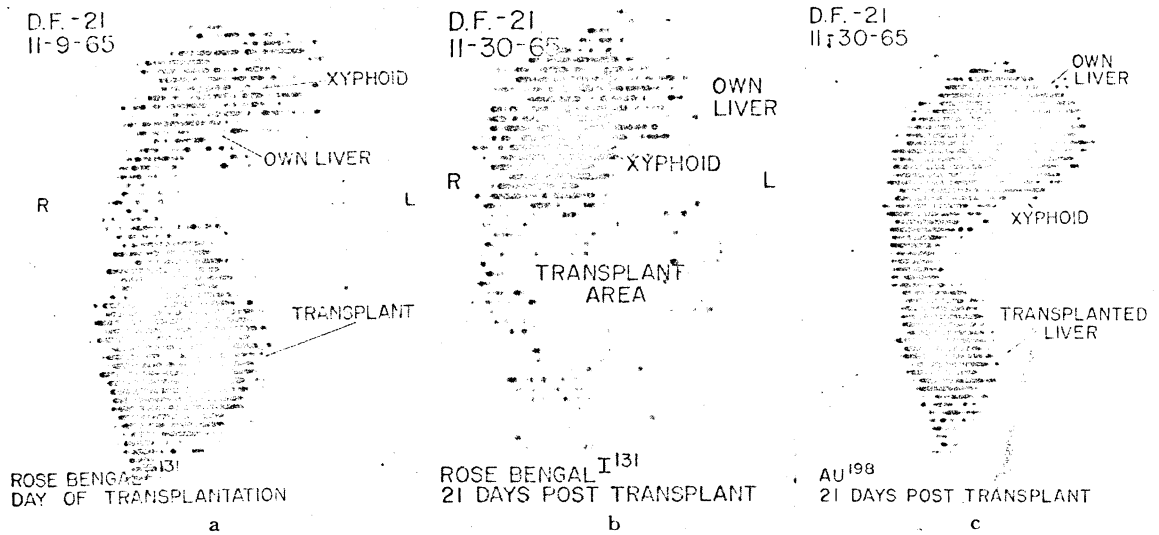


FIG. 2. Canine auxiliary hepatic homograft with inferior vena cava—portal vein anastomosis and host portacaval shunt—group 3A. The host common bile duct was ligated at the same time as homotransplantation. a, Rose bengal I^{131} scan on day of transplantation demonstrates better uptake by the homograft than by the host liver which has been deprived of its portal venous inflow. b, Rose bengal I^{131} scan 21 days after transplantation illustrates negligible uptake of rose bengal by the homograft. c, Gold scan also 21 days after transplantation demonstrates excellent uptake of Au^{198} by the atrophic homograft, despite inability to concentrate rose bengal I^{131} . This homograft, which weighed 464 grams when transplanted, was only 80 grams at autopsy on the thirty-second postoperative day.

it will be noted that the atrophied homograft concentrated gold as well as did the autologous liver, despite the fact that a rose bengal scan earlier on the same day had not demonstrated the auxiliary liver (Fig. 2b). Similarly, in the dog followed up for 49 days, no rose bengal concentration occurred in the homograft at that time, although the homograft was easily detectable with a gold scan.

Group 3B.—In both dogs, marked rises occurred in serum glutamic oxalacetic transaminase, serum glutamic pyruvic transaminase, and alkaline phosphatase and in 1 of the 2, jaundice developed before death. The homografts did not pick up rose bengal at any time after 1 week. One of the dogs had a gold scan at 19 days which failed to show the homotransplanted liver.

Group 4.—The 5 dogs which survived beyond 1 day became jaundiced and rises occurred in serum glutamic oxalacetic transaminase, serum glutamic pyruvic transaminase, and alkaline phosphatase. Five dogs died either of pulmonary complica-

tions, liver failure, or sepsis within 30 days, and 1 dog with hepatic failure was sacrificed at 37 days.

Group 4A.—One dog studied 16 hours postoperatively showed a good pickup of rose bengal in the autologous liver and the homograft. The other 2 dogs were not studied until the third and fourth weeks postoperatively. In 1, visualization of the homograft was faint, with both rose bengal and gold. The other was studied only with gold, and the homograft could not be visualized.

Group 4B.—One dog was studied immediately after homotransplantation. Good concentration of both rose bengal and gold was noted in both livers. Within 7 days, a marked reduction occurred in homograft isotope concentration, and after 20 days, the homograft could no longer be detected with rose bengal. Late studies were not carried out with gold.

Group 5.—The dogs were followed up from 1 to 193 days, 3 ultimately being sacrificed.

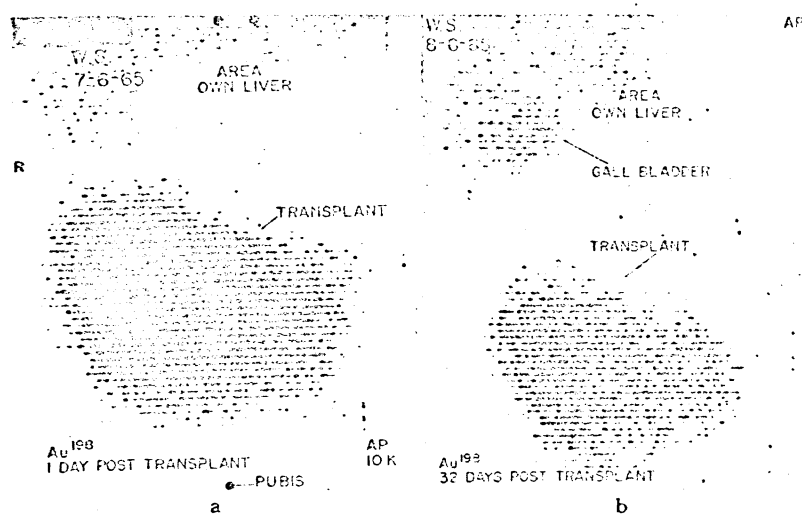


FIG. 3. Human auxiliary hepatic homograft demonstrates better uptake of Au¹⁹⁸ by the transplant than by the host liver on the first (a) and thirty-second (b) days. b, Note residual rose bengal I¹³¹ in gallbladder from scan performed 4 days before.

Group 5A.—In 1 dog studied immediately after operation, concentrations of rose bengal and gold were equivalent in the 2 livers; in another, equal distribution of gold was observed. Three dogs retained reduced but definite rose bengal concentration for as long as 25 days. The 3 dogs in which ligation of their own common duct had been carried out all became jaundiced. One dog without a ligated host common bile duct was followed up with scans for as long as 91 days without any return of homograft visualization with rose bengal.

Group 5B.—In 2 dogs, rose bengal concentration was not detectable in the homograft after 10 days, although in a third dog the dye was faintly detectable after 3½ weeks. The 3 dogs in which the homograft could not be visualized after 1 and 1½ months and in which, then, their own common ducts were ligated were followed up for as long as 40 days thereafter; dye concentration of rose bengal by the homograft never returned.

CLINICAL RESULTS

PATIENT 1. A patient who had nutritional cirrhosis received an auxiliary hepatic homograft on 20 February 1965. After operation, the bilirubin fell from 24.6 to 7.5 milligrams per cent. On the tenth

day, the bilirubin slowly began to rise again, finally reaching a peak of 16.6. Other details of the patient have been reported elsewhere (2). The patient died on the twenty-second postoperative day of pulmonary sepsis.

On the nineteenth postoperative day, a rose bengal scan was obtained which showed no visualization of the homograft and reduced concentration in the patient's own cirrhotic liver. Later on the same day, an Au¹⁹⁸ scan yielded similar findings.

The histologic features of the homograft included slight to moderate infiltration of the portal tracts by mononuclear cells, fibrinoid changes in the wall of several small branches of the hepatic artery, bile stasis, depletion of glycogen in hepatocytes, and atrophy of hepatocytes immediately adjacent to the central veins. Intrahepatic bile stasis was the most prominent abnormality.

PATIENT 2. Auxiliary homograft transplantation was performed on 5 July 1965. The bilirubin fell from 24.6 to a low of 4.5 milligrams per cent before a rejection crisis was diagnosed on the fourth postoperative day. After this, serum bilirubin slowly rose to a high of 18 milligrams per cent. Other features of the patient are described elsewhere (2).

One day postoperatively, a gold scan revealed intense concentration in the homograft, compared to the cirrhotic autologous liver (Fig. 3a). On the eleventh postoperative day after most of the gold had cleared from the liver, a rose bengal scan was performed and it also showed a greater concentration in the homograft; this examination was carried out after the clinical rejection had started. Rose bengal scans on the fourteenth, twenty-first, and twenty-eighth days continued to show the homograft uptake to be

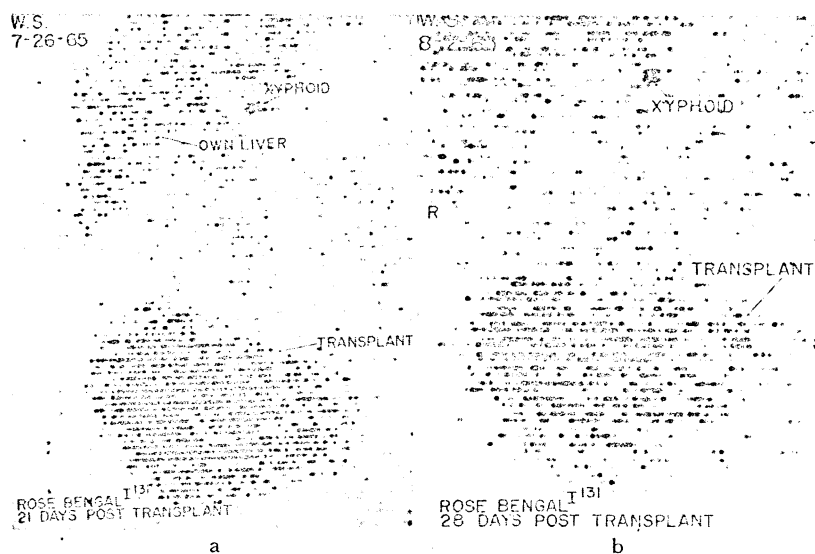


FIG. 4. Human auxiliary hepatic homograft at 3 (a) and 4 weeks (b) after transplantation demonstrates better uptake of rose bengal I¹³¹ by the transplant than by the host liver.

as much as, or distinctly more than, the patient's own liver (Fig. 4a and b). On the thirty-second day, a second gold scan also visualized the homograft better than the autologous liver (Fig. 3b).

The patient died 34 days after homotransplantation. Histologic examination of the homograft at autopsy showed hemorrhagic necrosis of the centrilobular hepatocytes accompanied by collapse and condensation of the centrilobular reticulin, marked centrilobular and midzonal cholestasis with large bile "thrombi," much fat in hepatocytes in the middle and peripheral zones, and cytomegalic inclusion disease affecting biliary epithelial cells.

PATIENT 3. Homotransplantation was carried out on 3 November 1965. After revascularization, the gross appearance of the liver suggested multiple small parenchymal infarcts. The wound was, therefore, closed and the child taken to the radiology department for a gold scan. Almost none of the isotope appeared in the homograft, but the child's own liver, the site of biliary atresia, was well visualized (Fig. 5).

The patient was returned to the operating room and the auxiliary liver removed. Shortly thereafter, a cardiac arrhythmia developed and the child died. Histologic examination of the excised homograft showed intrahepatic thrombosis of the portal venous and hepatic arterial branches. There were numerous hemorrhages in and around the portal tracts as well as multiple areas of hemorrhagic infarction.

DISCUSSION

Although scintillation scanning of the liver has been employed for years, the po-

tential usefulness of this procedure after auxiliary hepatic homotransplantation has not previously been explored. That the method might have value was suggested by Leger and his associates who reported auxiliary homograft concentration of Au¹⁹⁸ as long as 3 months after canine homotransplantation.

The present studies indicate that the greatest application of the scanning techniques in studying auxiliary liver homografts will be early after operation. During the first few postoperative hours in dogs, the image of the second liver was comparable or more prominent than that of the autologous organ, despite considerable variation in the techniques of revascularization. Homograft viability can thus be demonstrated at a time when such information is of the utmost practical importance. In 2 of the 3 clinical patients, early liver scans were obtained. In 1, the expected good radioisotope concentration was present. In the other, the failure to visualize the auxiliary liver suggested that the homograft had been irreparably injured, a conclusion which was confirmed by subsequent histologic studies after extirpation.

Late in the postoperative course, interpretation of an auxiliary hepatic scan is difficult. In general, the ability of the homograft to concentrate the isotope was progressively lost with the passage of time. Since its elimination is dependent upon parenchymal function, it is not surprising that rose bengal isotope concentration was lost earlier than that of gold in several dogs.

The late diminution of auxiliary homograft function is probably due to more than one factor. In earlier work (5), it was shown that with 2 co-existing livers, either organ was capable of injuring the other by a non-immunologic mechanism, as a result of competition for metabolic substrate. That organ with the most ideal blood supply operated at a physiologic advantage. The degree of injury imposed upon either the autologous liver or the homograft was at least partially dependent upon the method of revascularization. In the present experiments, it might be suggested that a similar phenomenon was noted in that the 2 livers shared the radioisotope used for testing.

The progressive inability of an auxiliary liver homotransplant to concentrate radioisotope may not, therefore, solely reflect the influence of rejection. Similar conclusions have been reached by Mizock and his associates in studies of thyroid transplantation in which a functional interrelationship was observed between autologous and homotransplanted thyroid tissue. In these experiments, the histologic evidence of rejection in heterotopic homografted thyroid tissue was frequently minimal at a time when isotope uptake had ceased. The functional life of the homograft could be prolonged by excision of the dog's own thyroid. In a general way, the observations in the present study and those of Mizock and his associates support the concept of the Halsted law of deficiency.

This, of course, does not suggest that rejection is without influence upon hepatic uptake of either rose bengal or gold, and, in fact, progressive and marked changes were detectable in dogs which received orthotopic

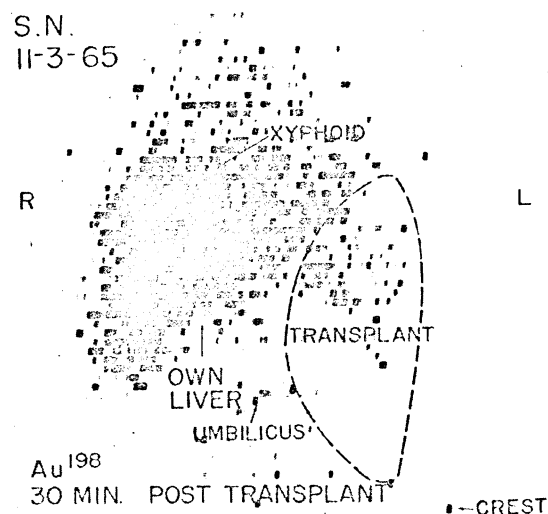


FIG. 5. Severely damaged human auxiliary hepatic homograft in a 16 month old child shows negligible uptake of Au¹⁹⁸ immediately after operation. The superior portion of the homograft occupies the bed of the previously excised spleen.

transplantation and who did not receive immunosuppressive therapy (1). In the latter experimental preparation, the interaction of an autologous liver with the homograft is eliminated, and the alterations observed are clearly ascribable to immunologic repudiation of the graft. Even with the orthotopic operation, however, standard liver chemistries provide a much more sensitive index of the course of the homograft than do the scans.

SUMMARY

Liver scans were used to study auxiliary hepatic homografts in dogs and man. On the day of transplantation, the uptake of rose bengal I¹³¹ and Au¹⁹⁸ by the transplanted canine liver was excellent with all methods of revascularization employed. The ability of the transplant to concentrate the isotopes was thereafter progressively lost, the rose bengal scan being affected at an earlier time than that of the gold.

Three patients received scans after auxiliary hepatic homotransplantation. Gold scans within 1 day of transplantation visualized the homograft in 1 of 2 patients

examined. The transplant which failed to illuminate was promptly removed and found to contain extensive irreparable damage. Two of the patients were examined late after transplantation. One, studied after 19 days, did not have either gold or rose bengal visualization of the auxiliary homograft. The other patient was studied at frequent intervals from 1 to 32 days postoperatively and was found to have excellent preservation of gold and rose bengal isotope concentration throughout the entire period of the study.

The greatest use of scintillation scanning techniques after auxiliary hepatic homotransplantation appears to be during the early postoperative course and primarily for the demonstration of homograft viability. Scans obtained at a later time are difficult to interpret.

REFERENCES

1. FARIS, T. D. Late function of the orthotopic liver homograft. In preparation.
2. HALGRIMSON, C. G., MARCHIORO, T. L., FARIS, T. D., PORTER, K. A., PETERS, G. N., and STARZL, T. E. Clinical and experimental auxiliary hepatic homotransplantation with emphasis on host portacaval shunt. *Arch. Surg.*, 1966, 93: 107.
3. HALSTED, W. S. Auto- and isotransplantation of parathyroid glandules. *J. Exp. M.*, 1909, 11: 175.
4. LEGER, L., MARCENAC, N., MATHÉ, G., PATEL, J.-Cl. and others. État actuel de notre expérience de la transplantation hépatique chez l'animal. *Mem. Acad. chir., Par.*, 1965, 91: 289.
5. MARCHIORO, T. L., PORTER, K. A., DICKINSON, T. C., FARIS, T. D., and STARZL, T. E. Physiologic requirements for auxiliary liver homotransplantation. *Surg. Gyn. Obst.*, 1965, 121: 17.
6. MIZOCK, B. J., FERGUSON, D. J., and HARPER, P. V., Jr. An application of thyroid scanning to the study of transplantation. *Surg. Forum, Clinical Congress 1965*. Vol. XVI, p. 226. Chicago: American College of Surgeons, 1965.
7. STARZL, T. E., MARCHIORO, T. L., PORTER, K. A., FARIS, T. D., and CAREY, T. A. The role of organ transplantation in pediatrics. *Pediat. Clin. N. America*, 1966, 13: 381.
8. WELCH, C. S. A note on transplantation of the whole liver in dogs. *Transpl. Bull.*, 1955, 2: 54.