

THE DIAGNOSIS AND TREATMENT OF HYPERPARATHYROIDISM AFTER RENAL HOMOTRANSPLANTATION

W. P. GEIS, M.D., M. M. POPOVTZER, M.D., J. L. CORMAN, M.D.,
C. G. HALGRIMSON, M.D., F.A.C.S., C. G. GROTH, M.D., and
T. E. STARZL, M.D., F.A.C.S., Denver, Colorado

SECONDARY HYPERPARATHYROIDISM has been reported by Stanbury and Lumb (21, 22) and Masary and his associates (14) to be present in most patients with chronic renal failure. After successful renal homotransplantation, it has been said by several investigators, including Alfrey and his colleagues (1) and Johnson and his co-workers (9, 10) that resolution of this hyperparathyroidism occurs almost universally. With conservative management, severe hypercalcemia after renal transplantation has been uncommon, and the dogma has become well established that parathyroidectomy is seldom required.

This conservative attitude was based upon relatively short term observations of renal recipients. In our center, there has been a growing realization that occult persistent hyperparathyroidism can be a major cause of morbidity, even more than five years after renal transplantation and in spite of multiple normal serum calcium concentrations. This article was undertaken, therefore, in order that the diagnosis of this complication might be described.

The second reason for this study is to discuss the surgical therapy of post-transplantation hyperparathyroidism which, in every one of our 18 patients, has been due to diffuse and multiglandular hyperplasia. Classic subtotal parathyroidectomy has been performed in half of our patients, and in the remainder, all the parathyroid tissue has been excised and a fraction of one gland returned as a free autograft. The advantages of both approaches for both long term and short term management will be mentioned.

From the Departments of Surgery and Medicine, University of Colorado School of Medicine, and the Veterans Administration Hospital, Denver.
This work was supported by research grants from the Veterans Administration, by grants No. RR-00051 and No. RR-00069 from the general clinical research centers program of the Division of Research Resources, National Institutes of Health, and by grants No. AI-AM-08898 and No. AM-07772.

METHODS *Patient Material and Analyses*

Several hundred recipients of renal homografts are having follow-up studies done in our clinics from one month to ten years postoperatively. Of this total, 90 were screened during the last 18 months for hyperparathyroidism, with total serum calcium and ionized serum calcium determinations. Many of the patients also had measurement of 24 hour urine calcium excretion. None of the recipients who eventually were surgically treated for hyperparathyroidism were consistently hypoproteinemic, and even transient hypoproteinemia was diagnosed only two times. In our routine laboratories, the normal range for total serum calcium in persons with normal serum proteins is 8.8 to 10.8 milligrams per 100 milliliters by atomic absorption spectrophotometry and the concentration of ionized calcium, as determined by Orion® ion exchange electrode, is 4 to 4.9 milligrams per 100 milliliters.

In our transplant program, the population sample of 90 screened patients was not completely random, in that entry into the study was made more likely if a patient lived in or around Denver and, consequently, was receiving routine care at the University, if his or her clinical condition was not completely stable or satisfactory, if there were significant musculoskeletal complaints, and if the patients were in the relatively early phases of post-transplantation convalescence. Conceding this bias, the number of patients who eventually underwent a parathyroidectomy was 18 of 90. Fifteen of the 18 patients who underwent parathyroidectomy were treated with orally administered phosphate supplements, as recommended by Alfrey and his associates (1) and Johnson and his colleagues (9, 10). In all 15 recipients, 120 milliliters per day of the liquid antacid, aluminum phosphate gel (Phosphaljel®) were given and, in a few instances, K-Acid-Phosphate® (potassium acid phosphate) was administered with

TABLE I.—CLINICAL DATA ON EIGHTEEN RENAL TRANSPLANT RECIPIENTS AFTER PARATHYROIDECTOMY

Age, yrs.	Creatinine clearance after transplantation, ml./min.	Interval between transplantation and parathyroidectomy, mos.	Radiographic findings before parathyroidectomy		
			Bone disease		Extra-skeletal calcification
			Osteoporosis	Osteitis fibrosa	
41	95	2	+	—	Vascular
22	70	7	—	—	—
21	81	14	+	—	Vascular
10	55	18	+	—	Vascular
39	49	20	+	—	—
43	90	32	+	+	Soft tissue
27	54	47	+	—*	Vascular, skin
30	90	54	+	—	—
17	50	63	+†	—	Vascular, soft tissue
13	51	53	+	—	—
30	53	6	+	+	—
48	89	6	—	+	Vascular
32	64	18	+†	—	—
11	46	19	+	+	Soft tissue
39	74	39	+	—	—
24	87	44	+	—	—
40	75	2	+	—*	Vascular
39	71	12	+†	—	—

* Osteitis fibrosa cystica histologically.

† Aseptic necrosis femoral head.

+, Presence of radiographic bone disease.

—, Absence of radiographic bone disease.

the daily provision of 0.5 to 1.5 grams of elemental phosphorus. Many of these patients, as well as numerous others who did not undergo parathyroidectomy, also had phosphorus concentrations determined in the urine and serum, using an autoanalyzer.

Every one of the screened patients had renal function measurements, including blood urea nitrogen, serum creatinine, and creatinine clearance. The skeletons of almost all the recipients were examined by radiographic bone surveys or by study of the bones by other roentgenographic procedures, such as intravenous pyelograms, gastrointestinal series, or routine chest examinations.

The clinical data on the 18 patients who eventually underwent parathyroidectomy from two to 63 months after transplantation are listed in Table I. Before transplantation, all of these recipients had renal failure, for at least several years, from glomerulonephritis, pyelonephritis, medullary cystic disease, or polycystic disease, and in all but one patient hemodialysis was required. Their kidneys were obtained from 13 related and five cadaver donors, and all these grafts were still providing life-supporting function. Radiographic evidence of bone disease was present in 17 of the 18 patients, invariably including bone rarefaction. However, ten patients also had radiographic or pathologic evidence of osteitis fibrosa cystica or extraskeletal calcification in arteries or soft tissues, or both.

In patients admitted to the hospital for parathyroidectomy, total and ionized serum calcium, phosphorus, creatinine, and blood urea nitrogen concentrations were obtained for three consecutive

days along with 24 hour determinations of urine calcium, phosphorus, and creatinine. Creatinine clearance, Ccr, and phosphate clearance, Cp were calculated in milliliters per minute, and the per cent tubular phosphate reabsorption, TPR, was derived from the formula

$$\text{TPR} = (1 - \text{Cp}/\text{Ccr})100.$$

After parathyroidectomy, the same daily measurements were obtained for at least ten days and intermittently thereafter for a maximum of 16 months.

Technique of Parathyroidectomy

Subtotal parathyroidectomy. The thyroid and parathyroid glands were explored through the standard collar incision popularized by Halsted (7). A thorough search was made for the parathyroid glands. After identifying these, a gland with an easily identifiable arterial supply was subtotally amputated with a razor or scapel, leaving the small remnant on a vascular stalk. Bleeding from the raw surface was controlled with vascular suture or cautery. Only after visually establishing the viability of the remnant were the other glands completely excised. If an accident occurred to the remains of the original gland, additional opportunities thereby remained available until the last moment.

In seven of the nine patients treated in this way, four glands were found, and, in the other two, there were three identifiable parathyroids.

Autotransplantation. The same surgical incision was used (Fig. 1) with somewhat more complete

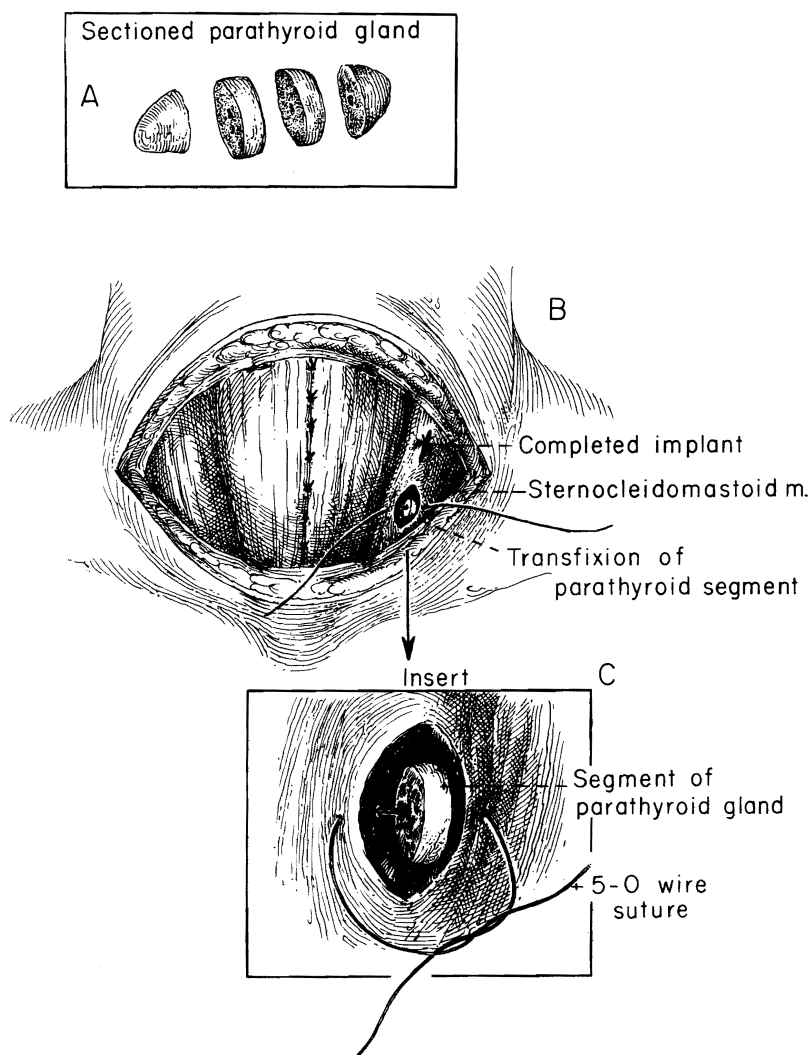


FIG. 1. Technique of parathyroid autotransplantation. A, The gland is removed and sliced. B and C, Two of the slices are inserted into small pockets of sternocleidomastoid muscle and marked with No. 5-0 stainless steel wire.

exposure of the left sternocleidomastoid muscle. After isolation of all of the parathyroid glands, these were completely removed. Two slices of one gland were fixed deeply within the sternocleidomastoid muscle, using No. 5 stainless steel wire to facilitate later identification of the implantation site, should that become necessary. Four glands were found in six of the nine patients treated with autotransplantation. Three glands only were found in two others, and five glands in the last one.

Treatment After Parathyroidectomy

Postoperatively, the serum calcium value was allowed to decline to 7 to 8 milligrams per 100

milliliters, or until hypocalcemic symptoms occurred.

Then, 450 milligrams of elemental calcium in the form of calcium gluconate were administered intravenously during a three hour interval. Concurrently, calcium was orally administered every hour at an initial dose of 300 to 400 milligrams elemental calcium per hour given as calcium gluconate or calcium lactate. Later, during the convalescence, the orally administered calcium supplement was slowly decreased over several weeks or months at a rate consistent with maintenance of the total serum calcium between 8 and 9 milligrams per 100 milliliters.

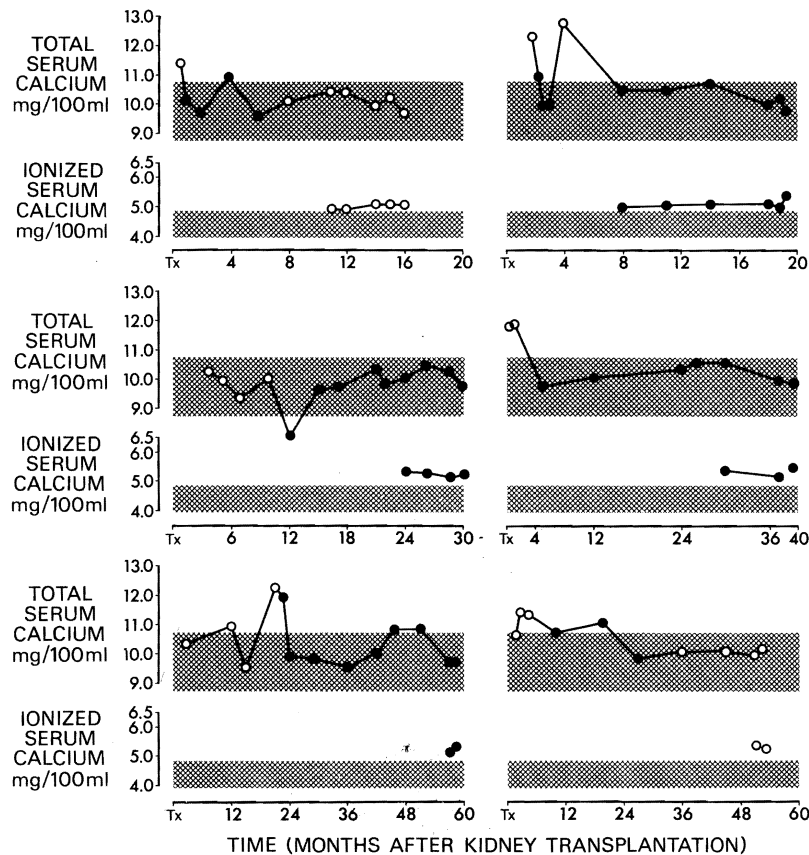


FIG. 2. Course of total serum calcium and ionized serum calcium in six patients prior to parathyroidectomy. The most consistent evidence of hyperparathyroidism was in the ionized calcium. Solid circles indicate that phosphate supplementation was being tried. Open circles denote the absence of phosphate supplementation.

RESULTS

Preoperative and Operative Findings

Total and ionized calcium studies. Six of the patients had a diagnosis of hyperparathyroidism primarily because of a persistent elevation of the ionized serum calcium value (Fig. 2). In five of the six patients, the total serum calcium level initially had been high, but this fell promptly with the phosphate supplementation by means of the orally administered antacid, Phosphaljel. Nevertheless, the ionized calcium value remained elevated. In the sixth patient, the ionized calcium level was high, although total calcium value never was elevated.

A second group of six patients had total calcium levels that apparently were beneficially influenced by phosphate supplementation (Fig. 3). However, the control of the total calcium value was incomplete, with secondary rises, despite active treatment or with recurrence of hypercalcemia after discontinuance of phosphate therapy. All six of these

patients had sporadic or continuously elevated ionized calcium, with or without phosphate therapy.

The final six patients had uncontrolled hypercalcemia either because they did not respond to phosphate therapy (Fig. 4a) or because they were not so treated (Fig. 4b). The ionized calcium values were elevated throughout in the five patients in whom they were measured.

A direct relationship of the total serum calcium to the ionized calcium concentrations is shown in Figure 5 for all samples in 17 of the 18 patients in which both determinations were obtained. The plotted data can be divided into four subgroups within the total pool of 109 samples contributed by the 17 patients. The samples in the right upper quadrant containing 35 per cent of the samples had abnormally high total calcium, as well as ionized calcium, values, so that either of these chemical determinations would have revealed what proved to be a hyperparathyroid state. In contrast, the

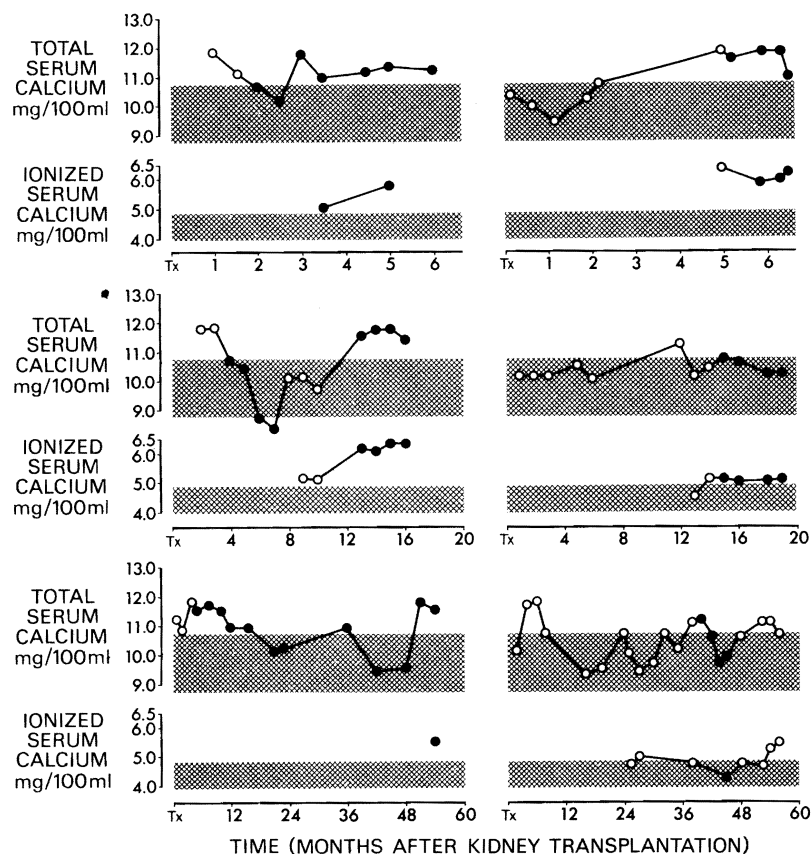


FIG. 3. Course of total serum calcium and ionized serum calcium in six patients prior to parathyroidectomy. Solid circles indicate that phosphate supplementation was in effect, and the open circles denote the absence of such therapy. Note that the hypercalcemia was reduced by the phosphate treatment.

left upper quadrant containing 44 per cent of the samples, had abnormally high ionized calcium values but with normal total calcium levels, as defined by an upper normal limit of 10.8 milligrams per cent. In this group, the standard total calcium determinations would have missed the diagnosis. In almost all the samples in the two lower quadrants, both the total and ionized serum levels were considered to be normal.

It also was considered whether or not the calcium changes were positively correlated with the steroid dosages used after transplantation. Enough calcium data were present in ten of the 18 patients of the reported series to permit examination of this question, and, in addition, two other well studied patients who did not undergo parathyroidectomy were included (Fig. 6). The total serum calcium levels tended to become elevated in these 12 patients as the prednisone dosages were reduced (Fig. 6). This observation could be interpreted as an indication that high dosages of glucocorticoids

might have suppressed hypercalcemia and that this became apparent only as the dosage of prednisone was reduced.

The effect of phosphate supplementation. Fifteen of the 18 patients eventually submitted to parathyroidectomy were given phosphates orally after hyperparathyroidism was suspected. In four, the serum phosphorus was above 2.5 milligrams per cent before this treatment was started. The other 11 began with serum phosphate concentrations below 2.5 milligrams per cent. With therapy, these concentrations could be raised to above 2.5 milligrams per cent, but, for the most part, the values remained low normal (Fig. 7).

Although the hypophosphatemia and total hypercalcemia often could be alleviated by this kind of phosphate therapy, the consequent effects upon the ionized calcium component were unpredictable. The relationship of the ionized serum calcium to the simultaneously determined serum phosphate on 102 occasions with or without phosphate ther-

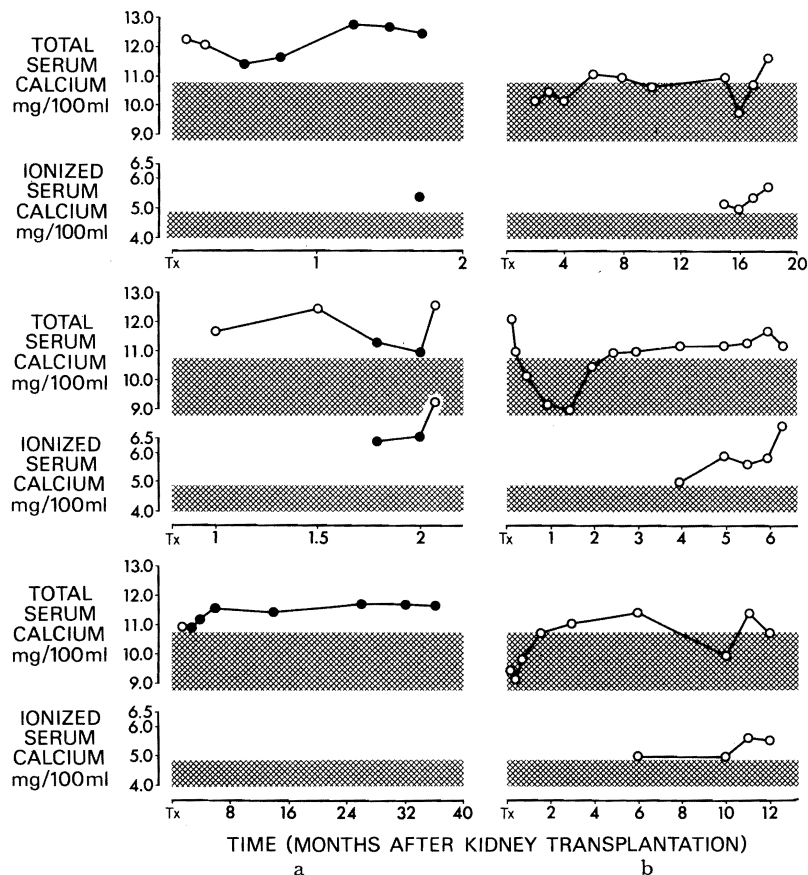


FIG. 4. Course of total serum calcium and ionized serum calcium in six patients prior to parathyroidectomy. a, Solid circles indicate phosphate supplementation, to which there was little or no response; open circles denote absence of this therapy. Ionized serum calcium determinations were not performed in the last patient (bottom graph). b, Note that none of these patients received phosphate supplementation.

apy in 17 of the patients who eventually underwent parathyroidectomy is shown in Figure 8. An inverse relationship between ionized calcium and phosphorus is apparent, but in many instances, normal serum levels of phosphorus were associated with high ionized calcium, an indication that hypophosphatemia was not a prerequisite to the occurrence of high ionized calcium.

In many patients, tubular phosphate reabsorption was determined at the time of ionized serum calcium and the phosphate measurements. If the hypophosphatemia in these patients primarily was due to phosphate depletion rather than hyperparathyroidism per se, the tubular phosphate reabsorption should have been at a maximum in those with hypophosphatemia. The converse actually was true, an indication that the diagnosis was hyperparathyroidism rather than phosphate depletion (Fig. 9). Ionized serum calcium values bore

an inverse relationship to the tubular phosphorous reabsorption (Fig. 10). However, tubular phosphorous reabsorption values in excess of 80 per cent were recorded with abnormally high ionized calcium, emphasizing the limited diagnostic value of tubular phosphorous reabsorption.

Diagnostic accuracy. All 18 patients were unequivocally shown, at the time of parathyroidectomy, to have hyperplasia by criteria of weight and microscopic structure. Histopathologically, the diagnosis in all 18 patients was chief cell hyperplasia, and, in addition, an oxyphil clear cell adenoma was present in one specimen. Moreover, the gland tissue removed weighed from 200 to 2,300 milligrams compared with an expected weight of 120 milligrams, as described by Pappenheimer and Willens (16). These results, which are summarized in Figure 11, indicate a perfect record of preoperative diagnostic accuracy.

Extrarenal complications. According to Stanbury and his co-workers (21, 22) and Massry (14) and his associates, the classical major complications of hyperparathyroidism are osteitis fibrosa cystica, metastatic calcium deposition, and renal function deterioration. Because of the transplant setting, the renal function analyses will be considered separately later on. Ten of the 18 patients had osteitis fibrosa cystica or metastatic calcium deposition, or both. Seven of the remaining eight recipients had only roentgenographic rarefaction as a bone complication and the eighth had no osseous abnormality.

Postoperative Observations

Renal function. Fifteen of the 18 patients had repeated and detailed renal function determinations before and after parathyroidectomy. They were divided into three categories according to the renal functional status before operation and the response afterward.

Four of the recipients had previously stable renal function. The parathyroidectomy had no perceptible subsequent effect (Fig. 12). Four more patients had progressive deterioration of renal function (Fig. 13). After parathyroidectomy, the losses ceased. Finally, seven patients with deteriorating renal function had a reversal of this process after

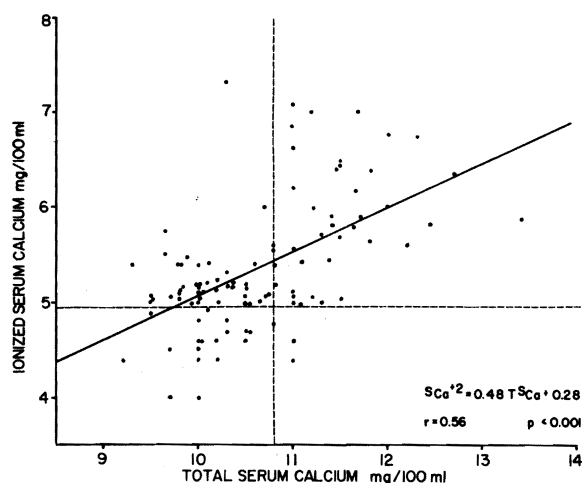


FIG. 5. Relation of the concentrations of total serum calcium to ionized serum calcium in 109 samples from 17 patients. The vertical interrupted line is high normal total serum calcium value, 10.8 milligrams per cent. The horizontal interrupted line is high normal ionized serum calcium value, 4.9 milligrams per cent. The regression line crosses high normal serum ionized calcium where the total serum calcium concentration is 9.75 milligrams per cent.

parathyroidectomy and without intensification of immunosuppressive therapy (Fig. 14).

Subtotal parathyroidectomy. Two of the patients treated with subtotal parathyroidectomy died four

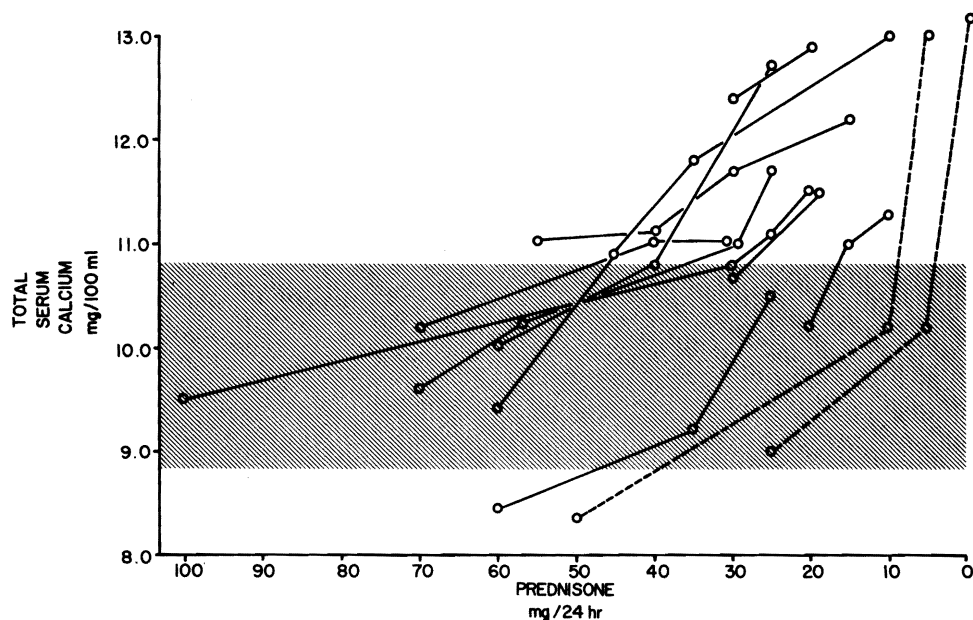


FIG. 6. The relation of daily prednisone dosages to total serum calcium concentration in 12 patients in the absence of phosphate supplementation. The interrupted lines are from two patients who did not undergo parathyroidectomy but who received prednisone rapidly decreased and discontinued due to life-threatening infection. Note that hypercalcemia developed as the steroid dosages were diminished.

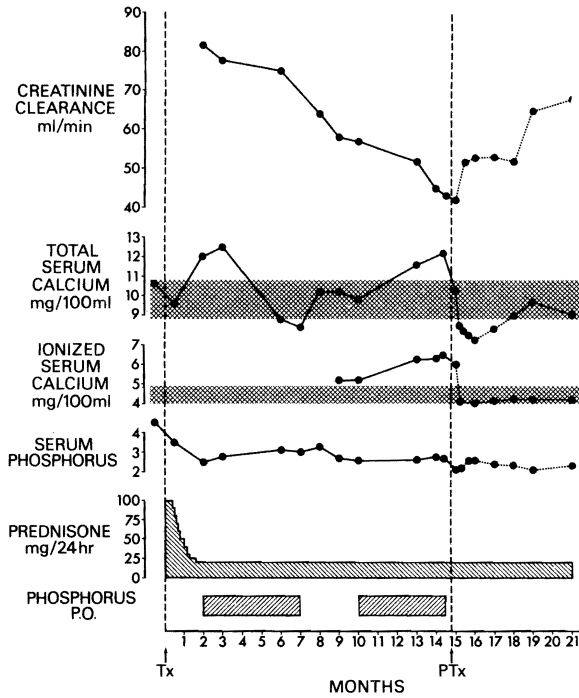


FIG. 7. The creatinine clearance, total serum calcium, ionized serum calcium, serum phosphorus, prednisone therapy, and phosphate supplementation in one patient from the date of transplantation, Tx, to parathyroidectomy, PTx, and then six months afterward. Screened bars are timing of phosphate supplementation. Shaded bars represent the normal range for total and ionized serum calcium.

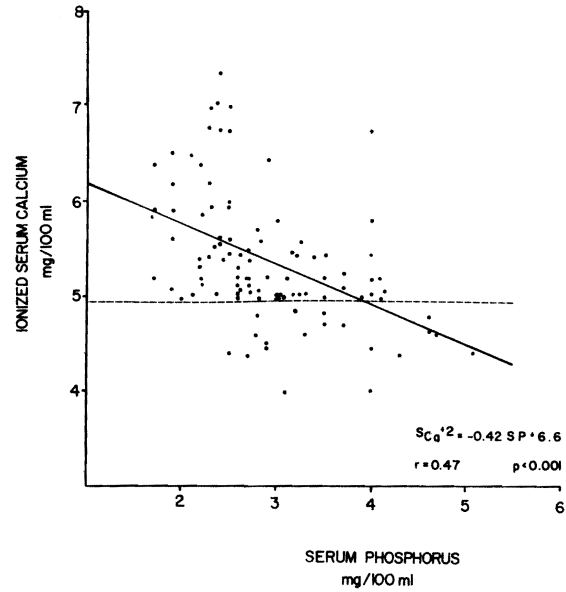


FIG. 8. The relation of ionized serum calcium to serum phosphorus. Some of the patients were receiving phosphate supplementation. Data are 102 points from 17 patients. Interrupted horizontal line denotes upper normal ionized serum calcium value. Regression line crosses upper normal ionized serum calcium at a serum phosphorous concentration of 4 milligrams per cent.

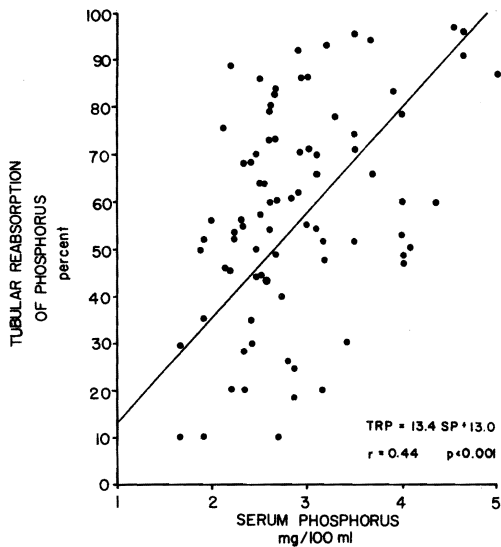


FIG. 9. The relation of serum phosphorus to tubular reabsorption of phosphorus. Regression line suggests a direct though imperfect correlation. There are 102 samples from 17 patients.

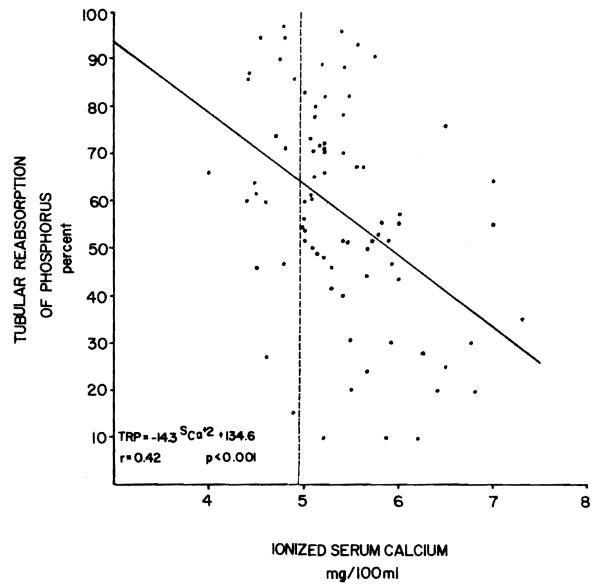


FIG. 10. The relation of ionized serum calcium to tubular reabsorption of phosphorus. The interrupted vertical line denotes the upper limits of normal of ionized serum calcium concentration. The regression line crosses the upper normal of ionized serum calcium at a tubular phosphorous reabsorption of 64 per cent.

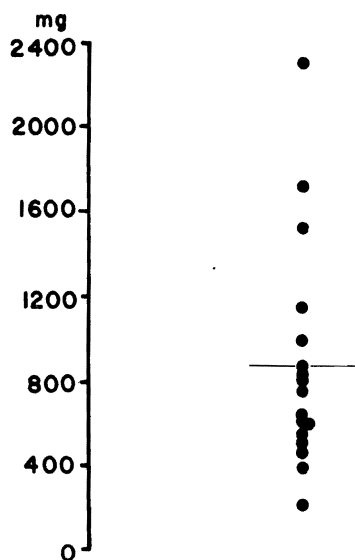


FIG. 11. The weights of parathyroid glands removed from 17 patients. The range was from 200 to 2,300 milligrams, with a mean of 875. One weight was omitted, since the total weight was not recorded because one gland was imbedded in the thyroid.

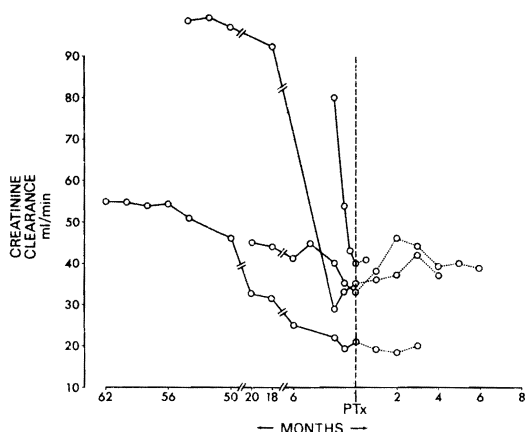


FIG. 13. A stabilizing effect of parathyroidectomy, PTx, upon the deteriorating creatinine clearance of four patients.

months and one month, respectively, after operation. The indication for parathyroid removal in the first patient was widespread cutaneous and subcutaneous gangrene, apparently caused by occlusion of small vessels by metastatic calcium. In spite of the parathyroidectomy, the complication led to death. The mortality a month after parathyroidectomy was caused by a perforated sigmoid diverticulum. In the latter patient, nephrocalcinosis was detected in the transplanted organ at autopsy.

The complete early postoperative data depicted in Figure 15 was obtained in seven of the nine pa-

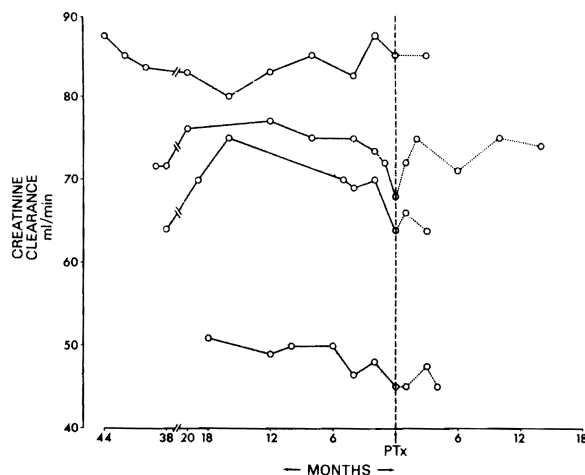


FIG. 12. Lack of effect of parathyroidectomy, PTx, upon the creatinine clearance in milliliters per minute of four patients.

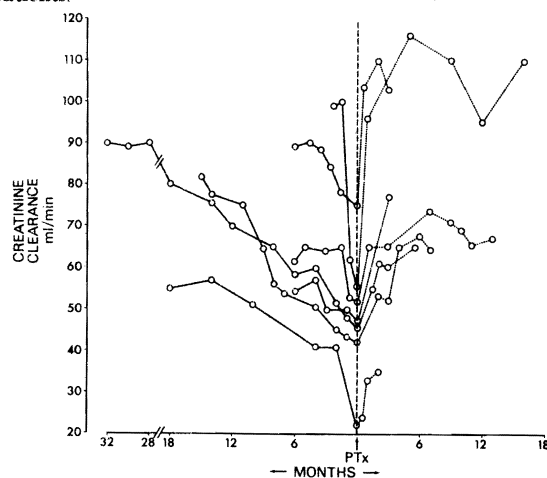


FIG. 14. An improvement of creatinine clearance in seven patients after parathyroidectomy, PTx.

tients in the absence of any calcium supplementation. Observations in three of the patients are not shown after two to four days because of the need for calcium therapy. However, the serum concentrations of both total and ionized calcium eventually became normal in all of these patients.

Tubular reabsorption of phosphorus never became complete in six of the seven fully studied patients and was 100 per cent for only four days in the seventh. With a longer follow-up period, the tubular reabsorption of phosphorus was variable but never 100 per cent. The subtotal parathyroidectomy was not responsible for any examples of hypoparathyroidism. In one patient, the typical biochemical findings of recurrent hyperparathyroidism developed almost a year after the parathyroid extirpation for an incidence of 11 per cent.

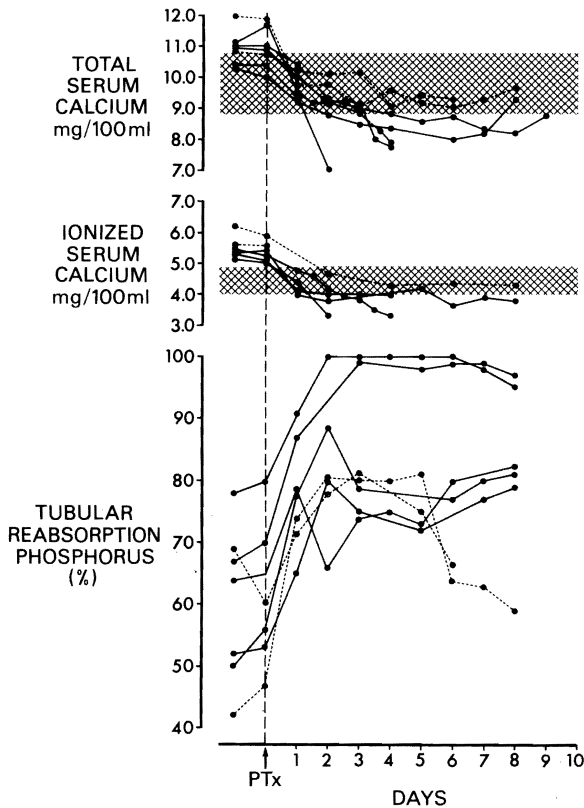


FIG. 15. Total serum calcium, ionized serum calcium, and tubular reabsorption of phosphorus in seven patients who underwent subtotal parathyroidectomy, PTx. The final point on the total calcium curve of three of the seven patients was two to four days after operation and corresponded with the onset of calcium supplementation. The dotted lines indicate two patients in whom only three parathyroid glands were found at exploration but who never required calcium supplementation. In those patients, a fourth gland was probably present.

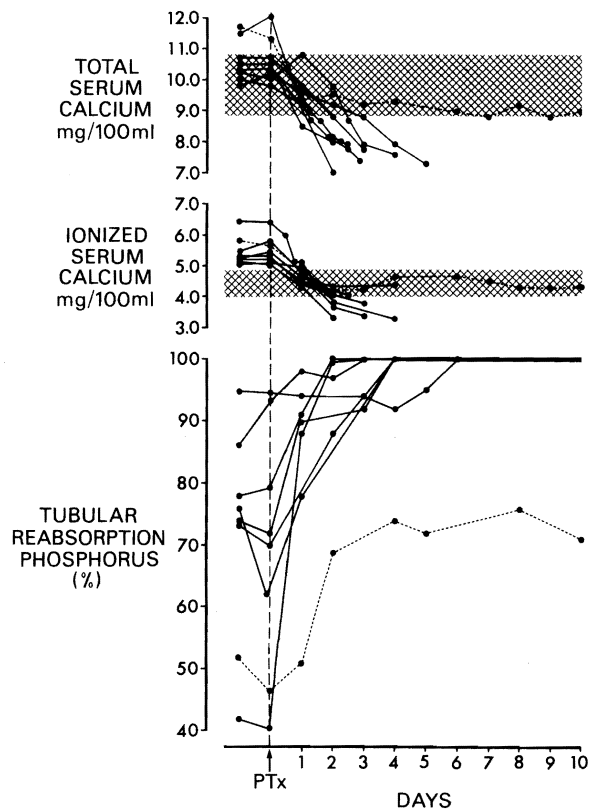


FIG. 16. Total serum calcium, ionized serum calcium, and tubular reabsorption of phosphorus in eight patients who underwent parathyroid autotransplantation. The final point on the total calcium curve in seven of the eight patients was two to five days after operation and corresponded with the onset of calcium supplementation. The interrupted line indicates a ninth patient who had four parathyroid glands removed, never required calcium supplementation, and never reached 100 per cent tubular reabsorption of phosphorus; a fifth gland was obviously present.

Parathyroid autotransplantation. All of these nine patients have survived to date for one to 12 months after operation. The complete biochemical data given in Figure 16 was obtained in eight patients. In one patient, it was obvious that a gland was inadvertently left, in spite of the fact that four glands were removed. This patient did not have 100 per cent tubular reabsorption of phosphorus, and calcium supplementation was not required.

The other seven, completely studied patients promptly exhibited complete tubular reabsorption of phosphorus, usually within two or three days and, at the longest, by six days (Fig. 16). Moreover, there was a need in all seven patients for calcium supplementation.

The course of the calcium therapy is presented in Figure 17 for the first six patients submitted to autotransplantation. Usually, 5 to 10 grams of ele-

mental calcium per day was begun, with an effort to wean the calcium dosage over the ensuing days and weeks. In all six of these patients, it became possible, within a few months, to stop the calcium altogether or to administer it in doses of less than 2 grams per day. The return of tubular reabsorption of phosphorus was further proof of adequate parathyroid function.

However, in one of the recently treated patients, there has been a persistent need for three or more grams per day of elemental calcium to maintain a total serum calcium level above 8. Although the tubular reabsorption of phosphorus in this last patient ranges from 60 to 80 per cent, persistent hypoparathyroidism has been diagnosed for an incidence of one patient in nine. There has been no recurrence of hyperparathyroidism in the autotransplantation group.

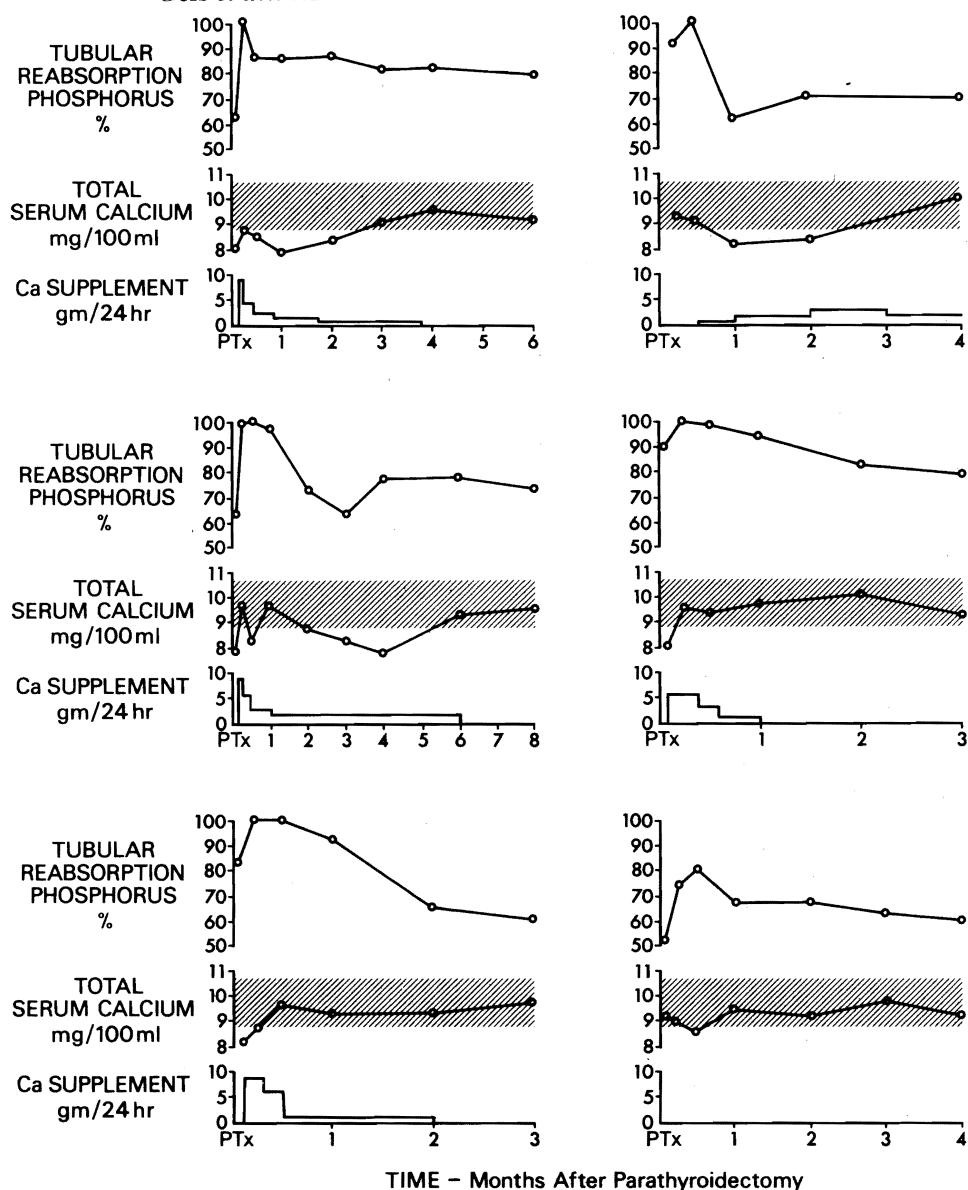


FIG. 17. Total serum calcium and tubular reabsorption of phosphorus or of calcium supplementations in six patients for the first several months after parathyroid autotransplantation. Five of the six required calcium supplementation for one to six months. The last patient, lower right-hand graph, never required calcium supplementation, never reached 100 per cent tubular reabsorption of phosphorus, and apparently had a retained gland.

DISCUSSION

From autopsy studies and clinical observations, it has been well known for nearly a half century that parathyroid hyperfunction is a common finding in patients with chronic renal disease, as summarized by Stanbury and Lumb (21, 22), Massry and his colleagues (14) and Pappenheimer and Willens (16). The pathogenesis of secondary hyperparathyroidism is not well understood. How-

ever, two general mechanisms have been proposed. According to De Luca (6) and Avioli and his co-workers (3), there is an acquired resistance to physiologic amounts of vitamin D, with an abnormal turnover rate of this vitamin leading to a decrease in ionized calcium and, hence, to secondary hyperparathyroidism. Bricker and his associates (4) described a retention of phosphorus due to decreasing nephron population, resulting in increas-

ing serum phosphorous levels with a reciprocal decrease in ionized serum calcium and excessive stimulation of parathyroid hormone secretion. It has been estimated by Reiss and his associates (19) that this latter mechanism comes into play when renal function is reduced to below 80 per cent of its normal value.

It is into this abnormal environment that many renal homografts are placed. Since the early days of renal transplantation, it has been thoroughly appreciated that this secondary hyperparathyroidism may persist into the postoperative period, as described by McIntosh (15), Schwartz and his colleagues (20) and Pletka and his associates (17). Popovtzer and his co-authors (18) have emphasized the difficulty of accuracy in the study of this problem because of the imperfections of the available parathormone assay methods.

The published opinions by Alfrey and his associates (1) and Johnson and his colleagues (9) have been strong that provision of adequate homeostasis with a well functioning renal homograft should reverse the initiating chain of events, that the abnormal stimulus to the parathyroid glands should cease, and that the anatomic and functional aberrations of the parathyroid glands would undergo involution. This impression has gained so much acceptance that it is widely believed that there is rarely any indication for parathyroidectomy after renal transplantation.

The information generated in our center in the last two years and herein reported has caused us to alter this conservative position. Although the exact incidence of sustained hyperparathyroidism cannot be accurately stated in our patient material, it now appears to be in excess of 20 per cent. The insidious feature of this complication has been its occult and subtle nature which, in some instances, particularly in children, has permitted bone changes progressing to the creation of a pariah without ever having biochemically florid hyperparathyroidism.

In our patients, the determination of total serum calcium and phosphorous concentrations has not provided an adequate screening for diagnosis. If an elevation in total serum calcium level were a prerequisite for the diagnosis, in eight of our 18 patients, diagnosis never would have been made. In contrast, the ionized calcium level provided the decisive clue in every patient in which it was measured. Similar observations recently have been published by Low and his associates (13) of the value of ionized calcium determinations to diagnose primary hyperparathyroidism.

So far, the indications for parathyroidectomy after renal transplantation undoubtedly have been

too restrictive. Now, caution must be exercised to avoid too much of a pendulum swing in the other direction. Nevertheless, the ultimate test of the accuracy of diagnosis in such instances should be the unequivocal demonstration of hyperplastic changes in the glands. Histopathologically, this was so in all the parathyroid glands removed in our series, and in addition, these glands weighed from two to 50 times what would have been normal.

It is tempting to speculate about some of the factors contributing to continuance of hyperparathyroidism after relief of uremia by transplantation. Glucocorticoids may exert an indirect effect on parathyroid stimulation. This action would be mediated through suppression of serum calcium level, as described by Jowsey and Balasubramaniam (11) and Laflamme and Jowsey (12). The appearance of hypercalcemia in many of our patients only when the dosage of prednisone was reduced is consistent with this action of glucocorticoids. Recently reported experimental results by Williams and his associates (23) support the notion that glucocorticoids both acutely and chronically may increase the secretion rate of parathyroid hormone.

Alfrey and his associates (1) suggested that in patients after renal transplantation a state of phosphate depletion may develop which could contribute to the development of hypercalcemia. They recommended a trial of repletion with phosphate-containing antacids, such as Phosphaljel or with specific medication, such as potassium-acid-phosphate. This kind of phosphate supplementation probably is worth trying for a short period. But if required chronically, it may recreate the parathyroid stimulus by driving down the serum calcium concentration, or it could, theoretically, aggravate soft tissue calcification, as pointed out by Jowsey and Balasubramaniam (11) and Laflamme and Jowsey (12). Consequently, parathyroidectomy should be strongly considered after a three months' trial of conservative treatment if there is a recurrence of the hyperparathyroid state after phosphates are stopped. The impetus to proceed should be increased if there are serious bone complications in the background or if there is a deterioration of renal homograft function unexplained on immunologic grounds. Almost two-thirds of the patients in the present series had deteriorating renal function prior to parathyroidectomy. After operation, this decline usually was either halted or reversed.

The classical approach to diffuse parathyroid hyperplasia has been complete removal of all but one of the parathyroid glands and subtotal resection of this last gland, as described by Cope (5). The

results with this procedure were satisfactory in the present series, except for a patient in whom there was a recurrence within a year. The advantage of this approach was that no permanent hypoparathyroid states were created and in the fact that the majority of the patients never required calcium supplementations.

The alternative method of autotransplantation, as originally described by Halsted and Evans (8) and recently revived by Alveryd (2), also was given a trial. This technique has a major advantage in that it permits a precise determination by simple metabolic studies carried out within the first post-operative week as to whether or not all the glands had been identified. If all glands were found and removed, the tubular reabsorption of phosphorus should become 100 per cent within a few days. Failure to demonstrate this signifies that the procedure was incomplete. With this test, it was evident that one of the nine patients in our series who underwent autotransplantation had an undetected gland.

In spite of this impressive advantage of autotransplantation, the procedure cannot as yet be recommended for general use because of its potential disadvantages both early and late. Immediately postoperatively, all patients require calcium supplementation for several weeks while the autograft becomes established. Furthermore, failure of the implant to be vascularized could lead to permanent hypoparathyroidism, as may be occurring in one of our most recently treated patients. Finally, it is conceivable that the cicatricial capsule around an established homograft might, in the long run, squeeze off the implant blood supply many months or even years later. Consequently, it is our plan to carefully observe the nine patients thus far treated by autotransplantation for one or two years before making a final judgment. Until then, subtotal parathyroidectomy will remain our first choice.

SUMMARY

In the last 18 months, 90 patients who had been treated successfully from a few weeks to almost ten years previously with renal homotransplantation were screened for hyperparathyroidism with the usual diagnostic techniques and determinations of ionized serum calcium concentrations. Eighteen of the 90 recipients eventually were shown by histopathologic criteria to have diffuse parathyroid hyperplasia. The removed parathyroid tissue weighed 200 to 2,300 milligrams.

Prior to parathyroid excision, the hyperparathyroid state was correctly identified by the elevated

ionized calcium values, whereas the diagnosis often would have been missed if reliance had been placed upon total serum calcium, serum phosphorus, tubular reabsorption of urinary phosphorus, or other determinations. All but one of the 18 patients submitted to parathyroidectomy had bone disease or metastatic soft tissue calcification, and more than half had pronounced deterioration of renal function, which was halted or reversed by relief of the hyperparathyroidism. Before resorting to parathyroidectomy, 15 of the 18 patients were given a trial of orally administered phosphate supplementation. This treatment reduced the total serum calcium concentration but had much less effect on the ionized calcium and, if used chronically, may have perpetuated the stimulus for parathormone secretion.

Nine patients underwent total parathyroidectomy, with parathyroid autoimplantation of segments of one of the hyperplastic glands. The other nine patients had classical subtotal parathyroidectomy. Just after autotransplantation, profound hypocalcemia always occurred with 100 per cent tubular phosphate reabsorption, calcium supplementation being required, which was decreased to a minimum or discontinued after two to six months. One of the nine patients had significant hypoparathyroidism. After subtotal parathyroidectomy, there were no examples of hypoparathyroidism, but there has been one example of recurrent hyperparathyroidism.

These data indicate an alarmingly high incidence of persistent and often occult secondary hyperparathyroidism in renal transplant recipients, which is not effectively treated with phosphate supplementation; the importance of ionized serum calcium determinations in diagnosing this complication; a harmful effect of hyperparathyroidism on transplanted kidneys; and the potential value of parathyroid autotransplantation in these patients to determine the presence of a fifth gland or other retained hyperplastic tissue which may cause recurrence. Subtotal parathyroidectomy will remain the operation of choice for diffuse parathyroid hyperplasia until more information about the long term outcome after total parathyroidectomy and autotransplantation becomes available.

REFERENCES

1. ALFREY, A. C., JENKINS, D., GROTH, C. G., and others. Resolution of hyperparathyroidism after renal homotransplantation. *N. Engl. J. Med.*, 1968, 279: 1349.
2. ALVERYD, A. Parathyroid glands in thyroid surgery. *Acta Chir. Scand.*, 1969, 389: 1.
3. AVIOLI, L. V., BIRGE, S. J., and LEE, S. W. Effects of prednisone on vitamin D metabolism in man. *J. Clin. Endocrinol.*, 1968, 28: 1341.

4. BRICKER, N. S., SLATOPOLSKY, E., REISS, E., and others. Calcium, phosphorus and bone in renal disease and transplantation. *Arch. Intern. Med.*, 1969, 123: 543.
5. COPE, O. The surgery of subtotal parathyroidectomy. *N. Engl. J. Med.*, 1935, 213: 470.
6. DE LUCA, H. F. Role of kidney tissue in metabolism of vitamin D. *N. Engl. J. Med.*, 1971, 284: 554.
7. HALSTED, W. S. The operative study of goitre. *Johns Hopkins Hosp. Rep.*, 1920, 19: 71.
8. HALSTED, W. S., and EVANS, H. M. The parathyroid glandules; their blood supply and preservation in operation upon the thyroid gland. *Ann. Surg.*, 1907, 46: 489.
9. JOHNSON, J. W., HATTNER, R. S., HAMPERS, C. L., and others. Secondary hyperparathyroidism in chronic renal failure, effects of renal homotransplantation. *J. A. M. A.*, 1971, 215: 478.
10. JOHNSON, J. W., WACHMAN, A., KATZ, A. I. and others. The effect of subtotal parathyroidectomy and renal transplantation on mineral balance and secondary hyperparathyroidism in chronic renal failure. *Metabolism*, 1971, 20: 487.
11. JOWSEY, J., and BALASUBRAMANIAM, P. Effect of phosphate supplements on soft tissue calcification and bone turnover. *Clin. Sci.*, 1972, 42: 289.
12. LAFLAMME, G. H., and JOWSEY, J. Bone and soft tissue changes with oral phosphate supplements. *J. Clin. Invest.*, 1972, 51: 2834.
13. LOW, J. C., SCHAAF, M., EARLL, J. M., and others. Ionic calcium determination in primary hyperparathyroidism. *J. A. M. A.*, 1973, 223: 152.
14. MASSRY, S. G., COBURN, J. W., POPOVTZER, M. M., and others. Secondary hyperparathyroidism in chronic renal failure; the clinical spectrum in uremia, during hemodialysis, and after renal transplantation. *Arch. Intern. Med.*, 1969, 124: 431.
15. MCINTOSH, D. A., PETERSON, E. W., and MCPHAUL, J. J. Autonomy of parathyroid function after renal homotransplantation. *Ann. Intern. Med.*, 1966, 65: 900.
16. PAPPENHEIMER, A. M., and WILLENS, S. L. Enlargement of the parathyroid glands in renal disease. *Am. J. Pathol.*, 1935, 11: 73.
17. PLETKA, P., STROM, T., BERNSTEIN, D. S., and others. Secondary hyperparathyroidism in human kidney transplant recipients. *Proc. International Congress of Nephrology*. P. 156 (abstract). Mexico City: International Society of Nephrology, 1972.
18. POPOVTZER, M. M., PINGGERA, W. F., HUTT, M. P., and others. Serum parathyroid hormone levels and renal handling of phosphorus in patients with chronic renal disease. *J. Clin. Endocrinol. Metab.*, 1972, 35: 213.
19. REISS, E., CANTERBURY, J. M., and CATER, A. Circulating parathyroid hormone concentration in chronic renal insufficiency. *Arch. Intern. Med.*, 1969, 124: 417.
20. SCHWARTZ, G. H., DAVID, D. S., RIGGIO, R. R., and others. Hypercalcemia after renal transplantation. *Am. J. Med.*, 1970, 49: 42.
21. STANBURY, S. W. Bone disease in uremia. *Am. J. Med.*, 1968, 44: 714.
22. STANBURY, S. W., and LUMB, G. A. Parathyroid function in chronic renal failure; a statistical survey of the plasma biochemistry in azotemic renal osteodystrophy. *Q. J. Med.*, 1966, 35: 1.
23. WILLIAMS, G. A., BOWSER, E. N., HARGIS, G. K., and others. Effect of glucocorticoids on function of the parathyroid glands in man. *Clin. Res.*, 1972, 20: 780.