

379



Fungus Infections After Liver Transplantation

GERHARD P. J. SCHRÖTER, M.D., MANFRED HOELSCHER, M.D., CHARLES W. PUTNAM, M.D., KENDRICK A. PORTER, M.D., THOMAS E. STARZL, M.D., PH.D.

From the Departments of Pediatrics and Surgery, Veterans Administration Hospital, the University of Colorado Medical Center, Denver, Colorado and the Department of Pathology, St. Mary's Hospital Medical School, London, England

The problem of fungus infections after liver transplantation was studied. In 100 consecutive recipients of orthotopic liver homografts there were 10 and 8 examples, respectively, of localized and disseminated infections caused by *Candida* species. Candidemia was demonstrated in 8 of these 18 patients. One patient who had a localized *Candida* infection also had disseminated cryptococcosis. An additional 31 patients were infected in that *Candida* could be cultured from sites where it is not normally found, such as the blood (8 examples), urine (8), ascitic fluid (8), and wounds (22). This exorbitant incidence of nosocomial infections and infestations was associated with a high frequency of complications involving the homograft as well as the hosts' gastrointestinal tract during the post-transplantation period. The yeasts found in blood, urine, ascitic fluid and elsewhere were thought to have originated from the gut. Ten of the 100 patients had aspergillosis which was localized in 7 instances and disseminated in 3. The lung was the most frequently affected organ. The fungus infections played a contributory role in the downhill course of our patients but in the event of death more fundamental and more frequent causes of failure were technical complications involving the homografts, difficulties in controlling rejection with reasonable immunosuppressive doses and bacterial sepsis. Suggestions have been made for the better control of fungal infections in liver recipients.

IMMUNOSUPPRESSIVE THERAPY renders organ transplant recipients susceptible to a variety of bacterial, fungal, protozoal and viral infections. The fact that many of the infectious complications are similar in recipients of different types of organs is not surprising since the immunosuppressive therapy used is the same. However, it is also clear that the type of organ replaced may cause or be associated with specific infectious problems.^{4,7,17} After orthotopic liver replacement, there has been an unusually high incidence of bac-

teremia originating from infections of the biliary tract, peritoneal cavity or devitalized liver tissue.^{3,16,18}

The present studies were undertaken to determine the special problems with fungal infections in liver transplant recipients, based upon a review of 100 consecutive cases. A more general analysis of the clinical events of the first 93 of these patients was recently published.¹⁴

Methods

The 100 patients received orthotopic liver homografts between March 1, 1963, and May 2, 1975. Congenital biliary atresia, primary hepatic malignancy, chronic aggressive hepatitis and alcoholic cirrhosis were the most common reasons for operation. Retransplantation was attempted in 13 patients because the primary grafts failed for a variety of reasons of which rejection was most common.

Twenty-eight of the 100 patients survived at least one year after operation. At present, 14 patients including one recipient of a second graft (OT 98) are still alive 1¼ to 6½ years after transplantation.

The technical details of the operation¹⁶ and the principles of postoperative care^{14,16} have been described previously. Azathioprine, prednisone and horse antilymphocytic globulin (ALG) were used for immunosuppression. If hepatotoxicity of azathioprine was suspected, cyclophosphamide was substituted since it is thought to have equal immunosuppressive value. Alternatively, cyclophosphamide was used in a number of cases initially with a switch to azathioprine later.

Knowledge of the biliary tract reconstruction is important in understanding the infectious complications.^{14,16} In early cases, cholecystoduodenostomy or choledochocholedochostomy with T-tube stenting was

Submitted for publication June 21, 1976.
The work was supported by research grants MRIS 8118-01 and 1727-01 from the Veterans Administration; by Grant Numbers AM-17260 and AM-07772 from the National Institutes of Health; and by Grant Numbers RR-00051 and RR-0069 from the General Clinical Research Centers Program of the Division of Research Resources, National Institutes of Health; Faculty Scholar, Josiah Macy, Jr. Foundation.
All correspondence: Gerhard P. J. Schröter, M.D., Box C-305, University of Colorado Medical Center, 4200 East Ninth Avenue, Denver, Colorado 80220.

used. In the last 2½ years, Roux-en-Y cholecystojejunostomy has been the preferred procedure even though it often has been necessary to subsequently convert this anastomosis into a choledochojejunostomy because of the development of obstruction at or near the cystic duct.^{6,13,15} The objective of using a defunctionalized loop of jejunum to accept biliary drainage has been to reduce biliary contamination. As an alternative procedure for selected cases, choledochocholedochostomy with a T-tube is still used.

During operation and for various intervals afterwards endotracheal tubes, central venous catheters, arterial lines, nasogastric tubes and Foley catheters were in place. Chest tubes were inserted if a combined abdominothoracic approach was necessary. Surgical incisions usually were closed primarily without drains. Wounds were drained if the operations were performed in the presence of infection, if the biliary anastomosis was to the homograft common duct, or if hemostasis was not satisfactory. When secondary operations became necessary because of biliary obstruction or fistula, the wounds were left partly open and allowed to granulate in.

The operations were carried out under broad spectrum antibiotic coverage with a combination of Methicillin, Ampicillin and Kanamycin. Cephalothin, Carbenicillin or Gentamicin occasionally were substituted with special indications. Intensive and prolonged therapy with a variety of antibiotics frequently was necessary later for documented or suspected bacterial infections.

Nystatin oral suspension and tablets were given routinely as soon as oral intake permitted and as long as the patients received antibiotics and/or high doses of corticosteroids. Intravenous Amphotericin B in gradually increasing doses up to 0.75 mg/kg or oral 5-Fluorocytosine in doses of 150 mg/kg/day were used individually or together to treat suspected or documented fungal infections.

Data about fungus colonization or infection were collected from routine cultures of throat, sputum, nasotracheal aspirates, stool, urine, blood, wound, wound drainage, infected body space and tissue. The microorganisms were isolated and identified by standard procedures in the clinical microbiologic laboratories. For recording the data, orthotopic transplant (OT) numbers were used throughout. The use of this coding system permits individual patients to be identified in various of our publications and to be followed from article to article.

Culture data and histopathologic studies were used for a classification of colonization, infestation, or infection. The designation of infection was used only if tissue invasion was proved and required tissue biopsy

or autopsy examination. The presence of *Candida albicans* or other yeasts in sites such as oral cavity, upper respiratory tract or gastrointestinal tract was defined as colonization since yeasts can be normal inhabitants of these places. No special significance was attributed to the results of tracheal aspirates since the nasotracheal catheters were inserted through a contaminated field. Transtracheal aspiration which would have avoided this contamination was not employed. Since they do not normally grow in these locations, yeasts in wounds, drain sites, bile or peritoneal fluid were considered to represent infestation if relative tissue damage was not documented. The finding of more than 10⁵ col/ml of yeasts in the urine was called infestation as were positive blood cultures if there was no other evidence of local or systemic *Candida* infection.

Results

Fungus infections were seen that were caused by yeasts, *Aspergillus* species and *Cryptococcus neoformans*. Figure 1 shows examples of all 3 of the invasive fungi.

Yeasts

Almost all of the yeasts were *Candida albicans* but in a few instances other yeasts such as *Candida tropicalis*, *Candida kruzei*, or *Torulopsis glabrata* were identified. In reporting, these were grouped together as *Candida albicans*.

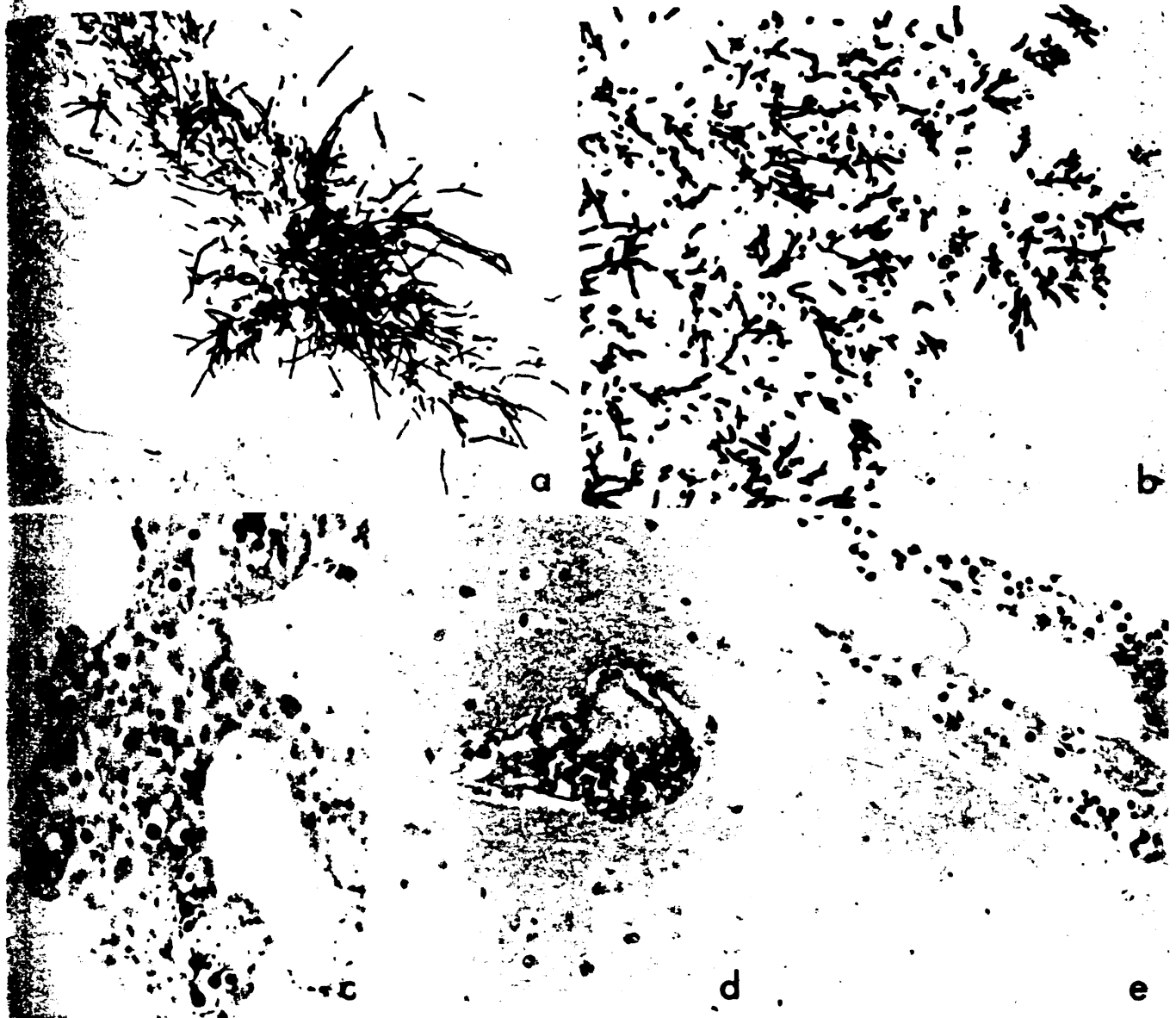
Preoperative Studies. The charts of 64 of the recipients contained the results of routine preoperative cultures. Twenty-three (36%) of these 64 patients harbored *Candida* species. In all 23 recipients the positive preoperative cultures of *Candida* were obtained from the upper respiratory tract, 4 had the *Candida* in urine as well, and 2 also had positive cultures from blood samples.

Postoperative Infection. Eighteen of the 100 patients developed *Candida* infection during the postoperative period (Table 1). The infections were localized in 10 cases and disseminated in the other 8. The diagnosis of a yeast infection was suspected during life in many of these patients, but usually neither a definitive diagnosis nor a full delineation of the location(s) and extent of the process was possible until autopsy.

The 10 localized infections are summarized in Table 1. Yeast infections were confined to the peritoneal cavity in 4 patients (OT 17, 47, 63, 81) although in 3 of these (OT 47) there was associated candidemia. In 2 peritoneal infections were subhepatic, subphrenic, or peripancreatic in location. Pure cultures of *Candida albicans* were grown from the abdominal drain-

... la to e.
... autopsy. a. OT
... *neoformans* in lu
... (m. d) and n

... in 2 of t
... there was c
... There we
... the brain (Fi
... and subcuta
... subcutaneot
... *neoformans*
... after spread
... ms. and a
... associated
... Di. emina
... ery helmi



FIGS. 1a to e. Disseminated fungal infections in three recipients of liver allografts. The fungi appear as black bodies in tissues obtained at autopsy. **a.** OT 36. *Candida albicans* in kidney. Grocott's modification of Gomori's methenamine silver stain ($\times 180$). **b.** OT 19. *Aspergillus fumigatus* in lung. Grocott's modification of Gomori's methenamine silver stain ($\times 180$). **c to e.** OT 100. *Cryptococcus neoformans* in lung (**c**), brain (**d**) and meninges (**e**). Alcian blue ($\times 200$).

fluid in 2 of the 4 cases (OT 63, 81) and in the two others there was concomitant bacterial growth.

There were examples of yeast infection localized to the brain (Fig. 2), wound, kidneys (2 examples), heart, and subcutaneous tissue (Table 1). The patient with the subcutaneous monilial infection also had *Cryptococcus neoformans* in the same suprapubic location which later spread to the subcutaneous tissues of the legs, arms, and abdomen. The cryptococcal infection was disseminated (Fig. 3).

Disseminated *Candida* infections in 8 patients were overwhelming in the breadth of their organ distribution

(Table 1 and Fig. 4). The most common sites of invasion were the lungs (7), heart (6), esophagus (6), and peritoneum (5). The thyroid, kidney, liver, and brain were less commonly involved. Five of the 8 patients with disseminated moniliasis had candidemia and 4 had candiduria during the postoperative course (Table 1).

In all 18 patients with yeast infection, some kind of damage to the gastrointestinal tract or else a surgical complication was obvious clinically or at autopsy (Table 2). Eight patients had complications of biliary tract reconstruction often with resulting bile leak and/or peritonitis, and 5 required operations on the gastro-

of *Candida* oral cavity, the gastrointestinal tract was normal. There were no significant differences in survival rates since the patients were treated through a course of therapy which would have been employed in the same locations. The peritoneal fluid was normal if related to the finding of *Candida* was called if there was *Candida*.

caused by *Coccidioides immitis*. 3 of these

patients but in *C. tropicalis*. were identified together with

of the 100 postoperative patients had the positive findings in the cultures from

100 patients postoperative diagnosed in 10 in many of the diagnosis extent of the

ed in Table peritoneal though in one demia. The chronic, and of *Candida* drainage

TABLE 1. Organ Involvement with Candida Infections

Organs	Disseminated (8 Patients)	Localized (10 Patients)
Esophagus	6	
Stomach	4	
Liver	2	
Peritoneal cavity	5	4
Heart	6	1
Lungs	7	
Kidneys	2	2
Thyroid	2	
CNS	1	1
Subcutaneous abscesses		1
Wound abscess		1
Positive blood cultures	5	2
Candiduria	4	3

intestinal tract at the time of transplantation or later, usually for the control of hemorrhage. Sixteen of the 18 recipients were eventually found to have ulcerations which did not seem primarily monilial in origin at some level of the gut (Table 2). The lesions covered a large etiologic spectrum and included Herpes-induced ulcers, peptic disease, stercal ulcers, and colitis.

The local or disseminated yeast infections were not commonly the primary reason for failure. As was recently reported elsewhere,¹⁴ a lethal chain of events was usually set into motion by a technical complication

(most frequently of the bile drainage), by the transplantation of a damaged homograft, by the inability to control rejection, or by the need to use excessive high doses of prednisone to achieve adequate control of rejection. Monilial infections came later. The examples are illustrated in Figs. 2-4. One patient had partial liver dearterialization and hepatic gangrene almost immediately after operation; she was never free of infection thereafter (Fig. 2). Another patient was a victim of excessive immunosuppression, which even the high doses used did not prevent recurrent rejection (Fig. 3). A third patient rejected her first graft and was given a second organ that was severely damaged by ischemia (Fig. 4).

The complexity of events in the patients with disseminated Candidiasis has been described before.¹⁵ The fungus infection was the primary cause of failure only in one patient (OT 83) who had fungemia at the time of operation and for at least several days before. Nevertheless, the superinfection of the disseminated Candida infection contributed to the hopelessness of the situation in all of the 8 cases.

Postoperative Infestation. In the foregoing analysis of Candida infections, the denominator in arriving at an incidence of 18% was considered to be the full complement of recipients. It was thought unlikely that a clinically significant yeast infection would have been missed

5 FLUOROCYTOSINE

FUNGUS CULTURES

BLOOD CULTURES

TEMPERATURE (°C)

TOTAL BILIRUBIN (mg/100 ml)

PREDNISONE (mg/day)

AZATHIOPRINE (mg/day)

ALG

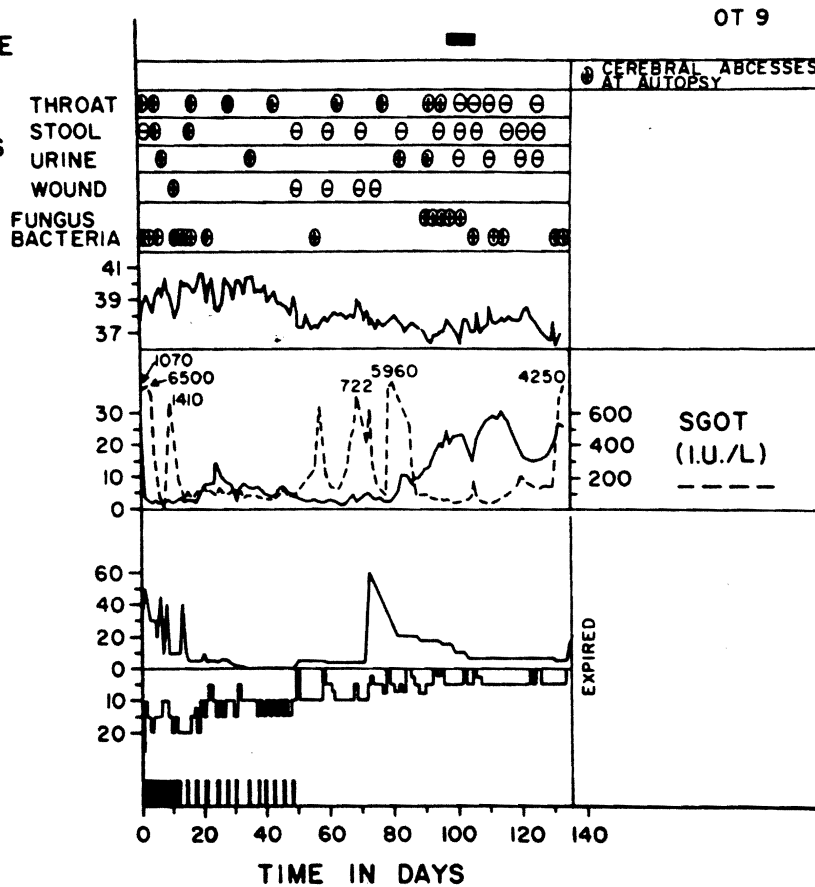


FIG. 2. The course of patient OT 9 who had localized Candida infection with brain abscess at death 133 days after liver replacement. One day post-operation thrombosis of the hepatic artery occurred causing partial hepatic gangrene. The patient was never free of infection thereafter.

AMPHOTERIN B
5 FLUOROCYTOSINE
FUNGUS
TOTAL
(mg)
SOLU-1
(lg)
PREDNISONE
(mg/d)
AZATHIOPRINE
C
CYCLOPHOSPHAMIDE
(mg/
ALG

FIG. 3. The course of patient OT 83 who had localized Candida infection with brain abscess at death 133 days after liver replacement.

In actual fact, the course of patient OT 9 who had localized Candida infection with brain abscess at death 133 days after liver replacement. One day post-operation thrombosis of the hepatic artery occurred causing partial hepatic gangrene. The patient was never free of infection thereafter.

by the trans-
the inability to
e excessively
ate control of
later. Three
e patient had
atic gangrene
was never free
atient was the
which even in
rent rejection
graft and was
damaged by

ents with is-
bed before
use of failure
ngemia at the
days before.
disseminated
pelessness of

going analysis
arriving at an
e the full 00
at a clinic lly
een misse

The course of pa-
T 9 who had a
d Candida infec-
h brain abscesses
h 133 days af-
er replacement
y post-operatively
osis of the right
artery occurred
; partial hepatic
ne. The patient
ever free of in-
thereafter.

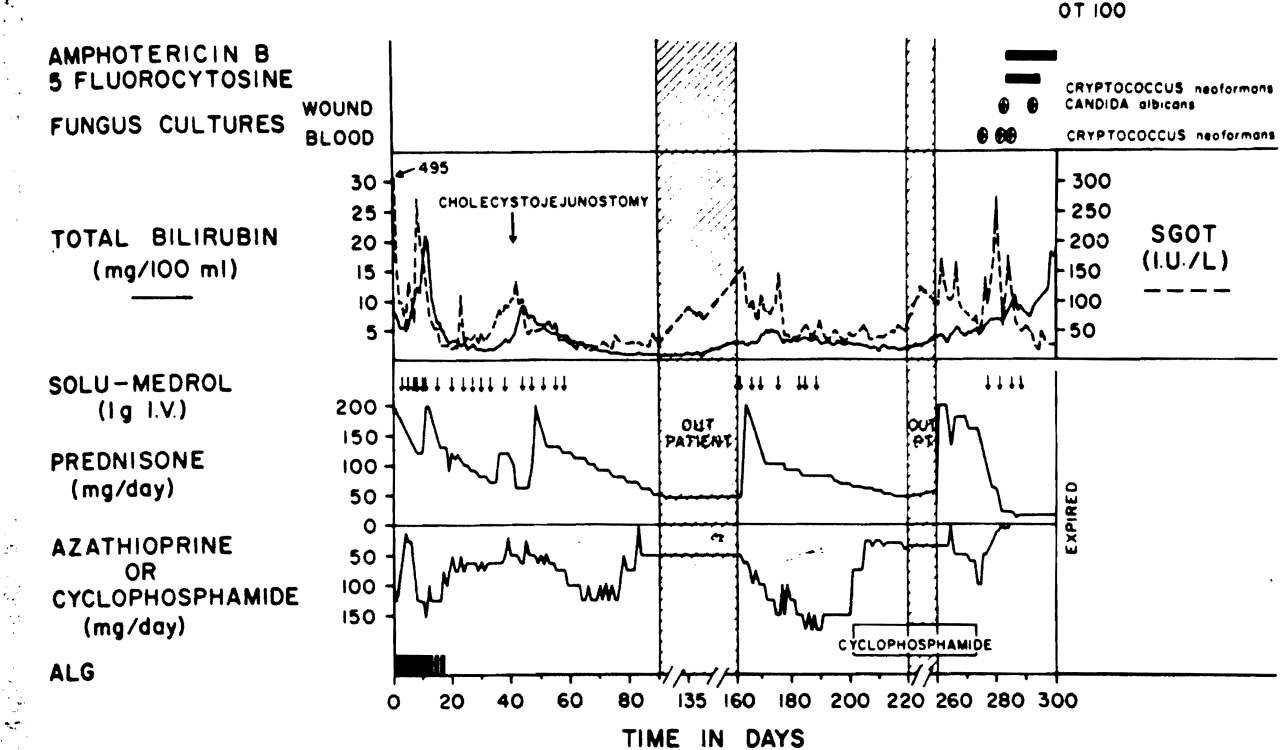


FIG. 3. The course of patient OT 100 who was treated with large doses of Prednisone. Azathioprine or Cyclophosphamide to maintain graft function. He acquired disseminated cryptococcosis and localized candidiasis during the last month of life.

In actuality, routine cultures which would have revealed *Candida* were obtained in only 87 of the patients. *Candida* infestation was found in 31 (36%) of the 87 recipients. The yeasts were most frequently found in surgical wounds or drain sites (22 examples) and in these locations they were always associated with bacteria (Table 3). *Candida* associated with bacteria were found in the bile of 5 patients and in the peritoneal drainage of 6 more; 2 other patients with yeasts in the peritoneal drainage had no accompanying bacteria (Table 3).

Pure cultures of *Candida* species were common in blood and urine samples. Eight patients had candidemia without a bacterial component and there were 8 examples of pure candiduria (Table 3).

As with the *Candida* infections, the infestations had a striking association with gastrointestinal lesions or complications (Table 4). In 19 of the 31 infestations, complications of the bile duct reconstruction had occurred with biliary obstruction or fistula or with enteric fistula formation from the Roux-en-Y jejunal limb, duodenum, or elsewhere. Secondary operations on the gastrointestinal tract for bleeding or perforation were common as were ulcerations throughout the gastrointestinal tract which usually were detected at autopsy (Table 4). There were only 4 examples of infestation in patients who did not have some kind of biliary, gastrointestinal or intraperitoneal lesion (Table 4).

The clinical significance and threat of the *Candida* infestations *per se* was difficult to evaluate. The presence of the positive cultures in the various sites almost always led to a decision for treatment with Amphotericin B or 5-Fluorocytosine even though the main threat to life invariably was some other kind of complication.

Postoperative Colonization. Among the 87 patients who had adequate cultures, another 26 had colonization in the normal locations, invariably including the upper respiratory tract.

Aspergillosis

Nine patients had documented aspergillosis, and in a tenth the diagnosis was suspected and treated but not proved (Table 5). The infection was localized in 7 of the recipients and disseminated in the other 3. The lungs were involved in 8 of the 10 patients, being spared only in one patient each with localized liver and brain involvement. The lung lesions ranged from abscesses to diffuse necrotizing pneumonitis with pleural involvement.

Aspergillus was never found in blood or urine cultures. Because of positive sputum cultures, the diagnosis was suspected during life in 3 of the 10 patients, and one of these recipients (OT 78) was apparently treated successfully. The diagnosis was first made at autopsy in the other 7 cases. One patient with

aspergillosis of the brain (OT 97) also had candidiasis of the heart.

Aspergillosis was the main cause of death of only patient OT 81. The other 9 patients died a few days to 41 months postoperatively from a variety of principal causes that included acute or chronic graft rejection (2 examples), duct obstruction (3), irreversible brain damage (1), acute graft necrosis (1), and recurrence of the primary hepatic tumors for which the liver replacement had been performed in the first place (2).

Disseminated Cryptococcosis

One patient (OT 100) had disseminated Cryptococcosis of lungs, brain, heart, meninges, kidneys, pancreas, subcutaneous tissue and liver allograft. Blood cultures were positive (Fig. 3). The presence of the variably encapsulated yeasts in the central nervous system was not associated with inflammation. In the lungs the only response was with focal mononuclear

and histiocytic inflammation. The necrotic subcutaneous lesions which had a polymorphonuclear leukocyte infiltration contained *Candida albicans* in addition to the *Cryptococcus neoformans*. Both infections persisted during 16 days of therapy with Amphotericin B, combined with 5-Fluorocytosine for 11 of the 16 days.

E. coli and *Clostridium septicemia* complicated by severe small bowel hemorrhage was the immediate cause of death. The homograft showed the histologic features of mild to moderate chronic rejection in spite of the fact that exceptionally heavy immunosuppression had been given.

Discussion

Even though the studies were retrospective, and although no special effort had been made to detect fungi, about three-fourths of the recipients eventually became colonized, infested or infected with yeasts.

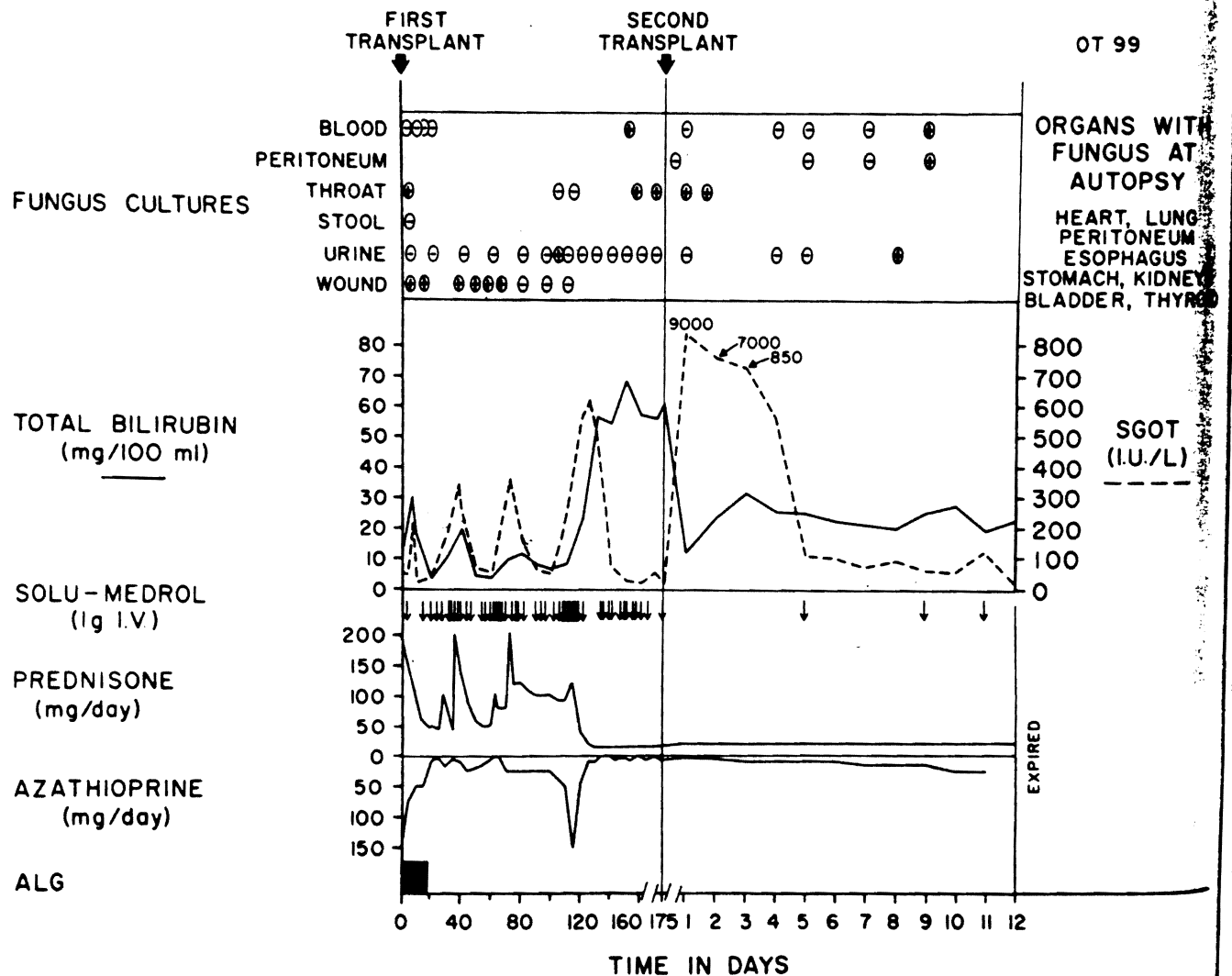


FIG. 4. The course of patient OT 99 who was retransplanted because of failure of the first graft. She died of combination of ischemic graft and untreated disseminated candidiasis. The *Candida* infection antedated second transplantation.

TABLE 2. *Candida* in Pa...

Gastrointestinal
Ulcerations of:
Oral cavity
Esophagus
Stomach
Small bowel
Colon
Bacterial peritonitis
GI tract operation
Pancreatitis
Biliary Complications
Obstruction
Bile and/or enter

The yeasts were *Candida albicans*. *Candida* was also found in the peritoneum, and in the esophagus operatively.

Candida are common organisms. They cause disturbances in the immune system. The intensive antibiotic therapy to control bacterial infection after transplantation was particularly effective. In our patients, disseminated candidiasis was particularly dangerous. A normal host would not survive on himself. *Candida albicans* and candidemia are common in immunosuppressed patients and other factors such as episodic candidiasis, metastatic infection, and direct to *Candida* infection are normal in liver transplant recipients. Immunosuppression itself has a high mortality in the esophagus, stomach, and small intestine.

TABLE 3. *Candida* in Pa...

Cultures
Blood
Urine
Peritoneal fluid
Bile
Surgical wounds

TABLE 2. *Gastrointestinal Damage and Biliary Complications in Patients with Localized and Disseminated Candida Infections*

Gastrointestinal damage	Disseminated (8 Patients)	Localized (10 Patients)
Ulcerations of:		
Oral cavity	1	4
Esophagus	6	4
Stomach	5	5
Small bowel		3
Colon	1	3
Bacterial peritonitis	3	1
GI tract operation	3	2
Pancreatitis	2	4
Biliary Complications		
Obstruction	2	4
Bile and/or enteric fistula	3	2

The yeasts were not always classified, but most were *Candida albicans*. In many cases colonization with *Candida* was already present at the time of transplantation, and in the others it tended to develop early postoperatively.

Candida are part of the normal human flora. Disturbances in this flora were undoubtedly caused by the intensive antibiotic therapy^{9,12} which was necessary to control bacterial infection during and after liver transplantation. The increase in the yeast population was particularly striking in the gastrointestinal tract of our patients. Dissemination to other areas from the gastrointestinal tract was a predictable derivative hazard. A normal human volunteer has demonstrated upon himself that ingestion of a large quantity of *Candida albicans* was followed by transient candiduria and candidemia.⁵ In patients made susceptible by immunosuppression, malnutrition, steroid diabetes, and other factors common in liver recipients, such episodic candidemias would be more apt to cause metastatic infections.

In addition, the "porosity" of the gastrointestinal tract to *Candida* would be predictably greater than normal in liver recipients, apart from any role played by immunosuppression. Advanced liver disease in and of itself has a high association with erosive lesions of the esophagus, stomach, and bowel. During the trans-

TABLE 3. *Positive Culture Sites in 31 Patients Infested with Candida Species*

Culture Sites	No. of Examples
Blood	8
Urine	8
Peritoneal fluid	8
Bile	5
Surgical wound or drain site	22

plantation, variable venous hypertension is imposed on the bowel during partial cross clamping and extensive manipulation is necessary. Multiple intestinal anastomoses must be performed if biliary reconstruction is with a Roux-en-Y jejunal loop. After operation, a variety of extrahepatic gastrointestinal complications has been noted. In addition to the difficulties recorded in Tables 2 and 5, about 10% of patients had hypomotility syndromes associated with or without colonic or ileal fecal impaction. Some of the small gastrointestinal ulcerations that developed postoperatively were proved or suspected of being due to activation of cytomegalovirus and Herpes simplex.

The liver itself or its duct system was apparently the site of contamination in some cases. When the liver was seriously damaged from ischemia or devascularization, or when the duct system leaked or was obstructed the incidence of positive *Candida* cultures from ascitic fluid, the liver, and even the blood became overwhelming. In such cases, the yeast infestations or infections were only a part of a complex chain of adverse and ultimately lethal events in which bacterial invasion became the most deadly factor.¹⁴

The gastrointestinal tract is not the only potential entry site of *Candida*. Respiratory and urinary origins could become a factor as the result of prolonged respirator care or urinary catheterization as could venous or arterial catheters. However, these sources had little significance in the moniliasis we observed in our patients.

Our review of our experience has suggested several therapeutic approaches. Oral administration of a non-absorbable antifungal agent such as Nystatin should be used to reduce colonization of the gastrointestinal tract with *Candida*. However, the efficacy of this preventive measure has been limited by restrictions in oral intake.

TABLE 4. *Gastrointestinal Damage and Biliary Complications in 31 Patients Infested with Candida Species*

Gastrointestinal Damage	No. of Examples
Ulcerations of:	
Oral cavity	4
Esophagus	7
Stomach	9
Duodenal ulcer	1
Small bowel	4
Colon	4
Peritonitis	8
GI tract operation	3
Pancreatitis	2
Peritoneal carcinomatosis	2
Biliary Complications	
Obstruction	16
Bile and/or enteric fistula	6
None Detected	4

TABLE 5. Organ Involvement with Localized and Disseminated Aspergillosis

Organs	Disseminated (7 Patients)	Localized (7 Patients)
Esophagus	1	
Stomach	2	
Peritoneum	1	
Liver	1	1
Spleen	2	
Pancreas	1	
Kidneys	2	
Adrenals	3	
Lungs	3	5
Heart	3	
Brain	3	1
Thyroid	2	
Prostate	1	
Skin	1	

by disturbed bowel function and motility and by the fact that exposure of areas like the oral cavity and esophagus to the medication are so transient. If this conservative measure fails to control colonization, early treatment should be considered with low doses of intravenous Amphotericin B which do not result in irreversible renal damage. Such prophylactic treatment may decrease the chance of developing disseminated or metastatic infection in doses that would not be expected to be effective in established infections. Because of the rapid development of drug resistant yeast populations during administration of 5-Fluorocytosine,¹⁰ Amphotericin B appears to be the preferred agent for this purpose, in spite of its greater intrinsic toxicity.

If it were not for the yeasts, fungus infections in liver recipients would not be problems much different than that seen after renal^{1,2,8,11} and cardiac⁴ transplantation. The next most common hazard to the liver patients was invasive aspergillosis, which was localized in 7 patients and disseminated in 3 patients. The diagnosis was made or suspected prior to death in 3 patients in whom aspergillosis was found in sputum cultures. Colonization with this fungus was not observed. The clustering of cases of aspergillosis during a period of months was consistent with the concept that this infection is acquired from the environment. The frequent pulmonary involvement suggested that inhalation of spores was a common mode of infection. The gastric infections pointed to ingestion of spores as an alternative and less common means of infection.

Cryptococcus neoformans caused the only other

kind of fungus infection in the series of 100 patients and even this was associated with *Candida albicans*. The combined infection could not be controlled.

References

1. Bach, C. M., Adler, J. L., Breman, J. et al.: Influence of Rejection on Fungal and Nocardial Infections in Renal Transplant Recipients. *Lancet*, 1:180, 1973.
2. Burton, J. R., Zachery, J. B., Bessin, R., et al.: Aspergillosis in Four Renal Transplant Recipients. Diagnosis and Effective Treatment with Amphotericin B. *Ann. Intern. Med.*, 77:307, 1972.
3. Fulginiti, V. A., Scribner, R., Groth, C. G., et al.: Infection in Recipients of Liver Homografts. *N. Engl. J. Med.*, 279:603, 1968.
4. Gurwitz, M. G., Stinson, E. B., and Remington, J. S.: Aspergillosis Complicating Cardiac Transplantation. Report of 5 Cases. *Arch. Intern. Med.*, 128:541, 1971.
5. Krause, W., Matheis, H., and Wulf, K.: Fungaemia and Funguria after Oral Administration of *Candida Albicans*. *Lancet*, 1:598, 1969.
6. Martineau, G., Porter, K. A., Corman, J., et al.: Delayed Biliary Duct Obstruction after Orthotopic Liver Transplantation. *Surgery*, 72:604, 1972.
7. Myerowitz, R. L., Medeiros, A. A., and O'Brien, T.: Bacterial Infection in Renal Homotransplant Recipients. *Am. J. Med.*, 53:308, 1972.
8. Rifkind, D., Marchioro, T. L., Schneck, S. E., and Hill, R. B.: Systemic Fungal Infections Complicating Renal Transplantation and Immunosuppressive Therapy. *Am. J. Med.*, 43:507, 1967.
9. Robinson, H. M., Jr.: Moniliasis Complicating Antibiotic Therapy. *Clinical and Laboratory Studies*. *AMA Archives of Dermatology and Syphilis*, 70:640, 1954.
10. Schönbeck, J.: Studies on 5-Fluorocytosine and its Relation to *Candida Albicans*. *Scand. J. Urol. Nephrol.*, 11 (Suppl.), 1972.
11. Schröter, G. P. J., Temple, D. R., Husberg, B. S., et al.: Cryptococcosis after Renal Transplantation. Report of 10 Cases. *Surgery*, 79:268, 1976.
12. Seelig, M. S.: The Role of Antibiotics in the Pathogenesis of Candida Infections. *Am. J. Med.*, 40:887, 1966.
13. Starzl, T. E., Ishikawa, M., Putnam, C. W., et al.: Progress and Deterrents to Orthotopic Liver Transplantation, with Special Reference to Survival, Resistance to Hyperacute Rejection and Biliary duct reconstruction. *Transplant. Proc.*, 6:129, 1974.
14. Starzl, T. E., Porter, K. A., Putnam, C. W., et al.: Orthotopic Liver Transplantation in Ninety-Three Patients. *Surg. Gynecol. Obstet.*, 142:487, 1976.
15. Starzl, T. E., Porter, K. A., Putnam, C. W., et al.: Biliary Complications after Liver Transplantation: With Special Reference to the Biliary Cast Syndrome and Techniques of Secondary Duct Repair. *Surgery*. (In Press).
16. Starzl, T. E., and Putnam, C. W.: *Experience in Hepatic Transplantation*. Philadelphia, W.B. Saunders Company, 1969.
17. Stinson, E. B., Bieber, C. P., Griep, R. B., et al.: Infectious Complications after Cardiac Transplantation in Man. *Am. Intern. Med.*, 74:22, 1971.
18. Williams, R., Smith, M., Shilkin, K. B., et al.: Liver Transplantation in Man: The Frequency of Rejection, Biliary Tract Complications, and Recurrence of Malignancy Based on Analysis of 26 Cases. *Gastroenterology*, 64:1026, 1973.