

397

Charles W. Putnam, M.D.,
and Thomas E. Starzl, M.D., Ph.D.

7

Portal Diversion for Inborn Errors of Metabolism: With Special Reference to Glycogen Storage Disease, Type II Hyperlipidemia, and Juvenile Gaucher's Disease

INTRODUCTION

Lately, a new dimension has been added to the old operation of portacaval shunt by employing it to favorably alter the course of patients with several inborn errors of metabolism. Our own experience has been with glycogen storage disease, type II hyperlipoproteinemia, and Gaucher's disease. In addition, Folkman of the Boston Children's Hospital has recently performed portacaval shunt in a patient with alpha₁-antitrypsin deficiency. We will discuss here these new uses for portal diversion. In addition, it will be interesting to look at possible mechanisms of the benefits of portacaval shunt, as these have been clarified by some recent advances in hepatic physiology.

GLYCOGEN STORAGE DISEASE

Trials of Portacaval Transposition

The first portal diversion for hepatic glycogen storage disease was performed almost 15 years ago²³ in a girl who is still well today. By shortcircuiting

splanchnic venous blood around the liver, it was hoped to make glucose more readily available to peripheral tissues and thus to relieve hypoglycemia, to coincidentally deglycogenate the liver, and to palliate other metabolic derangements such as acidosis. In order to avoid the potential complication of hepatic encephalopathy, which commonly follows portacaval shunt in dogs and other animals, the operation of portacaval transposition was selected, whereby the bypassed portal flow is replaced with venous blood from the suprarenal inferior vena cava (Fig. 7-1).

In this first patient the cavoportal anastomosis is still open more than a decade later with some flow to the liver (Fig. 7-2). However, most of the vena caval blood bypasses the liver through venous collaterals (Fig. 7-2). A second

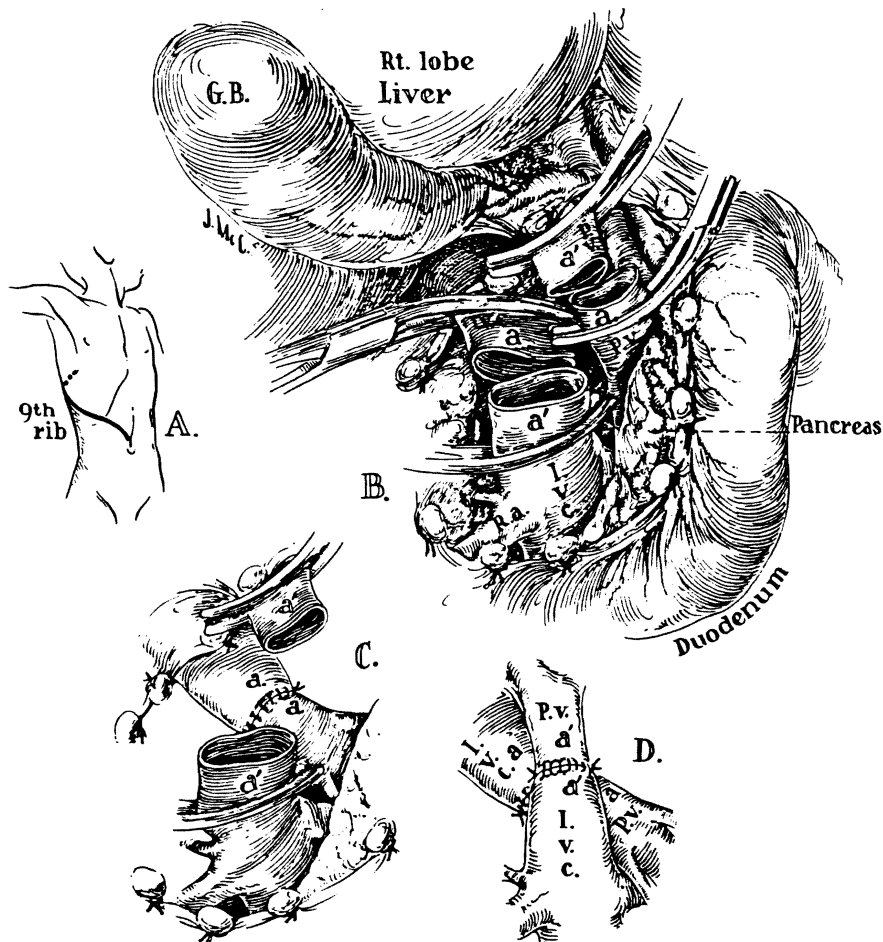


Fig. 7-1. The technique of portacaval transposition as it was carried out in the first 2 patients with glycogen storage disease treated at our center by portal diversion. (From ref. 23.)



Fig. 7-2. Inferior patient, in whom previously, there is a portal liver, as well as a copy. (IVC, distal 26.)

transposition was young boy who located and brought was open, but the so that the liver Nevertheless, this

Standardized Care

By the time the basic operative second patient su was unable to tra describing this ca the Cleveland Cl used. In 1972 Fol parenteral hyperali pre-existing hepat lipidemia.

Seven of these surviving children Despite marked m

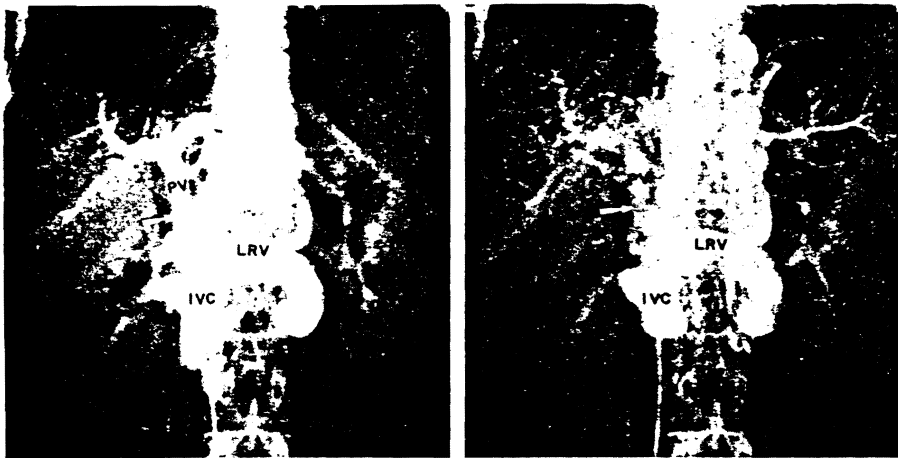


Fig. 7-2. Inferior vena cavagrams in March 1973 in Colorado Case 1 (Table 7-2). In this patient, in whom portacaval transposition (Fig. 7-1) had been performed 9½ years previously, there is a patent cavalportal anastomosis (arrow). Significant flow through the liver, as well as around it by the azygous and other collaterals, was well seen at fluoroscopy. (IVC, distal inferior vena cava; LRV, left renal vein; PV, portal vein.) (From ref. 26.)

transposition was soon performed by Riddell et al.¹³ of Bristol, England, in a young boy who emigrated to Calgary, Canada, not long postoperatively. He was located and brought to Denver for follow-up studies. The portacaval anastomosis was open, but the vena caval to portal venous anastomosis had clotted (Fig. 7-3) so that the liver was not provided with replacement flow as was intended. Nevertheless, this patient is also well.

Standardization of Operative and Supportive Care

By the time 9 cases had been compiled throughout the world (Table 7-1), the basic operative procedure had become an end-to-side portacaval shunt. In our second patient submitted to portacaval transposition, the glycogen-laden liver was unable to transmit the vena caval flow and the child died within 2 days. In describing this case¹⁶ and in a simultaneous report by Hermann and Mercer⁸ of the Cleveland Clinic, it was recommended that end-to-side portacaval shunt be used. In 1972 Folkman et al.⁴ added the important observation that preoperative parenteral hyperalimentation could reduce the operative risk by normalizing the pre-existing hepatomegaly, acidosis, and other abnormalities including hyperlipidemia.

Seven of these first nine patients (Table 7-1) are still alive. Two of the seven surviving children had severe hypoglycemic brain injury before portal diversion. Despite marked metabolic improvement, Hermann's child died about 1½ years

nd Starzl
 ose more
 to coinci-
 ngements
 patic en-
 other ani-
 he bypas-
 erior vena
 re than a
 f the vena
 A second

Pancreas

n the first 2
 1. (From ref.



Figure 2 in Table 7-1). The procedure was done in the Foothills Hospital, at the anastomotic site (Right): Note the patent portacaval anastomosis to the inferior vena

months later, was also not improved. In some cases, growth may have improved by measures after

cases with 9 patients. In the simple portacaval anastomosis (type I), 5 patients (type VI), 1 patient. There was an improvement in growth and acidosis.

In the case of preexisting hypoglycemia, the child continued to improve in the other

Table 7-1
First 9 Cases of Portal Diversion for Glycogen Storage Disease

Case	Surgeon	GSD Type	Age (Years)	Procedure (Date)	Outcome			Reference
					Survival	Patency		
1	Starzl et al., Denver	IIIB	8	Transposition (10/63)	Alive	Open		23
2	Riddeil et al., Bristol	I	7	Transposition (5/65)	Alive	Cava-portal anastomosis clotted		13
3	Hermann and Mercer, Cleveland	I	1	P-C shunt (4/67)	Died 1½ years	Open		8
4	Starzl et al., Denver	I	7	Transposition (6/68)	Died 2 days	Open		16
5	Boley et al., New York	I	5	P-C shunt (5/69)	Alive	Thought to be open		1
6	Clatworthy, Columbus	I	¾	P-C shunt (6/70)	Alive	Clotted		3
7	Folkman et al., Boston	I	3	P-C shunt (7/71)	Alive	Open		4
8	Folkman et al., Boston	I	2	P-C shunt (11/71)	Alive	Open		4
9	Starzl et al., Denver	I	7	P-C shunt (5/72)	Alive	Open		26

Table 7-2
Children with Glycogen Storage Disease Treated at the University
of Colorado by Portal Diversion

Case No. (Date)	Age at Operation (Years)	Type	Symptoms		
			Hypoglycemia	Acidosis	Growth Retardation
1* (1963)	8½	III	X	X	X
2* (1968)	7	I	X	X	X
3 (1972)	7	I	X	X	X
4 (1972)	11	I	X	X	X
5 (1972)	10	IV			X
6 (1972)	5	III	X	X	X
7 (1972)	3	III	X	X	X
8 (1973)	8	I	X	X	X
9 (1973)	13	I	X	X	X

*These 2 patients had portacaval transposition. All others had end-to-side portacaval shunt.

One reason for the continuing hypoglycemia may be the major increases in peripheral insulin after shunting. It has been known from the work of Lockwood et al.¹¹ that the peripheral insulin curves in patients with glycogen storage disease are flat (see preoperative study in Fig. 7-4). After shunting, the insulin response curves to glucose stimulation, months to years postoperatively, have been normal or distinctly supra-normal in several of our cases in whom these parameters were measured (Fig. 7-4). In turn, the flooding of insulin to the periphery may well have been the main reason for the growth spurt which we will describe later. In any event, it would be a mistake, at least in some of the cases, to try to completely eliminate dietary hypoglycemia management.

Effect on the liver. Liver glycogen concentrations were little changed from the preoperative levels, from 5 months to more than 9 years after portal diversion.²⁶ Even so, the liver in several of the children underwent obvious shrinkage (Fig. 7-5), which could be confirmed by planimetry. Even if such

obvious shrinkage in hepatic tissue is a virtue of the procedure around the

Other hypoglycemia

Symptoms	
Growth Retardation	X
	X
	X
	X
	X
	X
	X
	X
	X

side portacaval shunt.
 re major increases in
 e work of Lockwood
 ogen storage disease
 the insulin response
 ly, have been normal
 ese parameters were
 periphery may well
 ill describe later. In
 ases, to try to com-

were little changed
 9 years after portal
 underwent obvious
 retry. Even if such

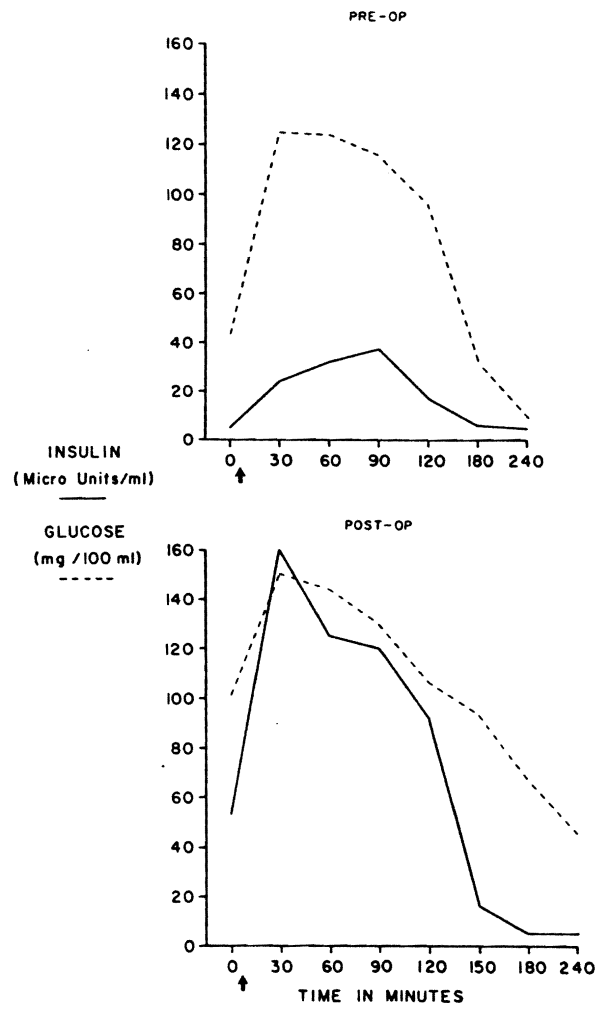


Fig. 7-4. Preoperative and postoperative oral glucose tolerance tests in a child with type I glycogen storage disease. Note the tremendous increase in peripheral venous insulin concentrations after portal diversion.

obvious shrinkage did not occur, postoperative biopsies always showed a diminution in hepatocyte size.²⁶ Any changes in liver size were, of course, magnified by virtue of the accelerated body growth which resulted in the body growing up around the liver.

Other metabolic abnormalities. In contrast to the incomplete relief of hypoglycemia, all components of the hyperlipidemia which is characteristic of




Fig. 7-5. AP 99m technetium liver scans in a child with type VI (phosphorylase deficiency) disease (Case 5 in Table 7-2). The cm^2 areas were obtained by planimetry from the anteroposterior projections. (From ref. 26.)

type I disease were profoundly and permanently relieved. This was first observed by Hermann and Mercer⁸ and confirmed by Folkman et al.⁴ and in our own cases.²⁶ Correction of other metabolic defects, including abnormal bleeding, uric acid elevations, and abnormal calcium metabolism, was also observed.²⁶

Effect on growth. Another major effect was on body growth. In our original case, a remarkable growth spurt was noted.²³ Accelerated height increases have been seen in all of our patients followed for sufficient time intervals.²⁶ During the first year after operation, these previously dwarfed children have grown at the rate of between 0.5 and 1 cm every month.

Comparison of x-rays of the wrist and hands before and 11½ months after operation shows the phenomenal effect of bone age doubling in a child with type I disease (Fig. 7-6). In addition to growth, mineralization has occurred and new bones have appeared in the wrists. Circulating somatotropin in these patients was normal. As mentioned earlier, the growth spurts may have been at least partially attributable to the increased insulin distribution to the periphery, since insulin has recently been recognized to be a major growth hormone comparable in potency to somatotropin.¹⁴

Alternative Therapy

The observations of Folkman et al.⁴ about the corrective effects of preoperative hyperalimentation were alluded to earlier. Because of the obvious limitations of chronic intravenous infusion therapy, this kind of treatment is not practical clinically. Burr and his coworkers² have reported marked relief of biochemical abnormalities, platelet dysfunction, and hepatomegaly in a 16-year-old boy with

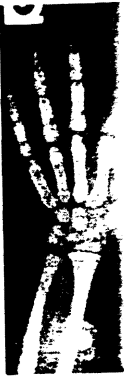

Fig. 7-6. The first 11½ months after operation. In addition to the appearance of

type I disease of carbohydrate

Folkman ingenious ingenious inn solution which battery-operated the metabolic diversion hav

HYPERLIPID

In the gl are always pat because of f homozygous portacaval sh cholesterol an ited disorder that there may normally bind does not ente suppression o

Whatever has a shocking Lipid-rich dep of the body.



8 1/2 MONTHS
POST-OP
218 cm²

phosphorylase de-
planimetry from

as first observed
and in our own
d bleeding, uric
served.²⁶

h. In our origi-
eight increases
me intervals.²⁶
children have

1/2 months after
child with type
urred and new
se patients was
least partially
nce insulin has
e in potency to

s of preopera-
us limitations
not practical
biochemical
old boy with

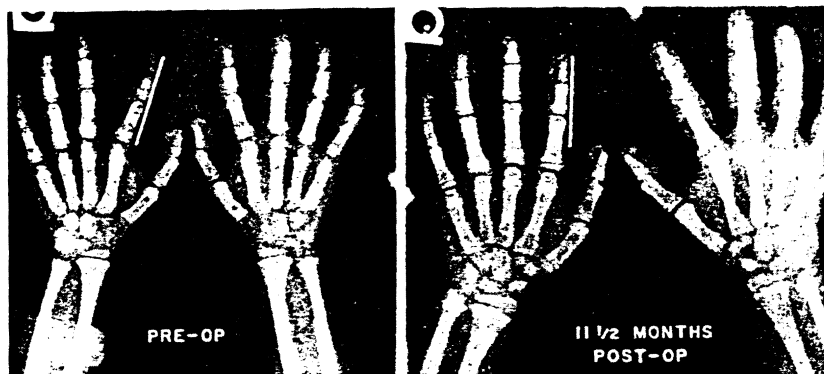


Fig. 7-6. The dramatic wrist and hand bone growth in Colorado Case 3 (Table 7-2) in the first 11 1/2 postoperative months. The bracket on the left index finger is 5 cm in length. In addition to the size change, note the mineralization that has occurred, as well as the appearance of new bones in the wrist. (From ref. 26.)

type I disease, who was treated for 23 days with continuous intragastric infusion of carbohydrate and protein.

Folkman and his associates (*personal communication*, 1975), in another ingenious innovation, are trying the continuous intragastric infusion of a sugar solution which is delivered through a gastrostomy by a finely calibrated, battery-operated pump. With prolonged intragastric hyperalimentation, many of the metabolic effects seen with parenteral hyperalimentation and after portal diversion have been duplicated, including accelerated body growth.

HYPERLIPIDEMIA

In the glycogen storage diseases which we have been discussing, the livers are always patently abnormal because of the accumulation of glycogen, and often because of fibrosis.²⁶ By contrast, the liver is morphologically normal in homozygous type II hyperlipoproteinemia, a second metabolic disease for which portacaval shunt has been performed. The explanation for the elevated serum cholesterol and low density lipoproteins (LDL) in this autosomal-dominant inherited disorder is by no means understood. Goldstein and Brown⁷ have suggested that there may be an absence of or a defect in the cell surface receptor sites which normally bind and transport LDL cholesterol into the cell. Because cholesterol does not enter the cell adequately, there is an absence of normal feedback suppression of cholesterol synthesis.

Whatever its cause, the homozygous form of type II hyperlipoproteinemia has a shockingly poor prognosis even with attempts at rigorous medical therapy.⁵ Lipid-rich deposits are laid down in widely separated superficial and deep parts of the body. Lipid accumulations in the vascular system cause aortic valvular

stenosis and coronary artery disease. Such cardiovascular complications are classically responsible for the precocious deaths from this disorder.

Colorado Cases

A young girl with homozygous type II hyperlipidemia was followed and treated medically at the university clinics for most of her life. By the time she was 7 years old, she had demonstrable aortic stenosis (Table 7-3) and significant angina pectoris. Portal diversion was first seriously considered for this patient in the spring of 1972 when she was 10 years of age. Unfortunately, a negative decision was made. In November 1972 her cardiac symptoms had become disabling. At that time she was given a course of parenteral hyperalimentation¹⁹ similar to that introduced by Folkman et al.⁴ for the preparation of patients with type I glycogen storage disease for portal diversion. A delayed but definite lowering of the previously refractory hypercholesterolemia was seen (Fig. 7-7), which outlasted the intravenous therapy by several weeks.¹⁹ Parenthetically, the antilipidemic effect of parenteral hyperalimentation in such patients has been confirmed in two recent papers, one by Torsvik et al.²⁸ from the United States and the other by Stein et al.²⁷ from South Africa.

In January 1973 the patient suffered a massive myocardial infarction. About 2 months after the infarction, end-to-side portacaval shunt was performed. Post-operatively, there was a dramatic fall in serum cholesterol concentration from about 800 mg/100 ml to nearly normal (Fig. 7-8). The cutaneous and tendinous lesions melted away (Fig. 7-9). By cardiac catheterization (Table 7-3), the gradient caused by severe aortic stenosis regressed. There also seemed to be reversal of atherosclerosis on coronary arteriography. However, three areas of residual stenosis remained. The most severe stenosis is shown in Figure 7-10.

Her course was one of steady improvement.^{17,19} However, on September 23, 1974, while coming home from school, she collapsed in the street and died. The conclusion from her autopsy¹⁸ was that death was caused by a cardiac arrhythmia. The old ventricular aneurysm was found but no new infarction was identified. The residual high-grade coronary artery stenoses were identified. The portacaval shunt was patent. The liver was grossly normal, but the hepatocytes were smaller than before operation. The liver cells contained some abnormalities

Table 7-3
Findings of Aortic Stenosis in a Child with Homozygous Type II Hyperlipidemia

	Aortic Systolic Murmur	mm Hg Gradient
Age 7	2+	24
Age 11	4+	56
16 Months after portacaval shunt	0	10

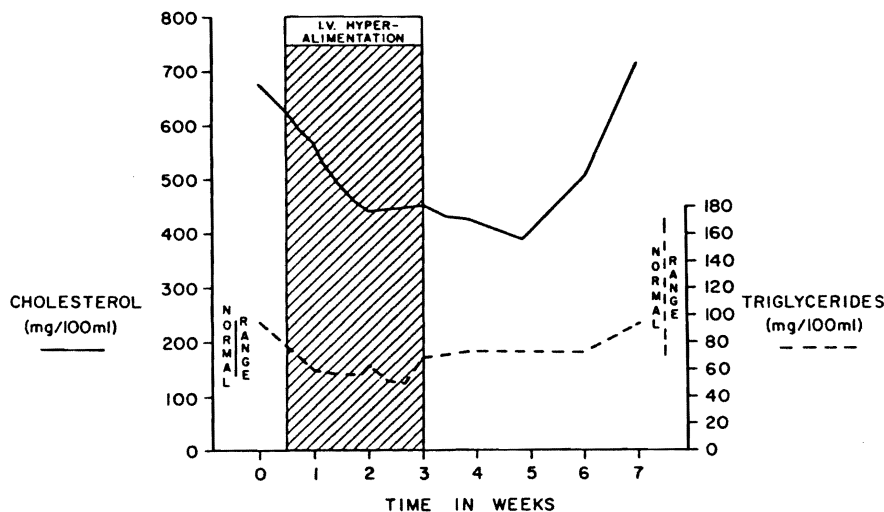


Fig. 7-7. Changes in cholesterol and triglycerides during intravenous hyperalimentation in a 12-year-old girl with homozygous type II hyperlipoproteinemia. (From ref. 19.)

of the organelles as had been reported from an earlier biopsy.¹⁹ Survival from the time of portacaval anastomosis had been almost 19 months.

We have also performed a portacaval shunt on a 7-year-old girl who had serum cholesterol values averaging 1000 mg/100 ml preoperatively. Nine months later the cholesterol was about 500 mg/100 ml (Fig. 7-11). Hepatic lipoprotein synthesis in this patient, as measured by Brown and Goldstein of Dallas (*per-*

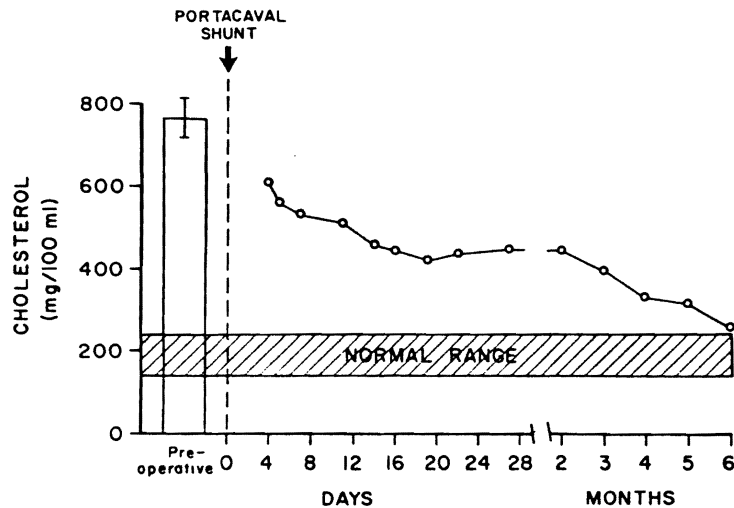


Fig. 7-8. Cholesterol concentrations before and during the first 6 months after portal diversion. The preoperative value represents the mean of nine determinations \pm 1 SD. The operation was performed on March 1, 1973. (From ref. 19.)

n and Starzl
ons are clas-

ollowed and
the time she
d significant
his patient in
, a negative
come disabl-
ion¹⁹ similar
s with type I
lowering of
, which out-
lly, the an-
ts has been
United States

ction. About
ormed. Post-
tration from
nd tendinous
-3), the gra-
o be reversal
s of residual

n September
et and died.
by a cardiac
infarction was
entified. The
hepatocytes
abnormalities

Ig Gradient

- 24
- 56
- 10

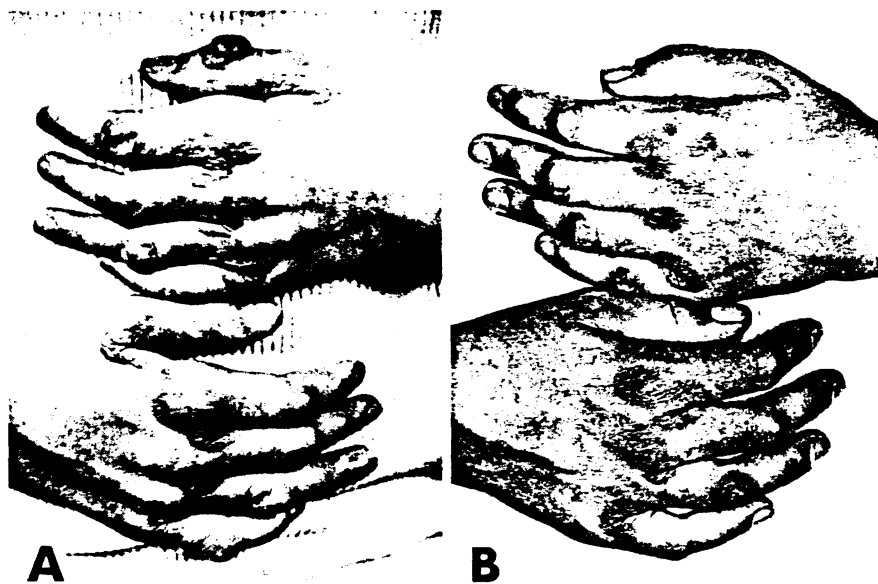


Fig. 7-9. Patient's hands (A) 2 weeks before and (B) 16 months after portacaval shunt for type II hyperlipidemia.

sonal communication) has been sharply reduced. Our own canine and baboon studies have also indicated that portal diversion greatly reduces hepatic lipid synthesis.²¹

Other Cases Elsewhere

We have information on 8 other patients, 6 from South Africa, submitted to portacaval shunt for homozygous type II hyperlipidemia. All these patients had a significant cholesterol reduction except a girl from Cape Town. In her case the shunt was proved to have clotted. Even more interesting, a huge collateral coming from the general area of the pancreas had revascularized the tied off central portal vein, thus explaining the therapeutic failure in this case (Cywes, *personal communication*, 1974).

Four South African patients studied in the Lipid Disorders Centre of the University of Witwatersrand, Johannesburg, were recently reported by Stein et al.²⁷ This article was of singular importance since it presented data from multiple patients, confirming several potentially important observations made in our first case. These included the antilipidemic effect of parenteral hyperalimentation, the sustained lipid-lowering effect of portal diversion, the melting away of visible xanthomatous deposits, and the relief of angina pectoris and other cardiovascular symptoms. There seems reason to hope that the lethal lesions characteristic of

Fig. 7-10. (ing of the co discrete areas 25.)

homozygous version.

JUVENILE (POSSIBILIT

The thir shunt is Gau in whom this was referred shunt was pe

It is inte with the sam cation, 1975 alive. Unfor



after portacaval shunt

canine and baboon
duces hepatic lipid

Africa, submitted to
these patients had a
wn. In her case the
a huge collateral
larized the tied off
a this case (Cywes,

rders Centre of the
reported by Stein et
data from multiple
ns made in our first
eralimentation, the
ng away of visible
ther cardiovascular
ns characteristic of

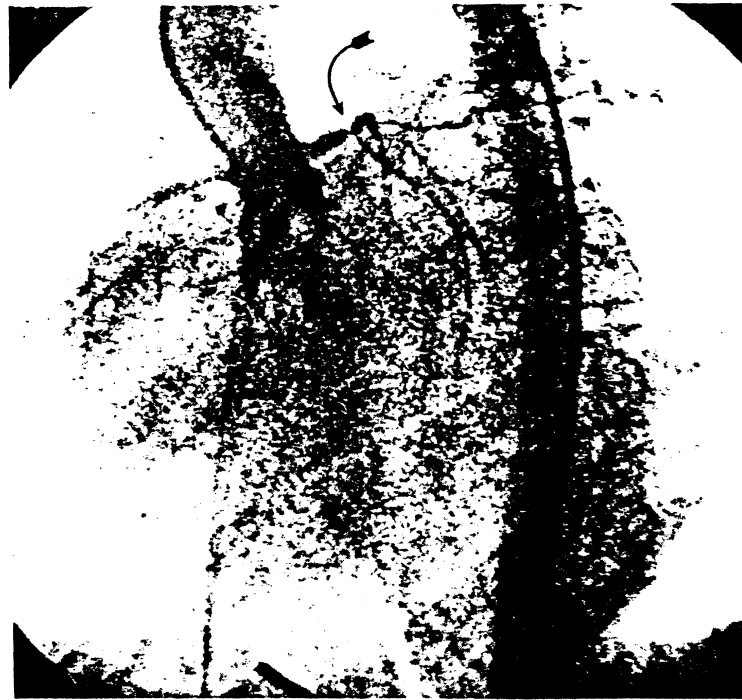


Fig. 7-10. Coronary arteriogram 16 months after portacaval shunt. The diffuse narrowing of the coronary arteries seen in the preoperative study had resolved except for three discrete areas of occlusive disease, one of which is displayed here (arrow). (From ref. 25.)

homozygous type II hyperlipoproteinemia may undergo reversal after portal diversion.

**JUVENILE GAUCHER'S DISEASE AND OTHER
POSSIBILITIES**

The third inborn error of metabolism which we have treated with portacaval shunt is Gaucher's disease or the glucosyl ceramide lipidosis. A 14-year-old-boy, in whom this disorder had led to hepatic failure, uremia, and intractable ascites, was referred to us to be considered for liver transplantation. Instead, a portacaval shunt was performed with amelioration of all these symptoms.

It is interesting that Imparato¹⁰ of New York reported a similar case in 1960 with the same gratifying result. In a recent correspondence (*personal communication*, 1975), he has given us an 18-year follow-up of his patient, who is still alive. Unfortunately, this man, who is now 28 years old, suffers from a convul-

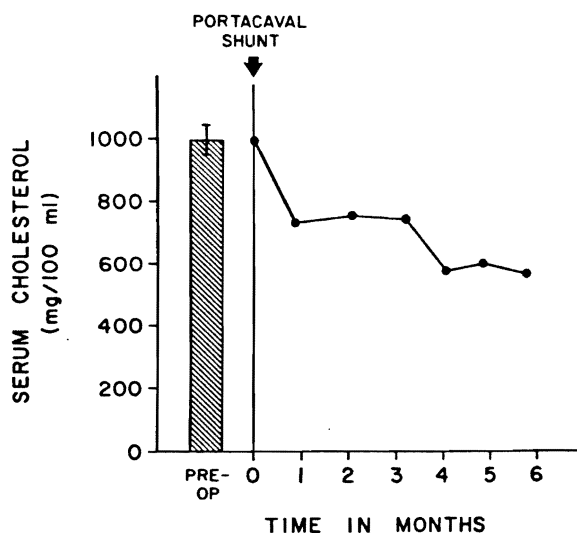


Fig. 7-11. Serum cholesterol values during the first 6 months after portacaval shunt in a 7-year-old girl with homozygous type II hyperlipidemia. The preoperative value represents the mean (\pm 1SD) of 12 determinations.

sive disorder of such severity that he is institutionalized. The seizures reflect the natural history of juvenile Gaucher's disease.⁶

In a discussion of our presentation at the American Pediatric Surgical Association in Puerto Rico on April 12, 1975, Folkman (*personal communication*) reported a gratifying result after portal diversion in an infant with rapidly progressive α_1 -antitrypsin deficiency. Somewhat surprisingly, his patient has had the same kind of growth spurt as seen after portacaval shunt for glycogen storage disease.

In both Gaucher's disease and α_1 -antitrypsin deficiency, it is possible to envision an improvement in health after portacaval shunt for hemodynamic reasons and without the kind of specific metabolic amelioration that has been seen after this procedure in glycogen storage disease and hyperlipidemia. On the other hand, a metabolic component to the therapeutic benefit has not by any means been ruled out.

MECHANISMS OF BENEFIT

It was pointed out earlier that increased peripheral insulin concentrations after portacaval shunt may explain the accelerated growth of the children with glycogen storage disease.

What is the explanation for the other metabolic effects of portal diversion in

this disorder beginning 1 venous block qualities than These so-called hypertrophy the basis of endogenous viscera and we have sh partly eliminated, emphy

We have venous block ity for regeneration.²¹ Such in hepatic h presumably

With e are diverted effects (Fig mentioned rently per part, the lip

These tions of liv from the su sequent ha the recom Gaucher's

As to at the pres if medical appropriate tions that proper stud forms of h

The r the syndrom animals, e

this disorder and in idiopathic hyperlipidemia? Publications from our laboratory beginning 10 years ago^{12,22} and recently summarized^{15,20,24} have shown that venous blood returning from the splanchnic organs has special liver-sustaining qualities that are not provided by equal volumes of other venous or arterial blood. These so-called hepatotrophic effects on hepatocytes include the support of hypertrophy, hyperplasia, glycogen storage, and various metabolic functions. On the basis of biochemical evidence,²⁰ we have ascribed these actions mainly to the endogenous hormones, especially insulin, that are released by the splanchnic viscera and thus arrive at the liver in high physiologic concentrations. Recently, we have shown in several experimental models in dogs that such effects are partly eliminated by the creation of alloxan diabetes or after total pancreatectomy, emphasizing again the primal hepatotrophic role of insulin.²⁴

We have also published evidence that these hormonal substances in portal venous blood which profoundly affect hepatic structure, function, and the capacity for regeneration are the same as those which subserve hepatic lipid synthesis.²¹ Such hormone effects on the liver probably assume amplified importance in hepatic homeostasis because the richness of nutrients in the same portal blood presumably contributes to significant hormone-substrate interrelations.

With end-to-side portacaval shunt, both nutritional and hormonal substances are diverted extrahepatically, and this may contribute to the desired postoperative effects (Fig. 7-12) in glycogen storage disease as well as in hyperlipidemia. As mentioned earlier, hepatic cholesterol synthesis is very significantly, and apparently permanently, depressed after portal diversion.²¹ This explains, at least in part, the lipid lowering influence of this operation.

These clinical applications accept a trade-off of distinctly suboptimal conditions of liver perfusion in return for metabolic improvements that are derivative from the suboptimal conditions. Realization of this fact, and the potential consequent hazards, will encourage a conservative and discriminating attitude about the recommendation of portacaval shunt for patients with glycogen storage or Gaucher's disease.

As to hyperlipidemia, we believe that portacaval shunt should be restricted at the present time to the highly lethal homozygous type II variety and then only if medical management fails. The certain establishment of the diagnosis and the appropriate investigation of each case require that such patients be seen in institutions that have a sophisticated interest in lipid metabolism. It is hoped that the proper study of these cases will lead to information that can be applied to other forms of hyperlipidemia and the resulting premature atherosclerosis.

THE SPECTER OF ENCEPHALOPATHY

The main reason to maintain a conservative attitude about portal diversion is the syndrome of hepatic encephalopathy, which is caused by this procedure in animals, even though they have normal livers at the time of operation. A popular

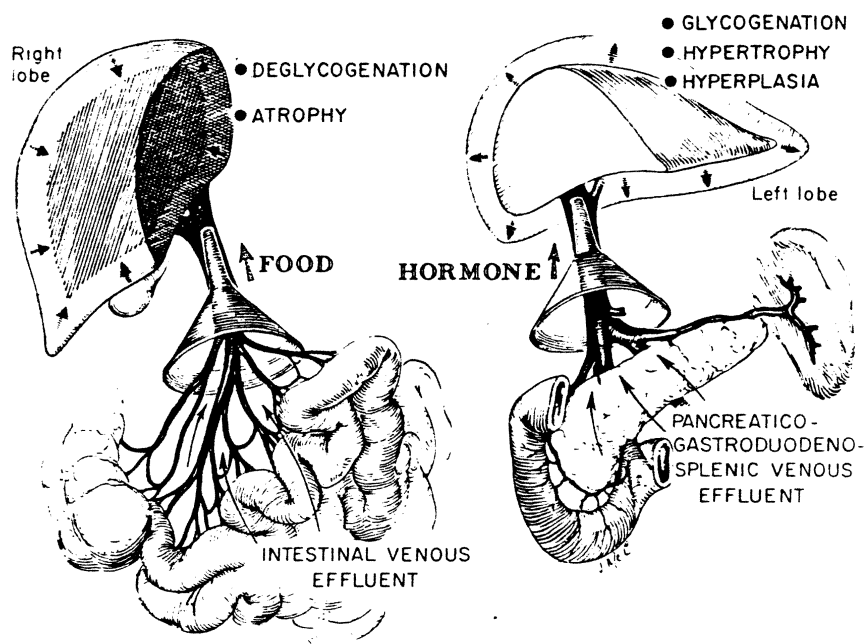


Fig. 7-12. Summary of experimental results of canine experiments²⁰ in which one portion of the liver received portal venous inflow from the pancreas and the other portion received inflow from the intestine. The "food-dominated" hepatic fragment underwent atrophy and deglycogenation, whereas the "hormone-dominated" fragment had hypertrophy, hyperplasia, and glycogen storage. These experiments which permitted dissoication of nutritional and hormonal influences indicated that the latter were more influential than the former in affecting liver structure and function. (From ref. 26.)

misconception is that the complication of encephalopathy is species specific to the dog, in which it is sometimes called "meat intoxication."

However, in a recent article,⁹ evidence was summarized and annotated showing that encephalopathy can be produced in widely divergent animal species including rodents, swine, and subhuman primates. We have studied eight baboons after complete portal diversion. Five of the animals developed typical hepatic encephalopathy within 1½ to 5 months. In addition to the neurologic manifestations, the baboons had profound weight loss, muscle wasting, and alopecia.

If there is a species peculiarity pertaining to portal diversion, the specificity would seem to be the resistance of humans to encephalopathy and other complications of the procedure. Although this has been well documented by the experience with glycogen storage disease and idiopathic hyperlipidemia, it cannot be forgotten that ruinous complications many years later are still a possibility, however remote.

SUMMARY

Portal purely hemo
ices or less c
metabolic pu
age disease.

REFERENCE

1. Boley, S. age diseas
2. Burr, I.M. parison of and portac 85:792, 19
3. Clatworthy, J., Jr.: Port hyperalime
4. Folkman, J. glycogen st surgery. Sur
5. Fredrickson. Metabolic E and D.S. Fr
6. Fredrickson. ease. In: Th Wyngaarden
7. Goldstein, J. defect in the ity associa
8. Hermann, R. storage disea
9. Hickman, R. metabolism 1974.
10. Imparato, A. Surg., 151:4
11. Lockwood, Seegmiller, disease. Dial
12. Marchioro, Physiologic r Obstet., 121:

COGENATION
ERTROPHY
ERPLASIA



HEATICO-
RODUODEN-
IC VENOUS
FLUENT

in which one
he other portion
nent underwent
ent had hyper-
mitted dissoica-
more influential

es specific to
nd annotated
imal species
ed eight ba-
oped typical
e neurologic
wasting, and

ne specificity
ther compli-
y the experi-
it cannot be
possibility,

SUMMARY

Portal venous diversion, which has been employed for many years for the purely hemodynamic objectives of stopping hemorrhage from esophageal varices or less commonly to treat intractable ascites, has now been used for specific metabolic purposes in treating three inborn errors of metabolism—glycogen storage disease, hyperlipidemia, and Gaucher's disease.

REFERENCES

1. Boley, S.J., Cohen, M.I., and Gliedman, M.L.: Surgical therapy of glycogen storage disease. *Pediatrics*, 46:929, 1970.
2. Burr, I.M., O'Neill, J.A., Karzon, D.T., Howard, L.J., and Greene, H.L.: Comparison of the effects of total parenteral nutrition, continuous intra-gastric feeding, and portacaval shunt on a patient with type I glycogen storage disease. *J. Pediatr.*, 85:792, 1974.
3. Clatworthy, W.: Discussion of Folkman, J., Philippart, A., Tze, W.-J., and Crigler, J., Jr.: Portacaval shunt for glycogen storage disease: value of prolonged intravenous hyperalimentation before surgery. *Surgery*, 72:306, 1972.
4. Folkman, J., Philippart, A., Tze, W.-J., and Crigler, J., Jr.: Portacaval shunt for glycogen storage disease: value of prolonged intravenous hyperalimentation before surgery. *Surgery*, 72:306, 1972.
5. Fredrickson, D.S., and Levy, R.I.: Familial hyperlipoproteinemia. In: *The Metabolic Basis of Inherited Disease*, edited by J.S. Stanbury, J.B. Wyngaarden, and D.S. Fredrickson, pp. 545-614. New York, McGraw-Hill, 1972.
6. Fredrickson, D.S., and Sloan, H.R.: Glucosyl ceramide lipidoses: Gaucher's disease. In: *The Metabolic Basis of Inherited Disease*, edited by J.S. Stanbury, J.B. Wyngaarden, and D.S. Fredrickson, pp. 730-759. New York, McGraw-Hill, 1972.
7. Goldstein, J.L., and Brown, M.S.: Familial hypercholesterolemia: identification of a defect in the regulation of 3-hydroxy-3-methylglutaryl coenzyme A reductase activity associated with overproduction of cholesterol. *Proc. Natl. Acad. Sci. U.S.A.*, 70:2804, 1973.
8. Hermann, R.E., and Mercer, R.D.: Portacaval shunt in the treatment of glycogen storage disease: report of a case. *Surgery*, 65:499, 1969.
9. Hickman, R., Crosier, J.H., Saunders, S.J., and Terblanche, J.: Transhepatic metabolism after end-to-side portacaval shunt in the young pig. *Surgery*, 76:601, 1974.
10. Imparato, A.M.: Gaucher's disease with ascities, response to portacaval shunt. *Ann. Surg.*, 151:431, 1960.
11. Lockwood, D.H., Merimee, T.J., Edgar, P.J., Greene, M.L., Fujimoto, W.Y., Seegmiller, J.E., and Howel, R.R.: Insulin secretion in type I glycogen storage disease. *Diabetes*, 18:755, 1969.
12. Marchioro, T.L., Porter, K.A., Dickinson, T.C., Faris, T.D., and Starzl, T.E.: Physiologic requirements for auxiliary liver homotransplantation. *Surg. Gynecol. Obstet.*, 121:17, 1965.

13. Riddell, A.G., Davies, R.P., and Clark, A.D.: Portacaval transposition in the treatment of glycogen-storage disease. *Lancet*, 2:1146, 1966.
14. Snipes, C.A.: Effects of growth hormone and insulin on amino acid and protein metabolism. *Q. Rev. Biol.*, 43:127, 1968.
15. Starzl, T.E.: Judd Lecture—Portal hepatotropic factors: a century of controversy. In: *Surgery of the Liver, Biliary Tract and Pancreas*, edited by J.S. Najarian and J.P. Delaney, pp. 495-524. New York, Intercontinental Medical Book Corp., 1975.
16. Starzl, T.E., Brown, B.I., Blanchard, H., and Bretschneider, L.: Portal diversion in glycogen storage disease. *Surgery*, 65:504, 1969.
17. Starzl, T.E., Chase, H.P., Putnam, C.W., and Nora, J.J.: Follow-up of patient with portacaval shunt for the treatment of hyperlipidemia. *Lancet*, 2:714, 1974.
18. Starzl, T.E., Chase, H.P., Putnam, C.W., Nora, J.J., Fennell, R.H., Jr., and Porter, K.A.: Portacaval shunt in hyperlipidemia. *Lancet*, 2:1263, 1974.
19. Starzl, T.E., Chase, H.P., Putnam, C.W., and Porter, K.A.: Portacaval shunt for the treatment of hyperlipoproteinemia. *Lancet*, 2:940, 1973.
20. Starzl, T.E., Francavilla, A., Halgrimson, C.G., Francavilla, F.R., Porter, K.A., Brown, T., and Putnam, C.W.: The origin, hormonal nature and action of portal venous hepatotropic substances. *Surg. Gynecol. Obstet.*, 137:179, 1973.
21. Starzl, T.E., Lee, I.-Y., Porter, K.A., and Putnam, C.W.: The influence of portal blood upon lipid metabolism in normal and diabetic dogs and baboons. *Surg. Gynecol. Obstet.*, 140:381, 1975.
22. Starzl, T.E., Marchioro, T.L., Rowlands, D.T., Jr., Kirkpatrick, C.H., Wilson, W.E.C., Rifkind, D., and Waddell, W.R.: Immunosuppression after experimental and clinical homotransplantation of the liver. *Ann. Surg.*, 160:411, 1964.
23. Starzl, T.E., Marchioro, T.L., Sexton, A.W., Illingworth, B., Waddell, W.R., Faris, T.D., and Hermann, T.J.: The effect of portacaval transposition on carbohydrate metabolism: experimental and clinical observations. *Surgery*, 57:687, 1965.
24. Starzl, T.E., Porter, K.A., Kashiwagi, N., Lee, I.-Y., Russell, W.J.I., and Putnam, C.W.: The effect of diabetes mellitus on portal blood hepatotropic factors in dogs. *Surg. Gynecol. Obstet.*, 140:549, 1975.
25. Starzl, T.E., and Putnam, C.W.: Portal diversion for glycogen storage disease and hyperlipidemia. *J.A.M.A.*, 233:955, 1975.
26. Starzl, T.E., Putnam, C.W., Porter, K.A., Halgrimson, C.G., Corman, J., Brown, B.I., Gotlin, R.W., Rodgerson, D.O., and Greene, H.L.: Portal diversion for the treatment of glycogen storage disease in humans. *Ann. Surg.*, 178:525, 1973.
27. Stein, E.A., Pettifor, J., Mieny, C., Heimann, K.W., Spitz, L., Bersohn, I., Saaron, I., and Dinner, M.: Portacaval shunt in four patients with homozygous hypercholesterolemia. *Lancet*, 1:832, 1975.
28. Torsvik, H., Feldman, H.A., Fischer, J.E., and Lees, R.S.: Effects of intravenous hyperalimentation on plasma-lipoproteins in severe familial hypercholesterolaemia. *Lancet*, 1:601, 1975.

8 Ablation as Treatment of Malignant

INTRODUCTION

Ablation of a group of diverse therapy is largely surgical approach. The greatest importance of prostate and breast cancer receptor²⁰ and thyroid cancer. It is well known that thyroid cancer responds well with endocrine ablation. This exciting advance in endocrine ablation is discussed.

THYROIDECTOMY

When a diagnosis is made, the requirements of treatment. The traditional approach can be achieved.