

507

Cardiac Transplants With Cyclosporin-A and Low-Dose Prednisone: Histologic Graduation of Rejection

B. P. Griffith, R. L. Hardesty, H. T. Bahnson, R. L. Bernsfein, and T. E. Starzl

CARDIAC histology has been reviewed in 16 patients between April 1980 and March 1981 to evaluate the effect of cyclosporin-A (CyA) and low-dose prednisone in a new trial of orthotopic cardiac transplantation. The usual maintenance dose of CyA has been 5–10 mg/kg/day, and prednisone 15–20 mg/day.¹ Hydrocortisone, 1 g intravenously, has been used to combat rejection, usually without alteration of the prednisone dose. Ninety-two endomyocardial biopsies have been performed and a minimum of three specimens from each evaluated by light microscopy. Each specimen is fixed in 10% buffered formalin and stained with hematoxylin and eosin, Masson's trichrome, and methyl-green pyronine. No mortality but some morbidity has resulted from the percutaneous endomyocardial biopsy; pericardial tamponade occurred once 6 hr following a procedure, and a second patient formed a superior mediastinal hematoma.

Morphological features and grading of rejection by endomyocardial biopsy is based on those described by Billingham for patients receiving conventional immunosuppression with azathioprine, antithymocyte globulin, and prednisone.² In this series, mild rejection has included varied degrees of lymphocytic endocardial infiltration, focal interstitial infiltration, and endocardial plus interstitial edema (Fig. 1). Moderate rejection occurs with increased monocytic infiltration and moderate myocyte necrosis. The latter feature distinguishes this group of CyA-treated patients from those treated with conventional immunosuppression in whom myocyte necrosis is rare and focal. Severe rejection has occurred with widespread necrosis and inflammation (Fig. 2). Increased active fibrosis and scar formation have been prominent following myocyte necrosis, and mild to mod-

erate round cell infiltration has persisted for more than a month after moderate to severe rejection episodes (Fig. 3). The previously described pattern of fine interstitial fibrosis attributed to CyA has been common in this series.³ During acute rejection episodes, round cells stain positively with methyl-green pyronine.

Eleven of 15 biopsies at 1 week showed no (3) or mild (8) rejection; whereas, for the subsequent 5 weeks, mild and moderate rejection approached an equal distribution (Fig. 4). Moderate rejection in 8, noted within the first 6 weeks, has improved to mild in every instance. Two of 16 patients showed severe rejection within the first 6 weeks. CyA had been withdrawn for 3 days prior to clinical rejection (2 weeks) in one instance because of renal toxicity. Hypotension and low cardiac output antedated severe histologic changes. Clinical and histologic rejection improved at 5 weeks, and at 18 weeks, mild morphological rejection correlated with a cardiac index (CI) of 2.2 liter/min/sq m and pulmonary capillary wedge pressure (PCW) of 9 mm Hg. One year posttransplantation, the biopsy showed marked interstitial fibrosis. Cardiac catheterization recorded a normal ejection fraction of 59%, but a low CI of 1.9 liter/min/sq m and widened arteriovenous oxygen difference of 6 vol %. Clinically, the patient was in controlled congestive failure but died suddenly in a dis-

From the Departments of Surgery and Pathology, University of Pittsburgh, School of Medicine, Pittsburgh, Pa.

Reprint requests should be addressed to Dr. B. P. Griffith, Department of Surgery, University of Pittsburgh, School of Medicine, 1084 Scaife Hall, Pittsburgh, Pa. 15261.

© 1983 by Grune & Stratton, Inc.
0041-1345/83/1501-0299\$01.00/0




Fig. 1. Endomyocardial biopsy showing mild acute rejection with round cell infiltration and edema of endocardium and interstitium (hematoxylin and eosin).

tant city 13 months postoperatively with a low output syndrome. Autopsy studies are pending.

Severe rejection in the second patient (4 weeks) improved to moderate, which persisted. Clinical rejection occurred at 23 weeks with moderate histologic changes. Improvement to mild rejection correlated with a CI of 2.3 and PCW of 15. Moderate fibrosis and mild rejection was noted 44 weeks postoperatively; and although this patient had developed mild congestive heart failure, his hemodynamics had not changed. Precipitous heart failure occurred at 47 weeks and resulted in death. Autopsy demonstrated diffuse interstitial fibrosis, mild acute rejection, and a left



Fig. 2. Endomyocardial biopsy showing severe acute rejection with mixed inflammatory infiltration and myocyte necrosis (hematoxylin and eosin).




Fig. 3. Endomyocardial biopsy showing marked interstitial fibrosis (Masson's trichrome).

ventricular infarction. The distal left coronary arteries were focally narrowed by severe subintimal round cell infiltration.

CyA with low-dose prednisone (15 mg/day) is effective immunosuppression for use in cardiac transplantation based on minimal clinical and generally mild to moderate histologic rejection with the first 6 weeks. The resolution of moderate (4–6 weeks) to mild (10–30 weeks) changes of rejection suggests its effectiveness. Histologic changes are generally similar to those described in a patient treated with azathioprine, antithymocyte globulin, and prednisone; however, the pattern

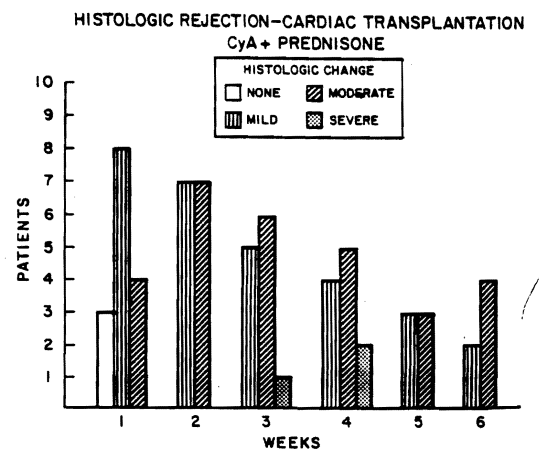


Fig. 4. Histologic gradation of endomyocardial biopsy specimens obtained from 1 to 6 weeks post-transplantation.

