

## Improved Method of Porcine Renal Allografting for Transplantation Research

KATSUHIKO YANAGA, MD  
LEONARD MAKOWKA, MD, PhD  
MITSUO SHIMADA, MD  
GUY LEBEAU, MD  
DELAWIR KAHN, MD  
LUIS A. MIELES, MD  
LINDA SHER, MD  
PAULO CHAPCHAP, MD  
LUIS G. PODESTA, MD  
THOMAS E. STARZL, MD, PhD

Department of Surgery  
University Health Center of Pittsburgh  
University of Pittsburgh  
Falk Clinic 5C  
Pittsburgh, PA 15213

**Abstract** *This study presents a refined, reproducible, and clinically appropriate animal model of renal transplantation. A pair of kidneys are harvested from a donor pig and preserved in Euro-Collins' solution (4 °C). After a set period of preservation, the allografts are transplanted to two recipient pigs. The abdomen is entered through a midline incision. The right common iliac artery and vein are dissected and bilateral native nephrectomy is performed. Each allograft is then randomly assigned and transplanted to the recipients. Three minutes before unclamping, 100 mg of furosemide and 10 g of mannitol are given IV. Immediately after reperfusion, urine output is measured for 1 h. The allograft is biopsied and ureteroneocystostomy is created. Cystostomy is then placed using a 16F Foley catheter. The bladder neck is ligated to secure complete diversion of urine, and the abdomen is closed in layers. This kidney transplant model allows an absolutely paired study of the kidney allograft function from the same donor and also collection of pure urine at any time postoperatively, obviating the need for metabolic cages or sedation for urinary collection. This model and its unique modifications allow various transplant studies, including organ preservation, immunosuppressive protocol, and the prevention of reperfusion injury from oxygen free radicals.*

**Keywords** Transplantation, kidney, animal experiment.

### Introduction

There has been enormous progress in human solid organ transplantation during the last 25 years. Factors for the improved results include advances in immunosuppres-

This work was supported by research grants from the Veterans Administration and Project Grant AM 29961 from the National Institute of Health, Bethesda, MD.

Address correspondence to Thomas E. Starzl, MD, PhD, Department of Surgery, University Health Center of Pittsburgh, University of Pittsburgh, Falk Clinic 5C, 3601 Fifth Avenue, Pittsburgh, PA 15213.

sion,<sup>1</sup> organ procurement and preservation,<sup>2,3</sup> and tissue typing.<sup>4</sup> To further improve the outcome of organ transplantation, it is essential to investigate, in animals, appropriate experimental models that closely simulate the clinical situation. Herein, we describe an improved porcine kidney transplant model, in which two kidney allografts from a single donor are transplanted into recipients in a paired fashion.

### **Experimental Model**

Outbred pigs of either sex, weighing 15–35 kg are used in this experimental model.

#### ***Donor Operation***

The donor pig is anesthetized with 25 mg/dL of thiamylal IV and 100% oxygen is administered through an endotracheal tube. The abdomen is prepped and draped in a sterile fashion. The peritoneal cavity is then entered through a midline incision and the terminal as well as the suprarenal abdominal aorta is encircled. The inferior vena cava and renal veins are dissected and the left adrenal, gonadal, and lumbar veins are divided between ligatures. During the dissection, diuresis is promoted by infusion of 50 mL/kg of lactated Ringer's solution, followed by 100 mg of furosemide and 10 g of mannitol IV. Following the administration of 5000 units of heparin IV, the terminal aorta is cannulated with a 16-French chest tube. Immediately after the suprarenal aorta is cross-clamped, the kidneys are flushed with 1000 mL of Euro-Collins' solution (4 °C). After the kidneys are completely flushed and cold, the ureters are dissected to the level of bladder, and the kidneys are harvested en bloc with the ureters. The kidneys are divided by splitting the aorta and the inferior vena cava longitudinally. The renal arteries and veins are trimmed, and the allografts are packed in a sterile bag and stored at 4 °C for variable periods according to the protocol.

#### ***Recipient Operation***

At a defined period of preservation after the aortic cross-clamp, the kidney allografts are transplanted into two recipient pigs. The pigs are intubated after IV induction with 25 mg/kg of thiamylal and maintained on a respirator with 40% oxygen. For the maintenance of anesthesia, thiamylal, ketamine, and pancuronium bromide are administered IV. The abdomen and neck are prepped and draped in a sterile fashion. Through a cervical incision, arterial and central venous pressure lines are placed in the carotid artery and external jugular vein. A total of 50 mL/kg of lactated Ringer's solution is given IV through the central venous line prior to revascularization of the graft.

Cephalosporins are added to the first bag of intravenous fluid. The peritoneal cavity is then entered through a midline incision and the right common iliac artery as well as the iliac vein are dissected. Bilateral native nephrectomies are performed and each renal allograft is randomly assigned to and transplanted into the two recipients. The terminal right common iliac artery is divided and the proximal common iliac artery is reflected cephalad to expose the right iliac vein. A curved vascular clamp is applied to a segment of the right external iliac vein and a longitudinal venotomy is made on the anterior aspect. The lumen of the iliac vein is irrigated with heparinized saline and then the venous anastomosis is performed in an end-to-side fashion of the donor renal vein to the recipient external iliac vein using continuous 6-0 Novafil

(blue monofilament polybuterester, Davis & Geck Monofil Inc, Manati, PR) suture. The proximal right common iliac artery is then transected just proximal to the 2-0 silk ligature and the lumen is flushed with heparinized saline. The arterial anastomosis is then performed in an end-to-end fashion between the donor renal artery and the recipient common iliac artery using continuous 7-0 Novafil suture. Three minutes before completion of the arterial anastomosis, 100 mg of furosemide and 10 g of mannitol are given IV. The arterial and venous vascular clamps are then released. Immediately after unclamping, 100 mg of methylprednisone and 2 mg/kg of azathioprine are given IV, and then the gross appearance of the graft at the time of reperfusion is recorded. The distal donor ureter is cannulated to measure urine output during the first hour. One hour after unclamping, 80 mg of furosemide is given IV, and the allograft is biopsied.

Ureteroneocystostomy is performed using Lich's method<sup>5</sup> with 6-0 Novafil continuous sutures. Cystostomy is performed using a 16-French Foley catheter, which is secured to the bladder wall with 3-0 silk purse-string sutures and brought out to and secured to the anterior abdominal wall through a separate stab wound (Fig 1). The bladder neck is then ligated with a 2-0 silk tie to ensure complete diversion of urine through the cystostomy catheter. The catheter is secured to the skin with a 2-0 silk suture and then connected to a sterile bag (Fig 1). The abdomen is closed in layers, using continuous 2-0 Maxon (green monofilament polyglyconate, Davis & Geck Monofil Inc, Manati, PR) sutures for the linea alba and continuous 3-0 Dexon vertical mattress sutures for the skin. The cervical wound is closed with 3-0 Dexon. The arterial as well as central venous lines are secured to the skin with 2-0 silk sutures and capped after flushing with heparinized saline solution. The vessel catheters are secured to the neck with the sponges and adhesive tape to avoid accidental dislodgement. The urine bag is also secured to the body with adhesive tape. The animal is warmed by heat lamp, extubated when fully awake, and then returned to the cage.

### ***Postoperative Care***

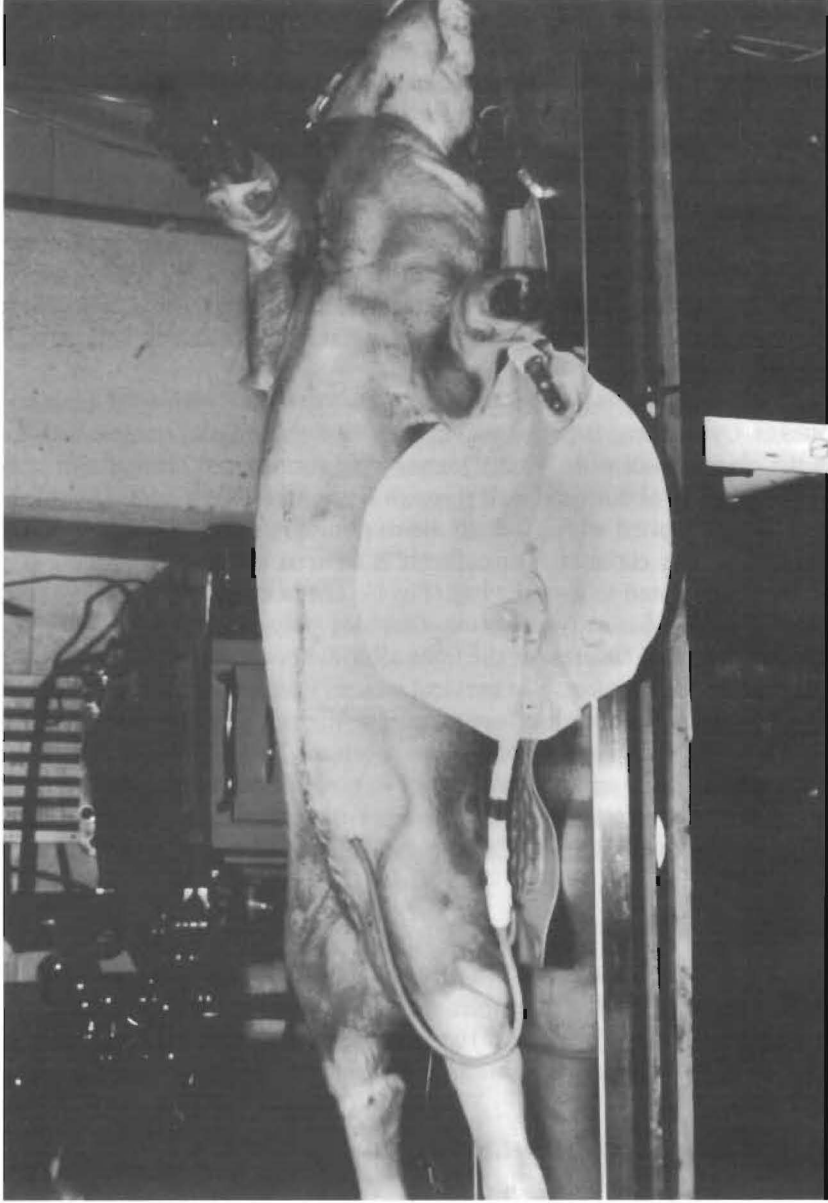
The animals are fed brown sugar on the day of transplantation, followed by their regular diet on the next day. Blood samples are drawn daily, and immunosuppression consists of 2 mg/kg of azathioprine and 10 mg of methylprednisone IV daily through the central venous line. Cephalosporins are administered IV twice daily for 5 days.

### ***Evaluation of Kidney Allograft Function***

Intraoperative parameters of allograft function consist of the characteristics of graft reperfusion, initial 1-h urine output, and histology of the allograft biopsy at 1 h after revascularization. Postoperatively, daily blood work consists of urea nitrogen, creatinine and electrolytes, and urine is collected daily for volume measurement, electrolytes, and urea nitrogen. At the time of sacrifice, the appearance of the transplanted kidney and the patency of the vascular and ureteric anastomoses are examined. A portion of the allograft is saved and processed for histological evaluation.

### **Results**

Using this experimental model, 20 pairs of kidney transplantation were performed in pigs after 24 h of preservation in Euro-Collins' solution. Also, sham kidney trans-



**Figure 1.** Cystostomy with a 16-French Foley catheter is brought out to the abdominal wall through a separate stab wound. The bladder neck is ligated to ensure complete diversion of urine through the cystostomy.

**Table 1**  
Causes of Failure in Transplantation of 24-h Preserved Kidneys in Pigs

Causes	Number
Technical failure	3/20 (15%)
Warm ischemia during the donor procedure	1
Difference in vascular anastomosis time	1 <sup>a</sup>
Inability to collect urine	1
Others	2/20 (10%)
Aspiration	1
Accelerated rejection	1
Total	5/20 (100%)

<sup>a</sup> 22-min difference.

plantation was performed in 4 pigs (normal control group). Of the 20 pairs of kidney transplantation performed, 5 pairs (25%) were excluded from the study; the causes of failure are listed in Table 1. Table 2 lists the laboratory data of animals following transplantation of the kidney preserved in Euro-Collins' solution or sham operation.

### Comments

The important features of the kidney transplant model described in this report are that it allows both an absolute paired study of kidney allograft function from the same donor, as well as the collection of the entire quantity of pure urine at any time postoperatively. The latter obviates the need for metabolic cages or sedation of the

**Table 2**  
Laboratory Data Following Porcine Renal Transplantation or Sham Operation

Variable	24-h Preserved Kidney (n = 15)	Sham Operated Kidney (n = 4)
BUN (mg/dL)		
Preoperative	11.8 ± 5.6 <sup>a</sup>	13.5 ± 6
POD 1	65 ± 15.5	13 ± 5.2
POD 2	90.9 ± 18.8	14.5 ± 4.5
Creatinine (mg/dL)		
Preoperative	1.1 ± 0.3	0.9 ± 0.2
POD 1	6.1 ± 3.1	0.9 ± 0.1
POD 2	7.9 ± 3.4	1.0 ± 0.1
Creatinine clearance (mg/min)		
POD 2	6.6 ± 8.8	28.5 ± 0.8 <sup>b</sup>

<sup>a</sup> Means ± SD.

<sup>b</sup> Data of a single kidney.

animal for collection of urine. Furthermore, the only difference of this model from clinical cadaveric renal transplantation is that the donor is not brain-dead. Therefore, this model and the unique modifications reported here allow the investigation of important transplant research, such as organ preservation, immunosuppression, and the prevention of reperfusion injury from oxygen free radicals. Furthermore, this model gives surgical residents and fellows an opportunity to refine their technical skills, and to be trained in the procedure and biology of kidney transplantation.

## References

1. Starzl TE, Hakala TR, Iwatsuki S, et al. The use of cyclosporin A and prednisone in cadaver kidney transplantation. *Surg Gynecol Obstet.* 1980;151:17-26.
2. Starzl TE, Hakala TR, Shaw BW, et al. A flexible procedure for multiple cadaveric organ procurement. *Surg Gynecol Obstet.* 1984;158:223-230.
3. Belzer FO, Southard JH. Principles of solid-organ preservation by cold storage. *Transplantation* 1988;45:673-676.
4. Terasaki PI, Marchioro TL, Starzl TE. Serotyping of human lymphocyte antigens: preliminary trials on long-term kidney homograft survivors. In: Russell PS, Winn JH, Amos DB, eds. *Histocompatibility Testing 1965*. Washington, DC: National Academy of Science; 1965:83.
5. Lich R, Jr, Howerton LW, Davis LA. Recurrent urosepsis in children. *J Urol.* 1961;86:554-562.