

REFERENCES

1. Carter SK. Adriamycin—a review. *JNCI* 1975; 55: 1265–74.
2. Blum RH, Carter SK. Adriamycin, a new drug with significant clinical activity. *Ann Intern Med* 1974; 80: 249–59.
3. Blum RH. An overview of studies with adriamycin in the United States. *Cancer Chemother Rep* 1975; 6: 247–51.
4. Von Hoff DD, Rozenzweig M, Piccart M. The cardiotoxicity of anticancer agents. *Semin Oncol* 1982; 9: 23–33.
5. Praga C, Beretta G, Vigo PL, et al. Adriamycin cardiotoxicity: a survey of 1273 patients. *Cancer Treat Rep* 1979; 63: 827–34.
6. Von Hoff DD, Rozenzweig M, Layard M, Slavik M, Muggia FM. Daunomycin induced cardiotoxicity in children and adults: a review of 110 cases. *Am J Med* 1977; 62: 200–08.
7. Dearth J, Osborn R, Wilson E, et al. Anthracycline-induced cardiomyopathy in children: A report of 6 cases. *Med Pediatr Oncol* 1984; 12: 54–58.
8. Bristow MR, Mason JW, Billingham ME, Daniels JR. Dose-effect and structure-function relationships in doxorubicin cardiomyopathy. *Am Heart J* 1981; 102: 709–18.
9. Marchandise B, Schroeder E, Bosly A, et al. Early detection of doxorubicin cardiotoxicity: interest of doppler echographic analysis of left ventricular filling dynamics. *Am Heart J* 1989; 118: 92–98.
10. Hausdorf G, Morf G, Beron G, et al. Long-term doxorubicin cardiotoxicity in childhood: non-invasive evaluation of the contractile state and diastolic filling. *Br Heart J* 1988; 60: 309–15.

SHORT REPORTS

Replacement of donor lymphoid tissue in small-bowel transplants

YUICHI IWAKI THOMAS E. STARZL
ATSUHIITO YAGIHASHI SATOSHI TANIWAKI
KAREEM ABU-ELMAGD ANDREAS TZAKIS
JOHN FUNG SATORU TODO

The presence of recipient lymphocytes in grafts is thought to equate with rejection. Thus, we wished to follow the fate of lymphocytes after transplant of the small bowel. Three complete small-bowel transplants, two with the liver from the same donor also transplanted, were done successfully. Patients were immunosuppressed with FK 506. 5 to 11% of lymphocytes in the recipients' peripheral blood were of donor origin during the early postoperative period when there were no clinical signs of graft-versus-host disease. However, donor cells were no longer detectable after 12 to 54 days. Serial biopsy specimens of the grafted small bowel showed progressive replacement of lymphocytes in the lamina propria by those of the recipient's HLA phenotype. Lymphoid repopulation was complete after 10 to 12 weeks but the epithelial cells of the intestine remained those of the donor. The patients are on enteral alimentation after 5, 6, and 8 months with histopathologically normal or nearly normal intestines. Re-examination of assumptions about the rejection of intestinal grafts and strategies for its prevention are required following these observations.

Lancet 1991; 337: 818–19.

Little is known about the fate and function of lymphocytes in intestinal grafts, partly because long-term survival after transplant of the small intestine has been difficult to achieve. The first successful complete small-intestine transplant in man¹ was accomplished with continuous intravenous infusion of cyclosporin. The patient briefly had donor lymphocytes in peripheral blood during the early postoperative phase and at the same time had symptoms of graft-versus-host disease (GVHD). We have

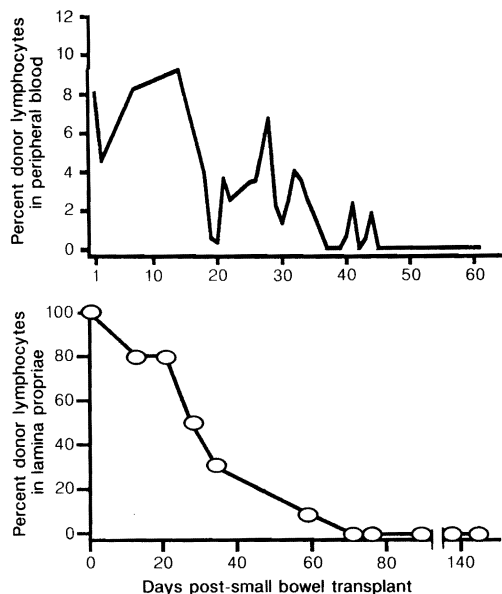
followed the fate of host and donor lymphocytes in three patients treated with FK 506—one after small-bowel transplant and two after combined liver-intestine grafting.

Patient 1 lost the entire small bowel and most of the colon 5 months before transplant after a gun shot wound of the superior mesenteric artery; liver function was normal. Patients 2 and 3 had had total small-bowel resection several years earlier because of necrotising enterocolitis and thrombosis of the superior mesenteric artery, respectively, and both had liver failure following parenteral hyperalimentation. All grafts received arterial blood from the aorta, and intestinal venous outflow was through the liver of patient 1 or through the liver grafts of patients 2 and 3. FK 506 for immunosuppression was given intravenously at first (0.1 mg/kg per day) and later enterally (0.3 mg/kg per day in divided doses). Maintenance doses of FK 506 were lower. Prednisolone was given initially and later stopped (patients 2 and 3) or reduced (patient 1). Patients were maintained on intravenous nutrition for at least 2 months before starting jejunostomy and, ultimately, oral feeding. Patients 1 and 2 have had normal gastrointestinal continuity restored, and patient 3 is still being fed through a nasogastric tube with its tip advanced into the graft jejunum.

Peripheral blood lymphocytes were isolated with 'Ficoll-Hypaque' (Pharmacia LKB) and stored in liquid nitrogen until tested. Lymphocytes were added to monoclonal antibodies (One Lambda Inc, Los Angeles), fixed in 2% paraformaldehyde-phosphate buffer solution, and identified by flow cytometry ('FACScan', Becton Dickinson). Monoclonal antibodies were also used for immunocytochemical identification of lymphocyte HLA phenotypes in biopsy specimens obtained through jejunal and ileal stomas.

During the first week after transplant, between 5 and 11% of the circulating lymphocytes of all patients were of the donor type (figure). However, after 12–54 days donor lymphocytes were no longer detectable. The proportion of donor lymphocytes in the lamina propria of patient 1 decreased from 80% at 21 days post-transplant to 30% after 35 days and 0% after 70 days (figure). Jejunal and ileal biopsies showed the same pattern of change. Donor lymphocytes were replaced by host lymphocytes in patients 2 and 3 after 77 and 84 days, respectively.

Our finding of recipient lymphocyte repopulation of chronically functioning intestinal grafts, and similar results in rats treated with FK 506,² indicate that presence of recipient lymphocytes in the graft does not necessarily equate with rejection.³ What do we know about the fate and function of the lymphoid component of intestinal or multivisceral grafts? In non-immunosuppressed dogs receiving multivisceral transplants the intestine was rejected and there was histopathological evidence of GVHD within 1 week.⁴ Subsequently, the consequences of GVHD (parent



Proportion of donor lymphocytes in peripheral blood and lamina propria after small-bowel transplant (patient 1).

to F_1 hybrid) were separated from those of rejection (F_1 to parent) in inbred rats.⁵ The design of these experiments rendered either the recipient or intestinal graft vulnerable to immunological attack by the other, whereas under clinical circumstances both immune systems are activated. It is unlikely that alteration of the graft lymphoid system could be achieved more efficiently by pretransplant manipulations (such as irradiation or antilymphocyte globulin) than occurred with the use of potent immunosuppression in our patients and in rats.² Donor pretreatment was not used in the three cases we report, nor in a fourth with only 7 weeks of follow-up. GVHD was not encountered. Histocompatible bone-marrow transplant experiments in rats show that FK 506 given prophylactically prevents GVHD.⁶ Established GVHD has been reversed with FK 506 in human bone-marrow recipients.⁷ This may be important if, as seems likely, the migrated donor lymphocytes have survived and are diffusely established in recipient tissue.

Lymphoreticular repopulation is not a unique feature of intestinal or multivisceral grafts. The macrophage system in human liver grafts switches completely to that of the recipient within 100 days.⁸ Fung et al.^{9,10} have described graft lymphoid tissues in transition after human heart-lung and liver transplant. Thus, lymphoreticular repopulation probably occurs with successful transplant of any lymphoid-containing graft. Whether this contributes to graft acceptance should be the subject for future inquiry.

Supported by the University of Pittsburgh Pathology Education, and Research Fund, project grant DK 29961 from the National Institutes of Health, and by a grant from the Veterans Administration.

REFERENCES

- Grant D, Wall W, Mimeault R, et al. Successful small-bowel/liver transplantation. *Lancet* 1990; 335: 181-84.
- Murase N, Demetris AJ, Matsuzaki T, et al. Long-term survival in rats after multivisceral versus isolated small bowel allotransplantation under FK 506. *Surgery* (in press).
- Ingham Clark CL, Cunningham AJ, Crane PW, Wood RFM, Lear PA. Lymphocyte infiltration patterns in rat small-bowel transplants. *Transplant Proc* 1990; 22: 2460.
- Starzl TE, Kaupp HA Jr, Brock DR, Butz GW Jr, Linman JW. Homotransplantation of multiple visceral organs. *Am J Surg* 1962; 103: 219-29.
- Monchik GJ, Russell PS. Transplantation of the small bowel in the rat: technical and immunologic considerations. *Surgery* 1971; 70: 693-702.
- Markus PM, Cai X, Ming W, Demetris AJ, Starzl TE, Fung JJ. Prevention of graft-versus-host disease following allogeneic bone marrow transplantation in rats using FK 506. *Transplantation* (in press).
- Tzakis AG, Fung JJ, Todo S, Reyes J, Green M, Starzl TE. Use of FK 506 in pediatric patients. *Transplant Proc* 1991; 23: 924-27.
- Gouw ASH, Houthoff JH, Huitema S, Beelen JM, Gips CH, Poppema S. Expression of major histocompatibility complex antigens and replacement of donor cells by recipient ones in human liver grafts. *Transplantation* 1987; 43: 291-96.
- Fung JJ, Zeevi A, Kaufman C, et al. Interactions between bronchoalveolar lymphocytes and macrophages in heart-lung transplant recipients. *Hum Immunol* 1985; 14: 287-94.
- Fung JJ, Zeevi A, Demetris AJ, et al. Origin of lymph node derived lymphocytes in human hepatic allografts. *Clin Transplant* 1989; 3: 316-24.

ADDRESSES: Departments of Surgery (Prof Y. Iwaki, MD, PhD, Prof T. E. Starzl, MD, PhD, A. Yagihashi, MD, PhD, S. Taniwaki, MD, K. Abu-Elmagd, MD, A. Tzakis, MD, J. Fung, MD, PhD, S. Todo, MD, PhD) and Pathology (Y. Iwaki), University of Pittsburgh School of Medicine, Pittsburgh, Pennsylvania, USA. Correspondence to Prof T. E. Starzl, Department of Surgery, 3601 Fifth Avenue, 5C Falk Clinic, Pittsburgh, PA 15213, USA.

Oncogene expression in cervical intraepithelial neoplasia and invasive cancer of cervix

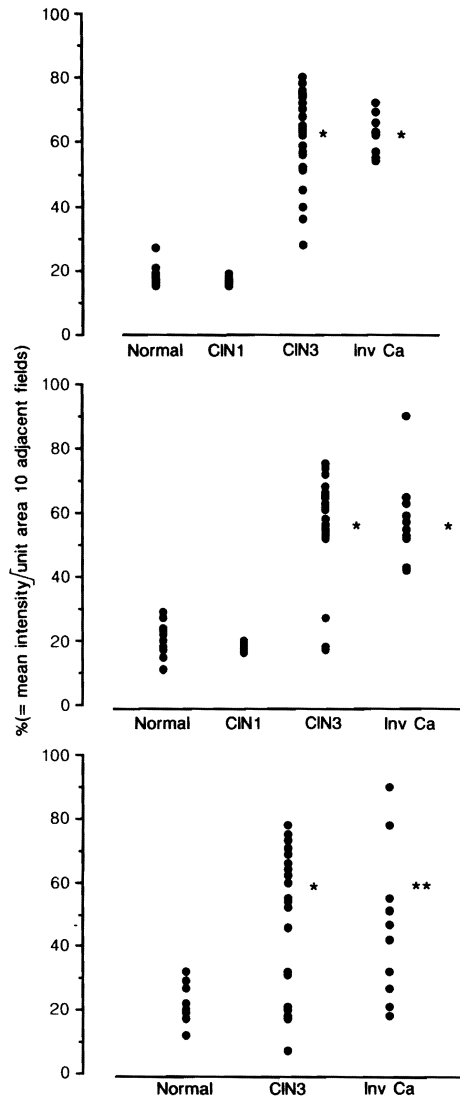
SHEENA B. PINION JAMES H. KENNEDY
RONALD W. MILLER ALLAN B. MACLEAN

Expression of the oncogenes Ha-RAS, c-MYC, and ERB-2 was investigated with an automated image analysis system in 12 specimens of normal cervix, 10 of cervical intraepithelial neoplasia (CIN) grade 1, 24 of CIN 3, and 10 of invasive cancer of the cervix. There was amplification of all three oncogenes in CIN 3 and invasive cancer compared with normal cervix and CIN 1. The difference was most pronounced with an antibody to the RAS p21 protein, with no overlap between CIN 3 and the normal range. This method might be useful in screening for cervical neoplasia, and for the determination of which CIN lesions require treatment.

Lancet 1991; 337: 819-20.

Altered oncogene activity has been noted in many malignant diseases¹ as well as in premalignant states such as villous adenoma of the rectum² and atypical hyperplasia of the endometrium.³ Several workers have shown altered Ha-RAS and c-MYC expression in malignant disease of the cervix⁴ and have related this to prognosis⁵⁻⁷ and cell type.⁸ Cervical intraepithelial neoplasia (CIN) has also been studied, with conflicting results.^{4,9,10}

We investigated expression of the oncogenes Ha-RAS, c-MYC, and ERB-2 in histological sections of normal cervix (n = 12), cervical intraepithelial neoplasia (10 CIN 1 and 24 CIN 3), and invasive cancer of the cervix (10) to see if there was a difference that could be helpful in screening, treatment, or prognosis.



RAS (upper), MYC (middle), and ERB (lower) expression in cervix.

* $p < 0.0001$, RAS, MYC, vs normal; * $p < 0.005$ vs normal; ** $p < 0.0005$ ERB vs normal.

Normal cervical tissue was obtained from patients with no history of cervical neoplasia and who were undergoing hysterectomy for benign disease. The histological diagnosis of normal cervix, CIN, or invasive cancer was confirmed on haematoxylin and eosin stained slides of adjacent sections of tissue. Slides were deparaffinised and rehydrated, then incubated for 40 minutes each with a murine monoclonal antibody (IgG or IgM) specific for the oncoprotein (p21 for Ha-RAS, Stratech, London; p45 for c-MYC and p185 for ERB-2, Cambridge Research Biochemicals), biotinylated anti-mouse IgG or IgM, and streptavidin-Texas red or fluorescein isothiocyanate (Amersham UK, and Sigma UK, Dorset), with thorough washing in phosphate-buffered saline between steps. With this method, one slide could be stained for two oncoproteins. The slides were examined with a fluorescent microscope with a $\times 50$ water immersion objective, and a 'System 3' image analyser (Micro Measurements, Saffron Walden, Essex). Fields were visually selected, the detector level was set to display fluorescent areas without background interference, and the results were expressed as a percentage, which was equivalent to the mean intensity per unit area of ten adjacent non-overlapping fields. Results were analysed with the Mann Whitney U test for non-parametric data.

The results for the three oncogenes are shown in the figure. For Ha-RAS, normal cervix and CIN 1 had closely similar levels of activity; CIN 3 and invasive cancer showed increased activity, but did not differ significantly. The CIN 3/invasive range did not overlap with the range for normal cervix. For c-MYC, results for normal/CIN 1 and CIN 3/invasive cancer differed significantly, but there was some overlap between normal and CIN 3. With ERB-2, CIN 3/invasive cancer results were significantly different from those for the normal cervix, although there was obvious overlap between the three groups.

With this method of fluorescent antibody staining of oncoproteins, amplification of the oncogenes Ha-RAS, c-MYC, and ERB-2 in malignant and premalignant cervical epithelium is seen when compared with the normal cervix. It has been suggested that CIN should be reclassified as low-grade and high-grade, reflecting the different malignant potential. Our findings of similar staining of CIN 1 and normal epithelium would perhaps support the theory that progression to high-grade CIN is not inevitable. All the invasive cancers studied had a high level of c-MYC and Ha-RAS expression, so it is unlikely that this method can provide a useful prognostic indicator. Since all the specimens of CIN 3 and invasive cancer showed increased Ha-RAS expression, with no overlap with the normal range, it may be that this method could be adapted for screening. We plan to apply this technique to cervical cytology smears to see if it can reliably identify patients with high-grade CIN.

This work would not have been possible without the cooperation of Dr J. Scholefield of the Department of Biomedical Instrumentation at Strathclyde University, and Dr F. Lee and the Pathology Department at Glasgow Royal Infirmary.

REFERENCES

- Slamon DJ, deKernion JB, Verma IM, Cline MJ. Expression of cellular oncogenes in human malignancies. *Science* 1984; 224: 256-62.
- Thor A, Hand PH, Wunderlich D, Caruso A, Muraro R, Schlom J. Monoclonal antibodies define differential ras gene expression in malignant and benign colonic diseases. *Nature* 1984; 311: 562-65.
- Long CA, O'Brien TJ, Sanders MM, Bard DS, Quirk JG. Ras oncogene is expressed in adenocarcinoma of the endometrium. *Am J Obstet Gynecol* 1988; 159: 1512-16.
- Di Luca D, Costa S, Monini P, et al. Search for human papillomavirus, herpes simplex virus and cmc oncogene in human genital tumours. *Int J Cancer* 1989; 43: 570-77.
- Riou G, Barrois M, Le MG, Le Doussel V, George M, Haie C. Cmyc proto-oncogene expression and prognosis in early carcinoma of the uterine cervix. *Lancet* 1987; i: 761-63.
- Riou G, Barrois M, Dutronquay V, Orth G. Presence of papillomavirus DNA sequences, amplification of cmyc and cHa-ras oncogenes and enhanced expression of cmyc in carcinomas of the uterine cervix. In: Howley P, Brocker T, eds. *Papillomaviruses: molecular and clinical aspects*. New York: Alan R. Liss, 1985: 47-56.
- Sowani A, Ong G, Dische S, et al. Cmyc oncogene expression and clinical outcome in carcinoma of the cervix. *Cell Probes* 1989; 3: 117-23.
- Sagae S, Kuzumaki N, Hisada T, Mugikura Y, Kudo R, Hashimoto M. Oncogene expression and prognosis of invasive squamous cell carcinomas of the uterine cervix. *Cancer* 1989; 63: 1577-82.
- Hendy-Ibbs P, Cox H, Evan GI, Watson JV. Flow cytometric quantitation of DNA and cmyc oncoprotein in archival biopsies of uterine cervix neoplasia. *Br J Cancer* 1987; 55: 275-82.
- Hughes RG, Neill WA, Norval M. Papillomavirus and cmyc antigen expression in normal and neoplastic cervical epithelium. *J Clin Pathol* 1989; 42: 46-51.

ADDRESSES: Department of Gynaecology, Aberdeen Royal Infirmary, Foresterhill, Aberdeen AB9 2ZB, UK (S. B. Pinion, MRCOG); Department of Gynaecology, Glasgow Royal Infirmary, Glasgow (J. H. Kennedy, FRCOG); Department of Biomedical Instrumentation, University of Strathclyde, Glasgow (R. W. Miller, MPhil), and Department of Gynaecology, Western Infirmary, Glasgow (A. B. MacLean, FRCOG). Correspondence to Miss S. B. Pinion.