

# The Systemic Distribution of Epstein–Barr Virus Genomes in Fatal Post-transplantation Lymphoproliferative Disorders

## An In Situ Hybridization Study

Parmjeet S. Randhawa,\* Ronald Jaffe,†  
Anthony Jake Demetris,\* Michael Nalesnik,‡  
Thomas E. Starzl,|| Yuan-Yuan Chen,¶ and  
Lawrence M. Weiss¶

From the Departments of Pathology\* and Surgery,||  
Presbyterian University Hospital, and the Departments of  
Pathology, Childrens Hospital† and Veterans Administration  
Hospital,‡ Pittsburgh, Pennsylvania; and the City of Hope  
National Medical Center,¶ Duarte, California

*The systemic distribution of Epstein–Barr virus (EBV) genomes was studied in paraffin-embedded tissues from 12 fatal cases of Post-transplantation lymphoproliferative disease (PTLD), using an in situ hybridization technique employing an alpha-<sup>35</sup>S-dCTP–radiolabeled BamHI-W fragment of EBV DNA. The presence of EBV was documented in various PTLD-involved organs. The hybridization signal for the virus localized predominantly in the abnormal lymphoid cells, but signals also were detected in hepatocytes and/or adrenal cortical cells in five cases. The distribution of autoradiographic label within the lymphoid cells was focal and its intensity varied from field to field, suggesting a nonuniformity of the viral genomic load in the infected tissues. Recruitment of EBV genome-bearing cells was not observed into inflammatory mononuclear infiltrates found in organs without histopathologic evidence of PTLD. (Am J Pathol 1991, 138:1027–1033)*

Epstein–Barr virus (EBV) is a common cause of infectious mononucleosis in young individuals. In this disease, initial infection is thought to occur through the oropharyngeal epithelium, with subsequent transmission of the virus to B lymphocytes. The virus induces proliferation and transformation of B cells, which in turn elicits a reactive prolifer-

ation of T-suppressor and cytotoxic cells, responsible for limiting the B-cell proliferation in normal individuals.<sup>1,2</sup> The clinical manifestations of infectious mononucleosis, eg, the tonsillar enlargement, lymphadenopathy, splenomegaly, hepatomegaly, and atypical lymphocytosis generally are explained on the basis of these B- and T-lymphocyte proliferations. During active disease, EBV genomes can be demonstrated in tonsils, lymph nodes, and peripheral blood, and persistence of EBV in oropharyngeal secretions and the parotid and lacrimal glands, but not lymphoid tissues, has been reported in subjects with a previous history of infection.<sup>3–8</sup> Cultures of B lymphocytes from asymptomatic seropositive individuals exhibit spontaneous transformation to EBV-positive lymphoblastoid cell lines, indicating the presence of low levels of latent virus presumably immortalized within B cells.<sup>9</sup>

When the normal immune mechanisms of an individual are compromised, as in inherited immunodeficiency, X-linked lymphoproliferative syndrome, systemic chemotherapy, and the Acquired Immune Deficiency Syndrome, EBV can proliferate unbridled and affect unusual locations.<sup>10–17</sup> Although EBV genomes have been demonstrated by Southern blotting, in extralymphoid organs in patients with such overwhelming systemic infections, it is not known whether in these cases the virus remains confined to lymphoid cells.<sup>18,19</sup> To address this issue, we used a <sup>35</sup>S-labeled EBV DNA probe and *in situ* hybridization methodology to examine the precise cellular localization and distribution of EBV genomes in multiple organs from 12 fatal cases of post-transplantation lymphoproliferative disease (PTLD) developing in the setting of cyclosporine/prednisone immunosuppression.

Supported in part by grant HL 13108 from the National Institutes of Health and by the Pathology Education Research Foundation, Pittsburgh, Pennsylvania.

Accepted for publication December 14, 1990.

Address reprint requests to A. J. Demetris, Department of Pathology, Presbyterian University Hospital, Pittsburgh, PA 15213.

## Materials and Methods

Cases were selected from the autopsy files at the Children's Hospital of Pittsburgh and the Presbyterian University Hospital, Pittsburgh, Pennsylvania. Seven of the patients were in the pediatric age group and five were adults. Post-transplantation lymphoproliferative disease was confirmed histopathologically in each case using previously published criteria.<sup>13</sup> Tissues were fixed in 10% neutral buffered formalin, embedded in paraffin, cut into 3- $\mu$  sections, and mounted on slides precoated with 3-aminopropyltriethoxysilane (Sigma Chemical Co., St. Louis, MO) as previously described.<sup>4</sup> Sections of vertebral bone marrow were decalcified in 5% nitric acid before paraffin embedding and sectioning. A total of 76 blocks were selected from 12 cases to ensure adequate representation of PTLD lesions in all major organ systems (Table 1). Tissues with PTLD-negative inflammatory infiltrates also were included in the study.

Clinical and microbiologic data pertaining to these cases were obtained from the autopsy protocols and hospital records. *In situ* hybridization was performed, as previously reported, on pronase-digested sections using a specific probe consisting of the *Bam*-*HI*-*W* fragment of EBV DNA, radiolabeled with alpha-<sup>35</sup>S-dCTP<sup>4</sup>. Autoradiographic exposures used an overlay of Kodak NTB2 emulsion (Rochester, NY) and lasted 10 to 14 days. After development of the emulsion, the sections were counterstained with hematoxylin and eosin. The efficacy of the procedure was monitored by a parallel run of nasopharyngeal lymphoepithelioma tissue known to contain EBV genomes.<sup>20</sup> Negative controls included histologically normal pediatric liver and adrenal tissue, as well as similar tissue with infiltrates of acute lymphocytic leukemia. The slides were assessed qualitatively and a clear deposition of grains in excess over the background level (3:1 or higher, signal-to-noise ratio) was considered to represent a positive result (Figure 4a, b). The sensitivity of EBV detection by the *in situ* hybridization protocol described here previously was estimated to be approximately 12 copies of EBV genome per cell.<sup>4</sup>

## Results

A summary of our histopathology and *in situ* hybridization findings by individual organs is shown in Table 1. Sections of the lungs were studied in 10 cases, eight of which showed PTLD involvement with EBV genome-bearing cells randomly scattered in the PTLD infiltrates. The hybridization signal varied from weak to intense. No labeling was observed over bronchial epithelium, smooth muscle,

endothelium, or alveolar lining cells. Infectious agents such as Cytomegalovirus, Candida, Staphylococcus, Enterobacter, Klebsiella, and Pseudomonas were cultured from PTLD tissues in all eight cases.

The myocardium was examined in nine cases and PTLD infiltrates were found in four cases, present in the epicardial fat as well as interstitially within the cardiac muscle tissue. The EBV labeling was confined to lymphoid cells and varied from only scattered cells hybridizing with the probe to strong autoradiographic signals seen in a majority of the cells. No signals were detected on myocardial or connective tissue cells. A section taken from the aorta in case 8 did not hybridize with the probe.

The livers showed histologic evidence of PTLD in seven of the eight cases. Epstein-Barr virus DNA was found in a majority of the infiltrating lymphoid cells, with the labeling intensity varying from weak to intense (Figure 1). Scattered hepatocytes also showed labeling in four cases (1, 2, 4, and 7), all of whom were children in the age range of 5 to 15 years (Figure 2a, b). No grains above background levels were detected in the biliary epithelium or hepatic reticuloendothelial cells.

The kidneys manifested histopathologic evidence of PTLD in seven of the nine cases. Distribution of PTLD within the organs was global with cortex, medulla, as well as the peripelvic soft tissues affected. Infiltrates were present in periglomerular, intraglomerular, peritubular, and intravascular locations (Figure 3). Epstein-Barr virus genomes were found only in the lymphoid cells. The labeling intensity varied from case to case and field to field as in other organs.

Examination of the spleen in eight cases showed PTLD with expansion of the white pulp and simultaneous infiltration of the red pulp. Epstein-Barr virus genomes were found in six cases. Lymph node tissues sampled from two cases showed diffuse labeling of lymphoid cells in areas of PTLD. The thymus examined in one case did not show evidence of hybridization with the probe.

Adrenal glands were evaluated in six cases and PTLD infiltrates were found in five cases, involving the cortex, the medulla and the periadrenal fat. Hybridization signals of variable intensity were found scattered randomly throughout these lymphoid infiltrates. Scattered foci of adrenal cortical cells with specific labeling were noted in two children (cases 4 and 6; Figure 4a, b).

Decalcified sections of vertebral bone marrow in six cases showed a hypercellular marrow with PTLD cells accounting for 60% to 90% of the total cell population present in five cases. *In situ* hybridization revealed scattered, weakly labeled EBV-positive lymphoid cells in only two cases, but eosinophils and eosinophil precursors were labeled intensely in all cases, apparently due to a nonspecific disulfide bond formation between <sup>35</sup>S-labeled DNA and a protein in the eosinophilic granules.

Table 1. Distribution of Epstein-Barr Virus in Tissues of Patients with Post-transplant Lymphoproliferations

#	Age Sex	Clinical setting	Tissues studied	Distribution of PTLD	Distribution of EBV genomes	Infectious agents in PTLD Tissues	Tissues with EBV-ve inflammatory infiltrates
1	15 F	Liver transplantation, biliary atresia	Adrenals, brain, bone marrow, kidney, liver, lung, thyroid, parotid	All tissues studied	All tissues studied (including hepatocytes)	Lung, CSF: Staphylococcus, alpha hemolytic Streptococcus	None
2	11 F	Liver transplantation, biliary cirrhosis	Adrenal, heart, liver, lung	Adrenal, liver, lung	Adrenal, liver (including hepatocytes), lung	Lung: Alpha streptococci, cytomegalovirus	Heart: myocarditis with gram + ve cocci
3	11 F	Liver transplant, inflammatory pseudotumor	Brain, heart, kidney, lung, stomach	Heart, kidney, lung, stomach	Heart, kidney, lung, stomach	Disseminated Candida, Aspergillus	None
4	5 M	Liver transplant, biliary atresia	Adrenal, kidney, liver, spleen	All tissues studied	Adrenal & liver (including epithelium), kidney, spleen	Liver: Escherichia coli, Acenitobacter anitratus	None
5	3 M	Liver transplant, alpha antitrypsin deficiency	Bone marrow, kidney, heart, lung, spleen	All tissues studied	All tissues studied	Lung: Staphylococcus, Enterococcus; Kidney: Adenovirus; Spleen: Candida	None
6	11 F	Liver transplant, familial intrahepatic cholestasis	Adrenal, bone marrow, heart, kidney, liver, lung, pancreas, spleen, thymus, ileum	Adrenal, spleen, ileum	Adrenal (including epithelium), spleen, ileum	Adrenal, ileum: Candida	Heart, kidney, liver, lung: Candidiasis & torulopsis
7	14 F	Heart transplant, mitral prolapse	Heart, kidney, liver, lung, spleen	All tissues studied	Heart, kidney, liver (including hepatocytes), lung, spleen	Lung: Alcaligenes denitrificans, Candida	None
8	20 M	Heart transplant, pulmonary veno-occlusive disease	Aorta, colon, lymph node, ileum, spleen	Colon, lymph node, ileum, spleen	Lymph node, ileum	None	None
9	34 M	Kidney transplant, membranous glomerulopathy	Adrenal, marrow, heart, kidney, liver, lung, pancreas, ileum, spleen, stomach	Bone marrow, kidney, liver, ileum, spleen, stomach	Kidney, liver, ileum, spleen, stomach	Spleen: Staphylococcus aureus, Enterococcus	Lung: Staphylococcus, Klebsiella, Pseudomonas
10	54 M	Liver transplant, ethanol cirrhosis and hepatocellular carcinoma	Bone marrow, heart, lymph node, lung, spleen	All tissues studied	Lymph node, spleen	Lung: Enterobacter cloacae, Pseudomonas aeruginosa, Spleen: Enterobacter	None
11	42 M	Heart transplant, idiopathic congestive cardiomyopathy	Bone marrow-heart, kidney, liver, lung, testis	Bone marrow, kidney, lung, liver, testis	Liver, lung, testis	Lung: Pseudomonas aeruginosa	Heart: fibrinous pericarditis, cellular rejection
12	18 M	Heart transplant, primary pulmonary artery hypertension	Adrenal, colon, heart, kidney, liver, lung, pancreas, ileum, spleen	Adrenal, colon, liver, lung, spleen, ileum	Adrenal, colon, liver, ileum, lung	Lung: Pseudomonas aeruginosa	Heart: fibrinous pericarditis, cellular rejection; kidney: tubular necrosis

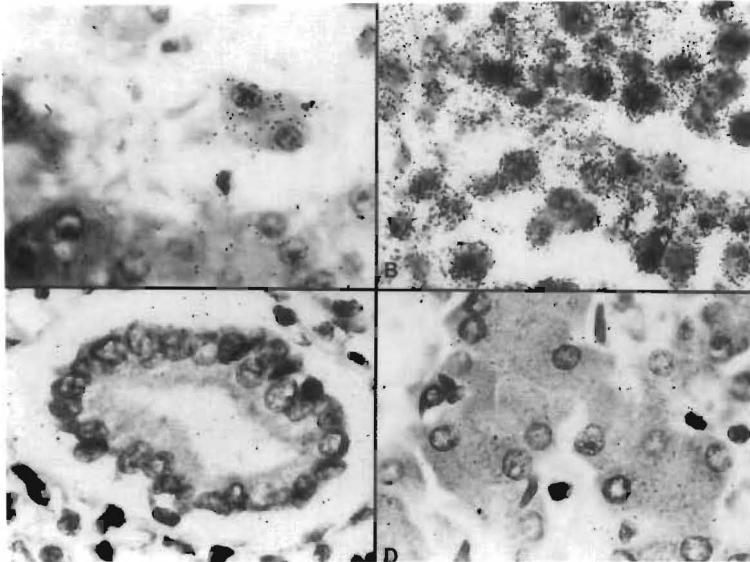


Figure 1. Liver tissue with PTLD lesions showing labeling of hepatocytes (upper left), and portal tract infiltrates (upper right), but not of the bile duct epithelium (lower left). The level of background labeling observed in hepatocytes and reticuloendothelial cells from control livers is also illustrated (lower right). Hematoxylin and eosin stain,  $\times 1250$ .

This nonspecific staining of eosinophilic cells also was found in control bone marrow tissues.

The gastrointestinal tract was sampled in five cases with histologic evidence of involvement by PTLD. Epstein-Barr virus genomes were found in seven of eight sections of typical lesions in the stomach, small intestine, and colon. Labeling was confined to the lymphoid cells, which permeated the entire gut wall. The lining epithelium, glands, vascular endothelium, and smooth muscle showed no labeling. Lymphocytic infiltrates in the parotid gland in one case showed EBV-positive cells. Pancreatic tissue studied in three cases showed no histologic evidence of PTLD and no EBV localization.

### Discussion

This study confirms the previously reported near-universal association of EBV with PTLD occurring in solid organ transplant recipients.<sup>13</sup> Epstein-Barr virus-positive lymphoid cells were demonstrated in all patients in a wide variety of organs sampled at autopsy. The organ distribution, percentage of cell staining, and the intensity of staining in different cells varied considerably from case to case. This could reflect differences in the degree of autolysis and fixation conditions; such factors are difficult to control for in a retrospective study of archival material. However different tumor cells in the same microscopic

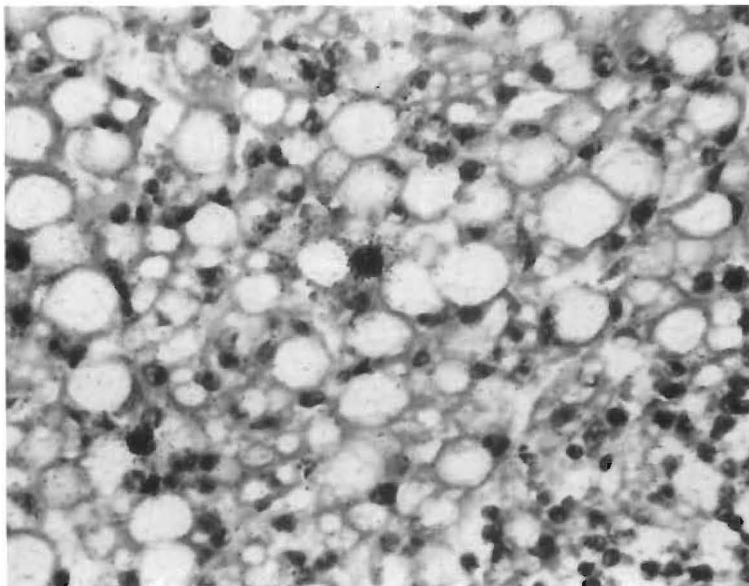


Figure 2. Panoramic view of markedly steatotic liver parenchyma showing focal autoradiographic signals over hepatocytes. Hematoxylin and eosin stain,  $\times 500$ .

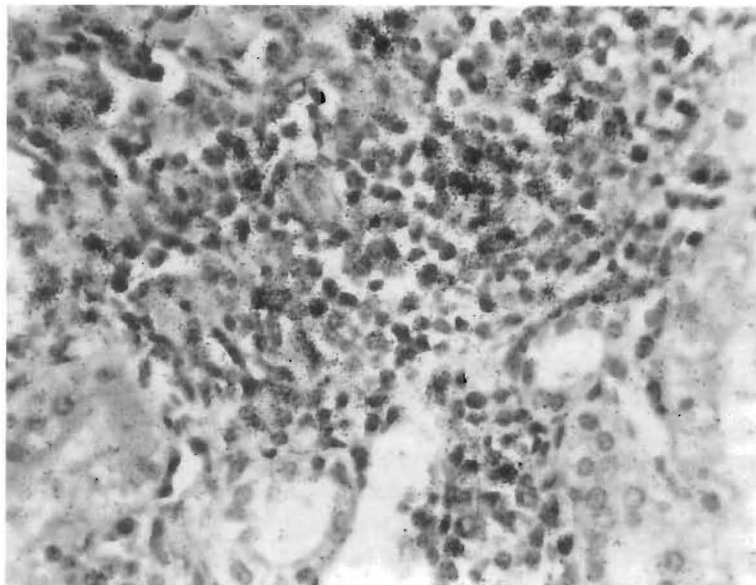


Figure 3. EBV-infected lymphoid cells in renal interstitial PTLD infiltrates. No tubular epithelium labeling is seen. Hematoxylin and eosin stain,  $\times 500$ .

field, all apparently equally well preserved morphologically, showed variation in the intensity of their hybridization signals. Consequently it is probable that the actual viral genomic load in lymphoid cells is not distributed uni-

formly throughout PTLD lesions. A variable number of cells may be in the lytic, rather than the latent, phase of the infection.<sup>21</sup> Heterogeneity in hybridization with specific EBV DNA probes also has been observed in virus-infected cell lines,<sup>22</sup> and attributed in part to differences in the level of mitotic activity between cells.<sup>23,24</sup>

It is well known that lymphoid tissues are the major target of infection for the EBV. In fully immunocompetent subjects, the oropharyngeal mucosa and the parotid and lacrimal glands seem to be the only epithelial tissues capable of harboring EBV.<sup>6-8</sup> However it seemed possible to us that, under conditions of immunosuppression, a wider range of tissues might become susceptible to the virus. On careful observation autoradiographic signals were indeed demonstrable over cells unequivocally recognized as hepatocytes (four cases) and adrenal cortical cells (two cases) by their location, relationship to other parenchymal cells, rectangular to polygonal shapes, and abundant cytoplasm.

This demonstration of EBV genomes in the hepatocytes and adrenals of four children is a novel and very significant finding. We believe that the signals observed represent true hybridization: histologically normal pediatric liver and adrenals, as well as similar tissues with infiltrates of acute lymphocytic leukemia, did not show any nonspecific deposition of silver grains over epithelial cells ( $n = 12$ ). The mechanism of EBV entry into the liver and adrenal cells is a matter for speculation. Virus entry into target cells is believed to be critically dependent on the expression of a specific EBV/C3d receptor. Initially it was believed that the EBV receptor occurs only on B cells.<sup>25-27</sup> However subsequently receptors have been documented on T-cell, null cell, and other hematopoietic cell lines, platelets, oropharyngeal epithelium, and human ectocervix.<sup>28-33</sup> The EBV receptor has not been

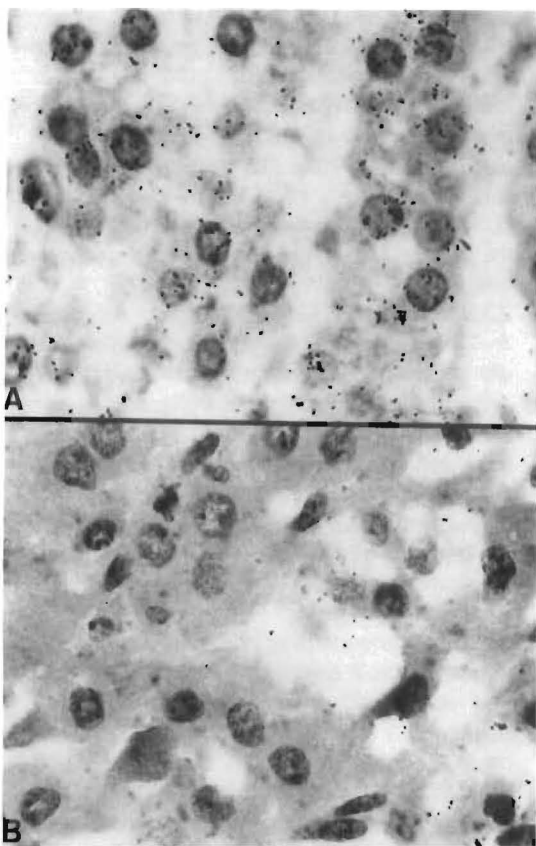


Figure 4. Nuclei of adrenal cortical cells from case 4 (A) show EBV hybridization signals distinctly stronger than those observed in control tissue (B). Hematoxylin and eosin stain,  $\times 1250$ .

documented yet on either adrenal cells or on hepatocytes. However hepatitis is a common clinical manifestation of disseminated EBV syndromes occurring in immunosuppressed liver transplant recipients.<sup>34</sup> While such hepatitis may be largely mediated by lymphocyte-driven cytotoxic mechanisms, electron microscopy has documented the occurrence of viruslike particles within the liver cells, in fatal EBV-induced infectious mononucleosis.<sup>35</sup> Our demonstration of EBV genomes within hepatocytes in four cases extends this observation. We are not aware of any studies that demonstrate the presence, or for that matter, the absence of the EBV/C3d receptor on hepatocytes. In the absence of such receptors, penetration of the virus into the liver cells could, perhaps, result from emperipolesis, a phenomenon described in hepatitis B virus infection.<sup>36</sup> Alternately we can speculate that the EBV nucleocapsid could acquire an envelope from an unrelated epitheliotropic virus, and thus effect entry into the liver cells.<sup>37</sup>

One final observation afforded by the study was that the distribution of EBV in these cases appeared to be organ restricted rather than generalized. In five patients there were organs free of PTLD, but which had inflammatory mononuclear infiltrates in which EBV genomes could not be demonstrated, at least within the limits of detection of our *in situ* hybridization procedure (Table 1). The underlying causes of these inflammatory infiltrates varied widely and included bacterial myocarditis with gram-positive cocci, disseminated cryptococcosis/torulopsis, mixed bacterial pneumonia, and fibrinous pericarditis. Post-transplantation lymphoproliferative disease infiltrates in these same patients at other organ sites showed the presence of EBV genomes in tissue infiltrates, as well as inside the lumen of several small blood vessels. The failure of the inflammatory response to recruit intravascular EBV-positive cells into organs not affected by PTLD leads us to speculate that EBV transformation of circulating lymphocytes perhaps leads to loss of endothelial-adhesion molecule expression on the cell surface.<sup>38</sup> Such a functional defect would interfere with the transcapillary migration of lymphocytes into sites of inflammation within individual organs.

## References

1. Jandl JH: Infectious mononucleosis. In Jandl JH, ed. Blood. Boston, Little Brown, 1987, pp 537-545
2. Sixbey JW, Nedrud JG, Raab-Traub N, Hames RA, Pagano JS: Epstein-Barr virus replication of oropharyngeal epithelial cells. N Engl J Med 1984; 310:1225-1230.
3. Niedobitek G, Hamilton-Dutoit S, Herbst H, Finn T: Identification of Epstein-Barr virus-infected cells in tonsils of acute infectious mononucleosis by *in situ* hybridization. Hum Pathol 1989; 20:796-799.
4. Weiss LM, Movahed LA: *In situ* demonstration of Epstein-Barr viral genomes in viral-associated B cell lymphoproliferations. Am J Pathol 1989; 134:651-659.
5. Hinuya Y, Saito T, Yamanato J, Hiroshima Y, Sudoh H, Deguchi M, Motokowa M: Simultaneous presence of EBNA positive and colony forming cells in peripheral blood of patients with infectious mononucleosis. Int J Cancer 1979; 23:746-750.
6. Wolf H, Haus M, Wilmes E: Persistence of Epstein-Barr virus in the parotid gland. J Virol 1984; 51:795-798.
7. Crouse CA, Pflugfelder SC, Demick SM, Atherton SS: Detection of Epstein-Barr virus genomes in normal human lacrimal glands. J Clin Microbiol 1990; 28:1026-1032.
8. Strauch B, Sigel N, Andrews LL, Miller G: Oropharyngeal excretion of Epstein-Barr virus in renal transplant recipients and other patients on immunosuppressive drugs. Lancet 1974; i:234-237.
9. Nilsson K, Klein G, Henle W, Henle G: The establishment of lymphoblastoid cell lines from adult and fetal lymphoid tissue, and its dependence on EBV. Int J Cancer 1971; 8:443-450.
10. Reece ER, Gartner JG, Seemayer TA, Joncas JG, Pagano JS: Epstein-Barr virus in a malignant lymphoproliferative disorder of B cells occurring after thymic epithelial transplantation for combined immunodeficiency. Cancer Res 1981; 41:4243-4247.
11. Markin RS, Linder J, Zuerlein K, Mroczek E, Grierson HL, Brichacek B, Putilo DT: Hepatitis in fatal infectious mononucleosis. Gastroenterology 1987; 93:1210-1217.
12. Putilo DT: Epstein-Barr-virus induced oncogenesis in immune-deficient individuals. Lancet 1980; i:300-303.
13. Nalesnik MA, Jaffe R, Starzl TE, Demetris AJ, Porter K, Burnham JA, Makowka L, Ho M, Locker J: The pathology of post-transplant lymphoproliferative disorders occurring in the setting of cyclosporine-A prednisone immunosuppression. Am J Pathol 1988; 133:173-192
14. Zutter M, Martin PJ, Sale GE, Shulman HM, Fisher L, Thomas ED, Durham DM: Epstein-Barr virus lymphoproliferation after bone marrow transplantation. Blood 1988; 72:520-529
15. Andiman WA, Eastman R, Martin K, Katz BZ, Rubinstein A, Pitt J, Pahwa S, Miller G: Opportunistic lymphoproliferations associated with Epstein-Barr viral DNA in infants and children with AIDS. Lancet 1985; ii:1390-1393
16. Hanto DW, Sakamoto K, Putilo DT, Simmons RL, Najarian JS: The Epstein-Barr virus in the pathogenesis of post-transplant lymphoproliferative disorders. Surgery 1981; 90:204-213
17. Cleary ML, Warnke R, Sklar J: Monoclonality of lymphoproliferative lesions in cardiac-transplant recipients. N Engl J Med 1984; 310:477-482
18. Ho M, Miller G, Atchison RW, Breinig MK, Dummer JS, Andiman W, Starzl TE, Eastman R, Griffith BP, Hardesty RL, Bahnson HT, Hakala TR, Rosenthal JT: Epstein-Barr virus infections and DNA hybridization studies in post-transplant lymphoma and lymphoproliferative lesions: The role of primary infection. J Infect Dis 1985; 152:876-886

19. Locker J, Nalesnik M: Molecular genetic analysis of lymphoid tumors arising after organ transplantation. *Am J Pathol* 1989; 135:977-987
20. Weiss LM, Movahed LA, Butler AE, Swanson SA, Frierson HF, Cooper PH, Colby TV, Mills SE: Analysis of lymphoepithelioma and lymphoepithelioma-like carcinomas for Epstein-Barr virus by in-situ hybridization. *Am J Surg Pathol* 1989; 13:625-631
21. Katz BZ, Raab-Traub N, Miller G: Latent and replicating forms of Epstein-Barr virus DNA in lymphomas and lymphoproliferative diseases. *J Infect Dis* 1989; 160:589-598
22. Bashir R, Hochberg F, Singer RH: Detection of Epstein-Barr virus by in situ hybridization. Progress toward development of a non-isotopic diagnostic test. *Am J Pathol* 1989; 135:1035-1044
23. Teo CG, Griffith BE: Epstein-Barr virus genomes in lymphoid cells: Activation in mitoses and chromosomal location. *Proc Natl Acad Sci* 1987; 84:8473-8477
24. De Souza YG, Greenspan D, Felton JR, Hartzog GA, Hammer M, Greenspan JS: Localization of Epstein-Barr virus DNA in the epithelial lesions of oral hairy leukoplakia by in-situ hybridization on tissue sections. *N Engl J Med* 1989; 320:1559(letter)
25. Nemerow GR, Wolfert R, McNaughton ME, Cooper NR: Identification and characterization of the Epstein-Barr virus receptor on human B lymphocytes and its relationship to the C3d complement receptor (CR 2). *J Virol* 1985; 55:347-351
26. Wells A, Koide N, Stein H, Gerdes J, Klein G: The Epstein-Barr virus receptor is distinct from the C3 receptor. *J Gen Virol* 1983; 64:449-453
27. Gervais F, Wills A, Leyritz M, Lebrun A, Joncas JH: Relative lack of EBV receptors on B cells from persistently EBV seronegative adults. *J Immunol* 1980; 126:897-900
28. Patel P, Menezes J: EBV-lymphoid interactions: I. Quantification of EBV particles required for the membrane immunofluorescence assay, and the comparative expression of EBV receptors on different human B, T and null cell lines. *J Gen Virol* 1981; 53:1-11
29. Tatsumi E, Harada S, Kuszynski C, Volsky D, Minowada J, Purtilo DT: Catalogue of EBV receptors on human malignant and non-malignant hematopoietic cell lines. *Leukemia Res* 1985; 9:231-238
30. Takimoto T, Sato H, Ogura H, Miyawaki T, Glaser R: Superinfection of epithelial hybrid cells (D-98/HR-1, NPC-kt and A2L/AH) with Epstein-Barr virus and the relationship to the C3d receptor. *Cancer Res* 1986; 46:2541-2544
31. Sixbey J, David D, Young L, Hutt-Fletcher L, Tedder TF, Rickinson AB: Human epithelial expression of an Epstein-Barr virus receptor. *J Gen Virol* 1987; 63:805-811
32. Young L, Sixbey J, Clark D, Rickinson AB: Epstein-Barr virus receptor on human pharyngeal epithelia. *Lancet* 1986; i:240-242
33. Bush JL: The Epstein-Barr virus receptor. *Lab Med* 1989; 20:318-324
34. Randhawa PS, Markin R, Starzl T, Demetris AJ: Epstein-Barr virus associated syndromes in immunosuppressed liver transplant recipients: Clinical profile and recognition on routine allograft biopsy. *Am J Surg Pathol* 1990; 14:538-547
35. Chang MY, Campbell WG: Fatal infectious mononucleosis associated with liver necrosis and Herpes like particles. *Arch Pathol* 1975; 99:185-191
36. Scheuer PJ: Viral hepatitis. In MacSween RM, Anthony PP and Scheuer PJ, eds. *Pathology of the Liver*, Second Edition. Edinburgh, Churchill Livingstone, 1987, p. 218
37. Shapiro I, Klein G, Volsky D: Epstein-Barr virus core reconstituted with Sendai virus envelopes infects Epstein-Barr virus receptor negative cells. *Biochem Biophys Acta* 1981; 676:19-24
38. Thomas JA, Hotchin NA, Allday MJ, Amlot P, Rose M, Yacoub M, Crawford DH: Immunohistochemistry of Epstein-Barr virus-associated antigens in B cell disorders from immunocompromised individuals. *Transplantation* 1990; 49:944-953