

1283

Renal Transplantation Under FK 506 in Patients With Previous Loss of Renal Function Due to Hemolytic Uremic Syndrome

J. McCauley, R. Shapiro, O. Bronster, M. Jordan, D. Ellis, N. Gliboa, V. Scantlebury, C. Jensen, A. Jain, and T. Starzl

HEMOLYTIC uremic syndrome (HUS) is a disorder characterized by hemolysis, thrombocytopenia, and renal failure. This syndrome may be epidemic, primary, familial, associated with autoimmune illness such as SLE, or due to cyclosporine (CyA) therapy. We have previously reported the first patient successfully treated with FK 506 to control CyA-induced HUS.¹ Although FK 506 was used only as substitution therapy, this patient's response has raised the hope that FK 506 might reduce the recurrence rate in renal transplant patients who have previously developed renal failure due to HUS. We will update our experience with renal transplant patients who have previously developed renal failure due to HUS and are subsequently treated with FK 506. In addition, we discuss one complicated patient who developed a syndrome very similar to HUS for the first time while receiving FK 506.

PATIENTS AND METHODS

All patients receiving renal transplants under FK 506 with the diagnosis of HUS as the cause of renal failure in their native kidneys or in transplanted renal grafts are included in this series. Four patients with primary HUS and one patient with familial HUS were included. In addition, there were two patients with loss of renal function due to CyA-induced HUS. An additional patient with SLE, previous splenectomy for thrombocytopenia, and subsequent development of thrombocytopenia and thrombosis in a renal graft will be discussed.

The immunosuppression protocol has been described previously.^{2,3} General goals of management include rapid tapering of prednisone and discontinuance if possible, and progressive rapid reductions in FK 506 dosage until the minimum quantity is attained. All patients receive Bactrim and acyclovir prophylactic therapy for pneumocystis and CMV.

RESULTS

Primary and Familial HUS

From September 1989 to December 1990 five patients with histories of renal failure due to HUS in the native kidneys received cadaveric renal transplants at the University of Pittsburgh under FK 506 (Table 1). One patient (5) developed HUS (diarrhea, microangiopathic hemolytic anemia, thrombocytopenia and renal failure) at age 3 months. Although renal function and the hematologic abnormalities improved, the patient experienced three relapses of HUS in 1 month and developed irreversible renal failure. A maternal aunt died of HUS at 1 year of age. The first cadaveric renal transplant was performed at age 11 months. He was treated with corticosteroids, CyA, aspirin, and heparin. Five days posttransplant he developed gross hematuria, thrombocytopenia, hemolytic anemia,

Table 1. Patients With History of HUS Transplant Under FK 506*

Patient	Age	Graft No.	Months	Outcome
1	32	5	13	Functioning
2	10	1	20	Functioning
3	3	1	8	Functioning
4	8	1	7	Functioning
5	11 mos	2	0.5	†Recurred

*20% recurrence rate.
†Familial HUS.

and worsening graft function. Despite a reduction in CyA dosage, addition of azathioprine and hemodialysis, an allograft nephrectomy was performed 10 weeks after transplantation, which resulted in improvement of the hematologic abnormalities.

At 4 years of age a second cadaveric renal transplant was performed under FK 506. Postoperative treatment included heparin and corticosteroids. The allograft functioned well until 5 days after surgery when gross hematuria, hemolytic anemia, and oliguria developed. He was initially treated with Persantine and plasmapheresis without effect. On the seventh postoperative day defibrotide and human gamma globulin were substituted for these agents but the HUS persisted. On the fifteenth postoperative day an allograft nephrectomy was performed with complete resolution of hematologic abnormalities.

The remaining four patients with primary HUS have excellent function and have no evidence of recurrent HUS. Patient 1 had lost four previous grafts under CyA, but we could not document recurrence of HUS as the cause in any graft.

CyA-Induced HUS

Two patients with CyA-induced HUS resulting in loss of renal function have been transplanted under FK 506. The first patient was a 33-year-old man who developed HUS after an orthotopic liver transplant. This patient was the first patient treated with FK 506 for HUS and has been previously reported.¹ He had chronic renal failure due to

From the Departments of Medicine and Surgery, University of Pittsburgh School of Medicine, Presbyterian-University Hospital, and the Veterans Administration Medical Center, Pittsburgh, Pennsylvania.

Address reprint requests to Jerry McCauley, MD, 709 Lhormer Building, Transplant Surgery Division, University of Pittsburgh School of Medicine, Pittsburgh, PA 15213.

© 1991 by Appleton & Lange
0041-1345/91/\$3.00/+0

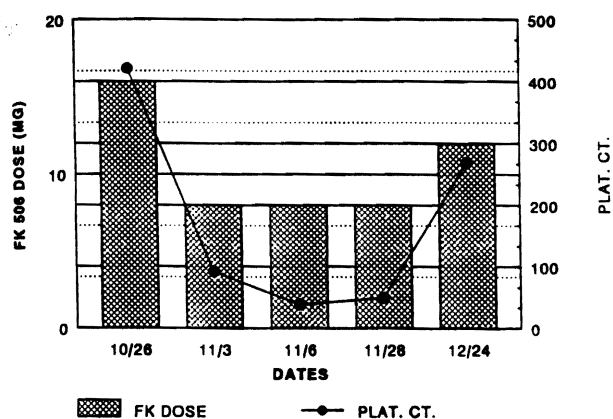


Fig 1. Clinical course of a patient with CyA-induced HUS during tapering of FK 506 dosage.

CyA at the time HUS developed. After a rapid recovery from HUS upon initiation of FK 506, the patient's hematologic picture worsened with rapid reduction in FK 506 dosage (Fig 1). When the FK 506 dosage was restored to an intermediate level, the platelet count also rose to an intermediate but adequate level. The patient's renal function, however, worsened and dialysis was required. A renal transplant was performed approximately 1 year later. After 18 months the patient has no evidence for recurrence. A slow and deliberate decrease in FK 506 dosage has been conducted since the kidney transplantation.

The second patient lost a cadaveric renal allograft due to CyA-induced HUS. The cause of renal failure in his native kidneys was focal sclerosing glomerulonephritis (FSGS). A second transplant was performed on January 14, 1991. After 7 months his hematologic picture is normal and graft function is excellent. There has been no evidence for recurrent HUS or FSGS.

THROMBOCYTOPENIA IN A RENAL TRANSPLANT PATIENT UNDER FK 506

A 36-year-old woman with renal failure due to SLE received a cadaveric renal transplant on May 4, 1990. Thrombocytopenia (50,000 cells) was present at the time SLE was first discovered in 1978. Persistent thrombocytopenia (minimum 20,000 cells) prompted a splenectomy in 1982. After splenectomy, the platelet count was approximately 200,000 except during flares when platelet counts fell to approximately 500-900.

Following transplantation, prednisone was rapidly tapered and discontinued within 1 month. Two months posttransplant creatinine was 1.2 mg/dL and platelet count 664,000, and the patient complained of pain in knees and generalized aches. Changes in FK 506 dosage and platelet count are illustrated in Fig 1. The hematologic picture was normal until the FK 506 dose was transiently decreased from 8 mg twice per day to 6 mg twice daily. Platelet count briefly fell from 672,000 to 588,000 and recovered after FK 506 was again increased to 8 mg twice daily. Seven months

posttransplant the patient developed dyspnea and a dry cough. Severe dyspnea prompted an admission in which bronchiolitis obliterans was diagnosed on lung biopsy. Despite FK 506 levels of 1.0 ng/mL (therapeutic) the dosage was reduced to 6 mg twice daily and 60 mg of prednisone was added. Eight days later she was admitted with a platelet count of 30,000 and creatinine of 2.7 mg/dL. FK 506 was discontinued and azathioprine was substituted.

A renal biopsy performed on January 17, 1991 revealed widespread glomerular capillary thrombosis. Daily plasmapheresis, vincristine, and platelet transfusions were given until February 27, 1991 when renal function and platelet count improved. During this admission, however, total bilirubin never rose greater than 0.5 mg/dL although LDH reached 743 IU/L. This admission was also complicated by CMV esophagitis and later CMV pneumonitis. Leukopenia, thought to be related to CMV and gancyclovir, also developed. Hematology consultation during that admission questioned whether high-dose Bactrim therapy for possible pneumocystis, CMV infection, or heparin infusions contributed to the thrombocytopenia. At latest follow-up creatinine is 1.0 mg/dL on azathioprine and prednisone.

DISCUSSION

Recurrence of hemolytic uremic syndrome after renal transplantation occurs frequently. The pathogenesis of HUS remains essentially unknown and may not be identical for all forms.

Our recent preliminary experience suggests that FK 506 may be an effective substitute therapy in CyA-induced HUS. Both patients with CyA-induced HUS in this series have not developed recurrence and both currently have excellent graft function. In our first patient, the platelet count fell when FK 506 was rapidly tapered but later remained stable when a much slower dose reduction was performed. This may suggest that the HUS was only under control in the early treatment period and potentially active. Great care should be exercised in reducing the dosage of FK 506 in these patients.

FK 506 may also allow patients with primary HUS to obtain renal allografts without a high risk of recurrence. None of the patients with primary HUS, and without the familial form, developed a recurrence after transplantation. However, patients with familial or rapidly recurrent HUS under CyA seem to be at great risk of recurrence under FK 506 therapy. Although we have treated only one such patient, it is clear that FK 506 may not prevent recurrence of all types of HUS. The patients who are most likely to benefit from FK 506 therapy and the poor prognostic indicators will be determined by treatment of larger number of these patients.

The patient with a HUS-like syndrome is very complicated but may suggest that de novo HUS is possible with FK 506 therapy. Problematic issues include a previous

history of persistent thrombocytopenia resulting in splenectomy, SLE (which is associated with TTP and HUS), the absence of hyperbilirubinemia (suggesting minimal hemolysis), and the development of other factors that could cause thrombocytopenia (CMV infection, ganciclovir therapy, high-dose Bactrim therapy). Despite these confounding problems, our limited experience certainly does not rule out the possibility that FK 506 may cause HUS. Interestingly, the changes in platelet count and the onset of the HUS-like syndrome was associated with a

reduction in FK 506 dosage. This parallels the experience of our patient with CyA-induced HUS. It is possible that FK 506 was actually controlling an autoimmune process leading to thrombocytopenia in this lupus patient.

REFERENCES

1. McCauley J, Bronster O, Fung J, et al: *Lancet* ii:1516, 1989
2. Shapiro R, Jordan M, Johnston J, et al: *Transplant Proc* 23:920, 1991
3. Starzl TE, Fung JJ, Jordan M, et al: *JAMA* 264(1):63, 1990