

CYTOMEGALOVIRUS INFECTION AND GASTRIC EMPTYING^{1,2}

D. H. VAN THIEL,³ J. S. GAVALER,⁴ R. R. SCHADE,⁴ M-C. CHIEN,⁴ AND T. E. STARZL⁵

The Department of Surgery and Medicine, the University of Pittsburgh School of Medicine, Pittsburgh, Pennsylvania 15213

Gastrointestinal infection due to cytomegalovirus occurs frequently in liver transplant recipients. Upper gastrointestinal cytomegalovirus infection is associated with subjective complaints of nausea, a sense of abdominal fullness, and occasionally emesis and/or dysphagia. In order to determine whether these symptoms reflect a disruption of the normal motility of the stomach, the following study was performed. Eleven individuals who were evaluated for liver transplantation were prospectively recruited and studied as follows: (1) upper gastrointestinal endoscopy with biopsy of the gastric antral mucosa; (2) viral culture of the gastric mucosa; (3) a histologic examination of the gastric mucosa; and (4) a radionuclide gastric emptying study was obtained before and 4-8 weeks following successful liver transplantation.

Prior to liver transplantation, none had symptoms of nausea, vomiting, or epigastric fullness. All were culture-negative for cytomegalovirus. All had endoscopic and histologic evidence of portal hypertensive gastropathy but none had antral erosions or ulcers. All demonstrated normal gastric emptying of a liquid meal.

Following liver transplantation, 6 remained free of gastric cytomegalovirus while 5 developed a culture-confirmed gastric cytomegalovirus infection. Those that developed a gastric cytomegalovirus infection also had more gastric symptoms, and more gastric histologic abnormalities. Moreover, those with a gastric cytomegalovirus infection demonstrated enhanced gastric retention of a liquid meal ($P < 0.01$).

These data demonstrate that gastric cytomegalovirus enteritis seen in liver transplant recipients may be associated with and increase in gastric symptoms, an increase in the frequency of histologic and endoscopic gastric antral abnormalities, and a significant reduction in gastric emptying.

Gastrointestinal infection due to cytomegalovirus is unusual in normal individuals but occurs often in immunosuppressed individuals, particularly organ transplant recipients (1-3). CMV infections of the esophagus, stomach, duodenum, colon, and liver have each been recognized and described (1-6).

Hepatic infection due to CMV is known to occur with fever and malaise, and can be associated with cardiovascular collapse (7, 8). Colonic infection can be the cause of diarrhea and cecal ulceration that can bleed profusely or perforate (4-6). In contrast, upper gastrointestinal CMV infection is associated with more subjective complaints including nausea, a sense of abdom-

inal fullness, and occasionally emesis and/or dysphagia (1-3). The present investigation was performed to determine whether an abnormality in gastric emptying accompanies the symptoms of nausea and abdominal fullness in patients who have received a liver transplant and who have been identified as having a gastric CMV infection.

MATERIALS AND METHODS

Subjects. Eleven individuals who were evaluated and scheduled to undergo orthotopic liver transplantation were prospectively enrolled at random by one of the investigators and studied both before and 4-8 weeks following their transplant procedure. Each subject had advanced, end-stage, parenchymal liver disease and was transplanted because of chronic hepatic failure. The clinical and immunologic characteristics of the 11 subjects studied in this investigation are shown in Table 1. All 11 were male; all had advanced parenchymal liver disease as their indication for liver transplantation. None complained of nausea, vomiting, or epigastric fullness prior to transplantation. None had overt hepatic encephalopathy at the time of study. Moreover, all had evidence of portal hypertensive gastropathy prior to transplantation but none had any antral erosions or ulcers. None had any histologic evidence of an acute superficial gastritis. Similarly, all were culture-negative for CMV using tissue obtained from their gastric antrum for the culture prior to liver transplantation. Finally, none was receiving or had been receiving any medication known or suggested to affect gastrointestinal motility.

Upper gastrointestinal endoscopy. Each subject underwent pan-upper gastrointestinal endoscopy prior to and 4-8 weeks following successful liver transplantation. Prior to each endoscopic study, the presence or absence of nausea, vomiting, and epigastric fullness was determined and was scored as present or absent. An Olympus 1-T endoscope was used in each case and four 4-mm biopsies were obtained from the gastric antrum of each subject for viral culture (n=2) and histopathology (n=2) at each endoscopy. This site was chosen for biopsy as it has been shown that the gastric antrum is the most frequently positive site for upper gastrointestinal CMV infection. The presence or absence of mucosal erythema, thickening, erosions, and ulcers was determined, and scored. Biopsies were obtained preferentially from areas recognized endoscopically as being abnormal.

Viral cultures. The tissue specimens for viral culture were homogenized immediately and cultured for CMV. The homogenates were cultured on human foreskin fibroblasts (F7000; Flow Laboratories, McLean, VA) and primary human embryonic kidney cells (M.A. Bio-products, Walkersville, MD), and were observed daily for 4 weeks for evidence of a cytopathic effect. Early antigen expression of infected cells was investigated at 18-24 hr.

Histopathology. Both biopsies submitted for histopathologic examination were fixed in 10% buffered formalin overnight, dehydrated and embedded in paraffin, sectioned at 5 μ , and mounted and stained with hematoxylin and eosin. All biopsies were read by attending pathologists at Presbyterian-University Hospital, who were unaware of this study but did know that the patients were either awaiting or had received an orthotopic liver transplant. The criteria utilized to evaluate the biopsies were those of Rotterdam and Sommers (9) (Table 2). The findings were scored as being present or absent.

The finding of typical CMV inclusions were required to make a histologic diagnosis of CMV enteritis.

¹ This work was reported in part at the Annual Meeting of the American Society of Transplant Physicians, May 1991, Chicago, IL.

² Address correspondence to: in part by a grant from NIDDK, AM32556.

³ David H. Van Thiel, M.D., 3601 Fifth Ave., Falk Clinic 5C, Pittsburgh, PA 15213.

⁴ Department of Medicine.

⁵ Department of Surgery.

CMV infection of the stomach was considered to be present if either the viral culture or histology was positive.

Gastric emptying of a liquid meal. Both before and 4–8 weeks after liver transplantation (33±4 days) and on the day following the upper gastrointestinal endoscopy procedure, gastric emptying of a radiolabeled liquid meal was studied. The test meal consisted of 250 ml of Gatorade containing 0.5 mCi of ^{99m}Tc-sulfur colloid (10). Gastric emptying of liquids was assessed, as it reflects true gastric emptying. Solids require grinding to an effective liquid prior to emptying. The subjects were studied sitting with the gamma camera positioned behind them, centered on the upper abdomen maximizing the efficiency of the counting procedure. Serial scans were obtained at 1-min intervals for 60 min. Scan data were stored in an on-line computer for subsequent analysis.

Data analysis. The recorded images were projected on a TV monitor and a region of interest was defined. This region was delineated to include the stomach and to allow for minimal patient motion but excluded adjacent small bowel. Each of the 60 1-min frames was individually reviewed and the counts in the region of interest were determined. The cpm for each frame within the region of interest were corrected for the presence of background activity and isotope decay. The data were then normalized and expressed as the fraction of isotope remaining in the stomach at any time (10). The cumulative area under the time-activity curve was determined at fixed 15-min intervals (11). This method of data analysis integrates both the rate of emptying and the residue volume throughout the duration of the study.

Immunologic factors. Prior to each endoscopic study, both before and after liver transplantation, each subject had a complete blood count with differential. The number of total lymphocytes in peripheral blood that were CD3⁺, CD4⁺, and CD8⁺ was determined by flow cytometry (12). With these data, the T helper/suppressor (H/S) ratio (CD4/CD8) for each subject was calculated.

Statistical analysis. All values are reported as means ± SEM. ANOVA and chi-square were used to determine the presence of a significant difference between groups (pre- and post-OLTx and CMV-positive vs. CMV-negative). The Fisher's exact test was used to confirm the results of ANOVA. A *P* value of <0.05 was considered to be significant.

RESULTS

Following transplantation, the 11 individuals recruited for participation in this study could be divided into two groups based upon the presence or absence of a CMV infection of the stomach occurring between 4 and 8 weeks postoperatively. Six remained CMV-free while five developed a gastric antral CMV infection, which in each case, was established by positive results on gastric biopsy and culture of the gastric antrum. Although those who developed gastrointestinal complaints were more

TABLE 1. Characteristics of the 11 men studied

Age (years)	41.7±2.2
Liver disease	
Cholestatic liver disease	5
Parenchymal liver disease	5
Viral liver disease (2)	
Alcoholic (1)	
Unknown etiology (1)	
Metabolic (Wilson's disease [1])	
Second biliary cirrhosis	1
Positive CMV serology prior to OLTx	9
Total lymphocytes ^a	1034±246
CD3 ⁺ cells ^a	764±184
CD4 ⁺ cells ^a	418±80
CD8 ⁺ cells ^a	286±103
Calculated H/S ratio	2.3±0.4

^a Cells per cubic millimeter in peripheral blood.

TABLE 2. Histologic definitions of gastritis/duodenitis

Chronic gastritis	Dense lymphocytic and plasma cell infiltrate expanding the lamina propria and separating adjacent gastric glands
Chronic active gastritis	Same as chronic gastritis, but with an additional acute inflammatory cell infiltrate (polymorphonuclear cells)
Chronic duodenitis	Excessive numbers of plasma cells and lymphocytes in the lamina propria
Chronic active duodenitis	As above for chronic gastritis and duodenitis but with a coexistent acute polymorphonuclear cell infiltrate

commonly found to have a pre-OLTx-positive serology and a gastric antral CMV infection, the data for nausea, vomiting, and a sense of epigastric fullness whether analyzed for each sign or symptom, individually or combined as a symptom complex, failed to reach a level of statistical significance (*P*=0.27). In contrast, when the histopathology of the stomach was assessed, those who were CMV-positive were found statistically more often to have an abnormal stomach (4 of 5) as compared with those who did not (1 of 6) (*P*<0.04).

The data relative to gastric emptying for the 11 individuals studied prior to liver transplantation are shown in Figure 1. These data are similar to those obtained for normal individuals studied in the same manner (data not shown) (10).

Consistent with the change in histopathology noted, individuals who were found to be CMV-positive after liver transplantation, had delayed or dismissed gastric emptying, with a resultant greater retained volume and area under the time-activity curve as compared with those who did not have a CMV infection (Figs. 2 and 3). No correlation between the severity of the subjective symptoms of nausea and abdominal fullness and the measured delay in gastric emptying was evident. The gastric emptying pattern following transplantation in those not found to be infected with CMV did not differ from that determined prior to transplantation.

The immunologic data for the two groups of subjects studied pre- and post-liver transplantation failed to distinguish between the two groups. The H/S ratio (CD4/CD8) declined in both groups posttransplantation, (CMV 2.4±0.3 pre-OLTx and 1.0±0.2 post-OLTx (*P*<0.01) and CMV⁺ 2.1±1.0 pre-OLTx and 1.3±0.4 post-OLTx) presumably as a consequence of the immunosuppression they were receiving.

DISCUSSION

These data clearly document, in a relatively small group of patients studied both before and after orthotopic liver transplantation, that the development of a CMV infection involving the stomach is associated with a trend toward an increased rate of upper abdominal symptoms and a statistically increased risk of having histologic gastritis and delayed gastric emptying of a liquid meal. The symptom complex that appears to be associated with CMV gastritis is similar to the symptoms experienced by individuals with gastric retention regardless of the specific etiology. The increased rate of gastric inflammatory disease in individuals with CMV gastritis was limited to a finding of acute

Residual Volume

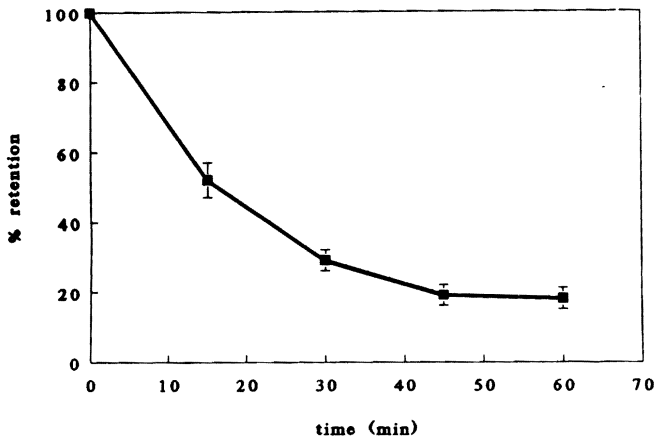


FIGURE 1. Gastric emptying of a liquid meal in the 11 subjects studied prior to liver transplantation. Residual volume as a function of time since ingestion of the test meal.

Area Under the Curve

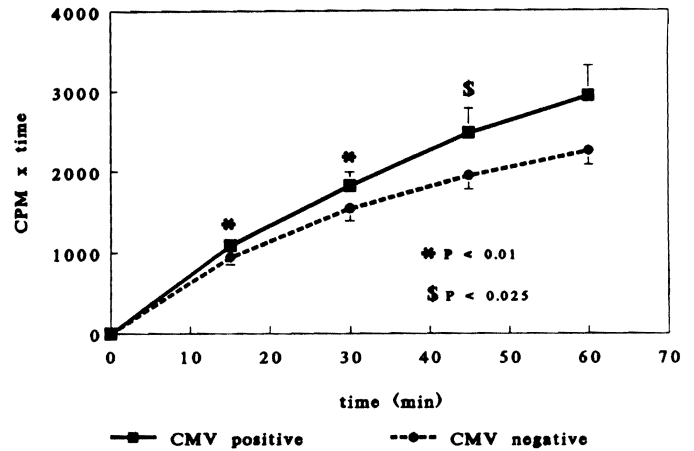


FIGURE 3. Gastric emptying of a liquid meal in 11 subjects studied 4-8 weeks after successful liver transplantation. The subjects are divided into 2 groups based upon the presence (n=5, solid line) or absence (n=6, broken line) of a documented CMV gastritis. The data are presented as the area under the time-activity curve at selected time points. The points represent mean values; the brackets represent the SEM.

Residual Volume

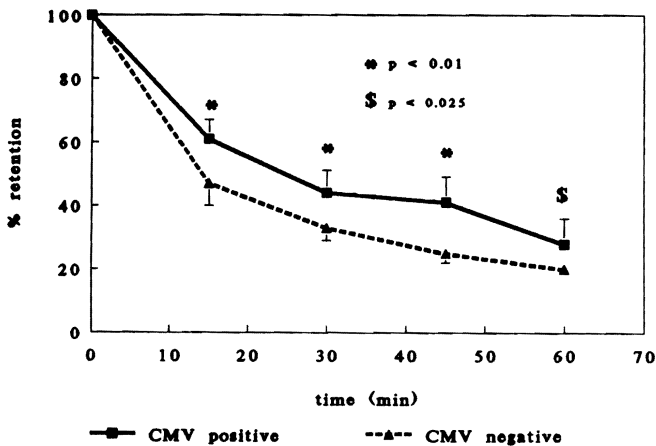


FIGURE 2. Gastric emptying of a liquid meal in the 11 patients studied 4-8 weeks following successful liver transplantation. The 11 subjects are divided into 2 groups based upon the presence (n=5, solid line) or absence (n=6, broken line) of a documented CMV infection of the stomach. All points are mean values. The brackets represent SEM. CMV gastritis was associated with enhanced gastric retention (reduced gastric emptying) of the ingested meal.

superficial gastritis and the presence of CMV inclusions in the gastric mucosa, which have been noted in earlier reports of similar types of patients (1, 2).

The principal finding of this study was that those who developed CMV gastritis having had normal gastric emptying prior to transplantation developed gastric stasis coincident with the presence of a gastric CMV infection and the presence of superficial acute gastritis following transplantation. This suggests rather strongly that the CMV infection, which developed as a consequence of the immunosuppression required to prevent graft rejection, produces clinical disease characterized by nausea, abdominal fullness, an acute superficial gastritis, and delayed gastric emptying of a liquid meal. Of interest was the fact

that although the immunosuppression used in all cases was nearly identical, only some individuals developed a CMV infection. Moreover, because the gastric emptying of those not found to have a CMV infection following transplantation did not differ from that obtained prior to transplantation, the data suggest quite strongly that the immunosuppressive agents used in these cases did not contribute to the alteration of gastric emptying observed in those with a CMV infection following transplantation. No particular difference was seen in the various lymphocyte subsets or the resultant T H/S ratio between those who did and did not develop CMV gastritis and a reduction in gastric emptying.

It is important to note further that this study was performed solely in men to avoid any confounding effects of the menstrual cycle upon gastric emptying (13). Moreover, the second evaluation in each case was delayed until at least 4 weeks, but was always performed before the eighth posttransplantation week, the period during which the majority of clinical infections with CMV are manifest in this unique population (14).

The symptoms reported by the patients with CMV gastritis are all consistent with those expected to occur in individuals with a motility disorder involving the stomach. They are also consistent with those one might expect in a CMV enteritis involving the proximal small bowel. Thus these symptoms can not be ascribed as occurring solely as a result of CMV gastritis but nonetheless are consistent with those expected in a CMV enteritis involving the stomach and duodenum. Nonetheless, it can not be assumed categorically that these findings are a result of CMV gastroenteritis per se. Liver transplantation involves extensive dissection in the area around the liver and this dissection may lead to severe injury that is directed toward the stomach. Moreover, prolonged operative time or trauma might also alter one's convalescence and transiently impair nutrition making these patients more susceptible to CMV infection. It is important to note, however, that among the various upper

gastrointestinal locations, the gastric antrum has been shown to be the most frequently involved site (14). It must also be pointed out that involvement of the myenteric plexus of the upper gastrointestinal tract has been reported, and that such involvement in the cases studied here would be expected to produce dysmotility (15). Finally, because viral culture and gastric histology were used to distinguish between CMV⁺ and CMV⁻ cases, rather than techniques such as in situ hybridization, it is possible that a positive result reflects a CMV viremia rather than a true enteritis. Regardless of the precise location of the CMV infection, be it blood, myenteric plexus, or mucosal cells of the stomach or duodenum, the cases that were positive developed a delay in gastric emptying of a test liquid that did not occur in those who were negative for CMV using the techniques utilized.

In summary, this study documents a possible increased prevalence of subjective symptoms and histologic evidence of acute superficial gastritis, as well as delayed gastric emptying of liquids, in individuals with culture-proved CMV gastritis.

REFERENCES

- Alexander JA, Brouillette DE, Chien MC, et al. Infectious esophagitis following liver and renal transplantation. *Dig Dis Sci* 1988; 33: 1121.
- Alexander JA, Cuellar RE, Fadden RJ, Genovese JJ, Gavaler JS, Van Thiel DH. CMV infection of the upper gastrointestinal tract before and after liver transplantation. *Transplantation* 1988; 46: 378.
- Campbell DA, Piercey JRA, Shritka TK, Goldsand G, Devin RDO, Weinstein WM. Cytomegalovirus associated gastric ulcer. *Gastroenterology* 1977; 72: 533.
- West JC, Armitage JO, Mitros FA, Klassen LW, Corry RJ, Ray T. Cytomegalovirus cecal erosion causing massive hemorrhage in a bone marrow transplant recipient. *World J Surg* 1982; 6: 251.
- Sutherland DER, Chan FY, Foucar E, Simmons RL, Howard RJ, Najarian JS. The bleeding cecal ulcer in transplant patients. *Surgery* 1979; 86: 386.
- Foucar E, Mukai K, Foukar K, Sutherland DER, Van Buren CT. Colon ulceration in lethal cytomegalovirus infection. *Am J Pathol* 1981; 76: 788.
- Bronsther O, Makowka L, Jaffe R, et al. The occurrence of cytomegalovirus hepatitis in liver transplant patients. *J Med Virol* 1988; 24: 423.
- Paya CV, Hermans PE, Wiesner RD, et al. Cytomegalovirus hepatitis in liver transplantation: perspective analysis of 93 consecutive orthotopic liver transplantations. *J Infect Dis* 1989; 160: 752.
- Rotterdam H, Sommers SC. *Stomach in biopsy diagnosis of the digestive tract*. New York: Raven Press, 1981: 45.
- Schade RR, Dugas MC, Lhotsky DM, Gavaler JS, Van Thiel DH. Effect of metaclopramide on gastric liquid emptying in patients with diabetic gastroparesis. *Dig Dis Sci* 1985; 30: 10.
- Dugas MC, Schade RR, Lhotsky D, Van Thiel DH. Comparison of methods for analyzing gastric isotopic emptying. *Am J Physiol* 1982; 243: G237.
- Chen K, Demetris AJ, Van Thiel DH, Whiteside TL. Methods in laboratory investigation: double immunoenzyme staining method for analysis of tissue and blood lymphocyte subsets with monoclonal antibodies. *Lab Invest* 1987; 56: 114.
- Van Thiel DH, Schade RR. Pregnancy: its physiologic course, nutrient cost, and effects on gastrointestinal function. In: Rustigi VK, JN Cooper, eds. *Gastrointestinal and hepatic complications in pregnancy*. New York: Wiley 1985: 1.
- Hassanein TI, Shetty B, Gavaler JS, et al. Upper gastrointestinal CMV infection pre- and postorthotopic liver transplantation. *Digestive Dis Sci* (in press).
- Sonsino E, Mouy R, Foucaud P, et al. Intestinal pseudoobstruction related to cytomegalovirus infection of myenteric plexus [Letter]. *N Engl J Med* 1984; 311: 196.

Received 7 August 1991.

Accepted 10 October 1991.