

Atlas of Surgical Oncology

Editors

John M. Daly, M.D.

Johnathan E. Rhoads Professor of Surgery
University of Pennsylvania School of Medicine
Chief, Division of Surgical Oncology
Hospital of the University of Pennsylvania
Philadelphia, Pennsylvania

Blake Cady, M.D.

Professor of Surgery
Harvard Medical School
Chief of Surgical Oncology
New England Deaconess Hospital
Boston, Massachusetts

Art Editor

David W. Low, M.D.

Assistant Professor of Surgery
Division of Plastic Surgery
University of Pennsylvania School of Medicine
Hospital of the University of Pennsylvania
Philadelphia, Pennsylvania

 **Mosby**

St Louis Baltimore Boston Chicago London Philadelphia Sydney Toronto

1993

*Right and Left Hepatic Trisegmentectomy**

*Shunzaburo Iwatsuki, M.D.
Thomas E. Starzl, M.D., Ph.D.*

Illustrated by Ronald Filer

Introduction and Anatomic Consideration

A large portion of the liver that lies to the right side of the falciform ligament was mistaken as the right lobe for a long time. However, Cantlie in 1898, and McIndoe and Counseller in 1927 reported that the division between the true right and left lobes of the liver was not at the falciform ligament, as had previously been believed, but at a line passing through the bed of the gallbladder and projecting posteriorly toward the vena cava (known as Cantlie's line).

Casting studies of the liver in the early 1950s demonstrated that each true lobe was further divided into two segments: (1) an anterior and posterior segment of the right lobe and (2) a medial and lateral segment of the left lobe. These observations were confirmed and extended by Couinaud and by Goldsmith and Woodburne in the late 1950s. Couinaud divided each of the four segments into two, resulting in a total of eight segments (subsegments).

The principle of trisegmentectomy is based on the four anatomic segments of Goldsmith and Woodburne but not on the eight segments (subsegments) of Couinaud. With right trisegmentectomy, the right lobe of the liver and the medial segment of the left lobe are removed, with the exception of the caudate lobe proper, which may be removed or retained, depending on the location of the tumor. With left trisegmentectomy, the left lobe of the liver and the anterior segment of the right lobe are removed, but the caudate lobe proper may be resected or retained.

"Extended" right or left lobectomy as we use the term means right or left trisegmentectomy. Unfortunately, the same designation is sometimes used in the literature to describe a slight modification of right or left lobectomy in which the medial segment of the left lobe or the anterior segment of the right lobe is partially removed. Extended lobectomy with the latter meaning is a nonanatomic resection, which does not differ from the lobectomy in preparation for actual hepatic transection.

FIG 28-1

There are five truly anatomical hepatic resections: right and left trisegmentectomy, right and left lobectomy, and left lateral segmentectomy.

Incision and Exposure

FIG 28-2

Various types of incision for hepatic surgery are shown.

A. The basic incision is a bilateral subcostal incision to which an upper midline extension is usually added. The right side of the subcostal incision (points A-B) usually is longer than the left side (points A-D). When the upper midline extension (A-C) includes complete removal of the xiphoid process, the exposure of the suprahepatic abdominal vena cava improves significantly. A thoracic extension (E-F) into the eighth intercostal space or a sternotomy (C-G) is rarely necessary even for very large tumors. In many cases a right subcostal incision with an upper midline extension (A-B plus A-C) gives adequate exposure.

B. When the costal angle is narrow, a J-shaped incision can be used.

C. In children a rather flat bilateral subcostal incision can be used without the midline extension. A self-holding retractor such as a Rochard retractor applied to the right and left costal margins is helpful in obtaining steady satisfactory exposure.

*Figures 28-1 and 28-2 from Starzl TE, Iwatsuki S: *Surg Gynecol Obstet* 1982; 155:21-27. Used by permission.

FIG 28-1

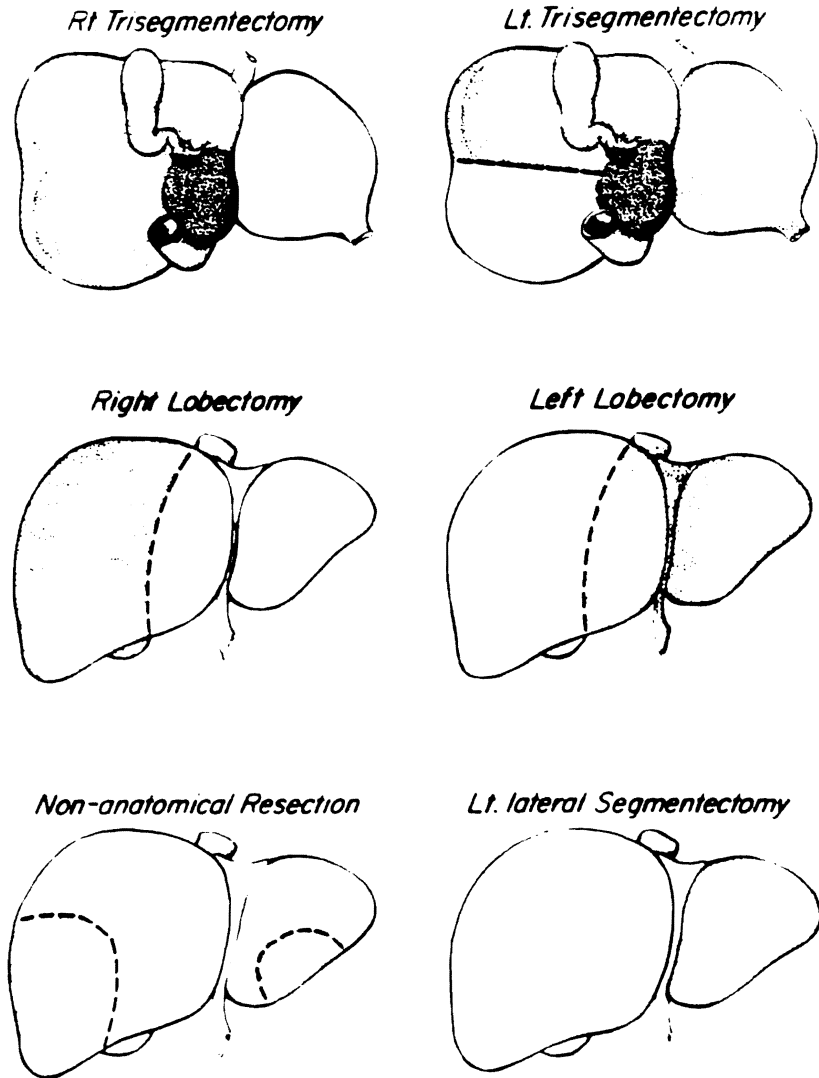
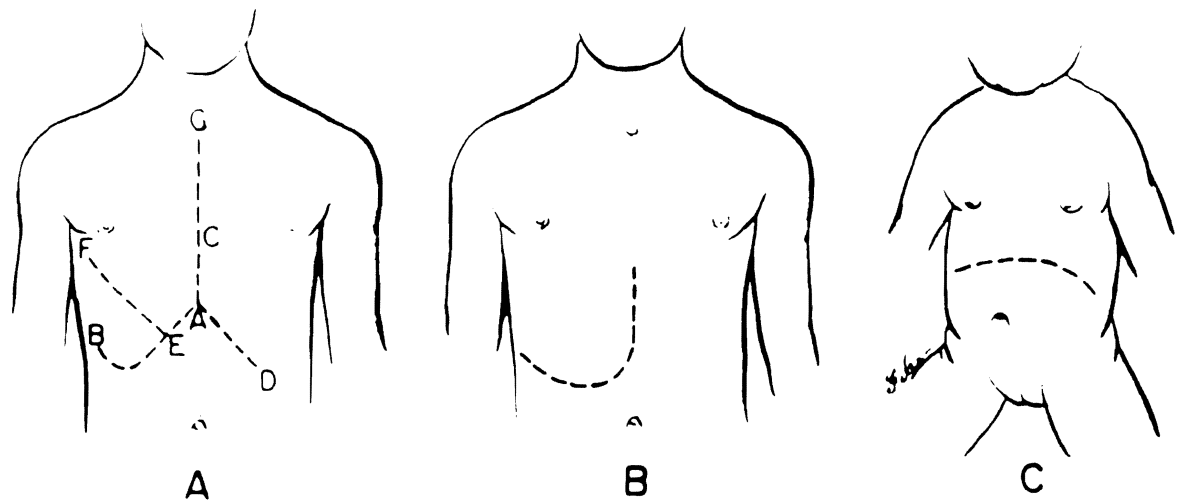


FIG 28-2



Identification of the Hepatic Artery

FIG 28-3

There are numerous variations of hepatic hilar structures, particularly the hepatic artery. In the past we thought that the dissection of the hilar structures would be so much facilitated by prior knowledge of the hepatic arterial blood supply that elective hepatic resection should never be performed without preoperative angiography. However, for the last 10 years or longer we have not used preoperative angiography for this purpose, because the intraoperative examination of the hilar structures by inspection and palpation is quite sufficient to identify all variations of the hepatic arterial blood supply. Moreover, computed tomography scan and magnetic resonance imaging have replaced angiography in the detection and localization of hepatic lesions.

The first step is to look for an anomalous artery in the left part of gastrohepatic ligament. A vessel here is usually a left segmental or lobar branch, which originates from the left gastric artery. The branch enters the liver at the base of the umbilical fissure (between the medial and lateral segment).

FIG 28-4

Further evaluation is with a left index finger inserted into the foramen of Winslow. If by bidigital palpation a pulse is felt to the left of the common duct anterior to the portal vein, it is almost certain that the artery comes from the celiac axis. A pulse felt posterior to the portal vein is a sure sign of an artery that has originated from the superior mesenteric artery. This anomalous vessel usually supplies part or all of the right lobe of the liver (see Fig 28-3), but it may also supply part of the left lobe or even the entire liver.

More distally, the best place to feel the left hepatic artery is the umbilical fissure at the base of the liver, and the best place for the right hepatic artery is the base of the gallbladder neck.

The lesion to be resected is very carefully evaluated. A final decision about the appropriate operation is made surprisingly often at the operating table rather than on the basis of the documentation obtained from preoperative imaging and other studies.

FIG 28-3

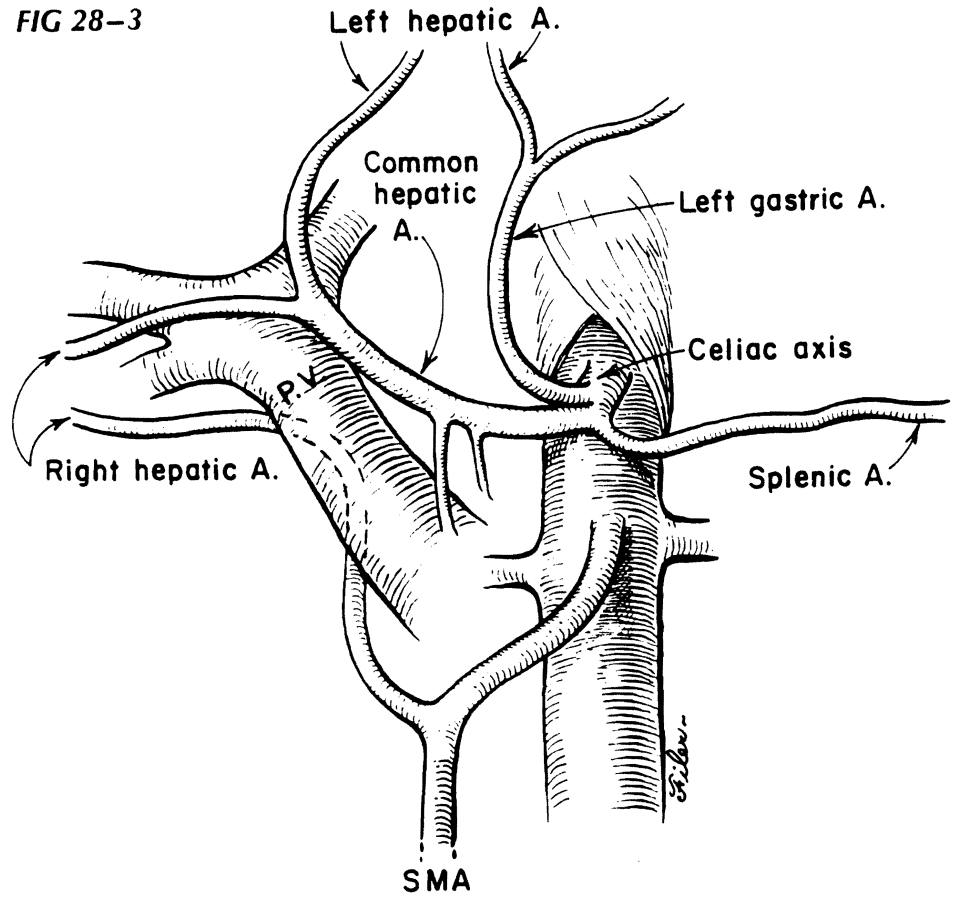
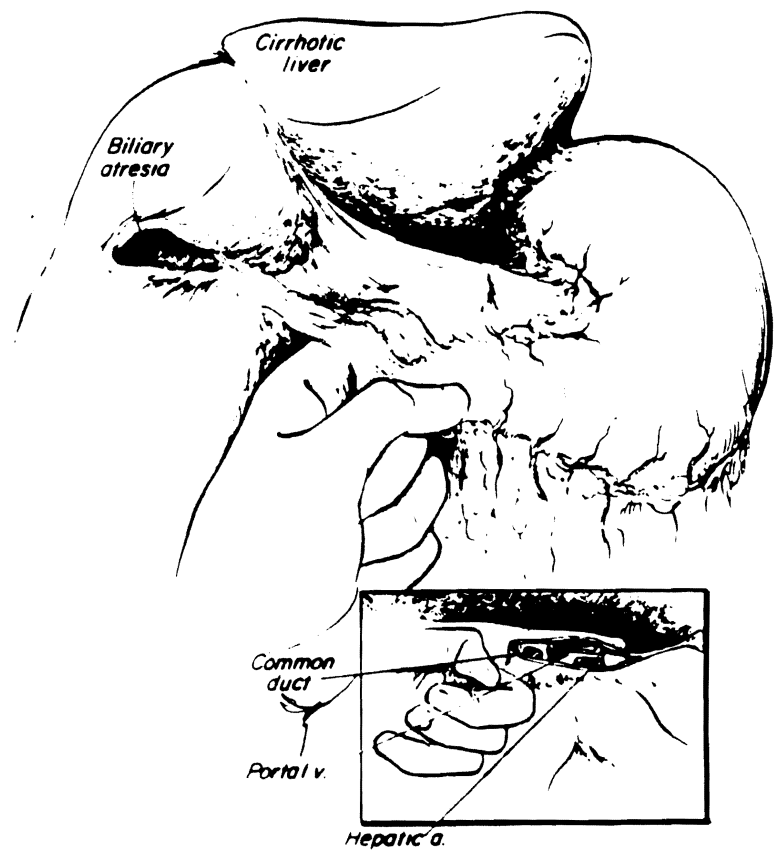


FIG 28-4



Right Trisegmentectomy

Preliminary Mobilization

The sequence of the operation may vary from case to case, depending on the location and size of the lesions. Usually preliminary mobilization of the right lobe of the liver is the initial step. The attachment of the ascending colon (hepatocolic ligament) and the prerenal peritoneum (renohepatic ligament) are separated from the inferior surface of the liver.

FIG 28-5

The right triangular and coronary ligaments are also incised at this time. When this is done, the right bare area can be broadly entered and the right lobe of the liver easily elevated into the wound and retracted toward the left. Early mobilization of the right lobe is an optional luxury, the feasibility of which depends on the location and size of the lesion. If the mobilization is difficult or the area where the right hepatic vein enters the vena cava cannot be readily exposed, the right hepatic vein should be approached from within the liver during the parenchymal transection (see later discussion).

FIG 28-6

Hilar Dissection

The initial step of hilar dissection for the right trisegmentectomy is exactly the same as that for the right lobectomy. The cystic duct and artery are freed, ligated, and divided. By doing so, the bifurcation and especially the right branches of the hilar structures can be identified more easily and safely. The cystic artery usually arises from the right hepatic artery. The right hepatic artery is dissected, doubly ligated, and divided. The hepatic artery variations are so numerous that the right hepatic artery should never be sacrificed without preliminary test occlusion and without being sure that during this test occlusion there are definite arterial pulsations going to the hepatic fragment that is to be retained.

After the right hepatic artery is divided and the peritoneum, lymphatics, and nerve tissue are cleared, the right branch of the portal vein is encircled. If it is long enough, it is ligated and divided. If it is short, it is divided between vascular clamps, and the proximal end is closed with continuous 6-0 Prolene suture.

If there is difficulty with exposure of the right portal branch, the portal vein can be easily approached laterally or posteriorly when the liver is retracted anteriorly and to the left (see Fig 28-5). This posterior approach is especially helpful if vein branches emanate from the back of the portal bifurcation, as is often seen. After the right hepatic artery and the right branch of the portal vein are divided, a line of demarcation becomes evident between the right and left lobe through the bed of the gallbladder and directed toward the vena cava. If the line of demarcation is not evident or is far to the right of the expected line, further search for missed hepatic artery or portal branches is necessary.

The common hepatic duct almost always has the most superior bifurcation among the three portal triad structures. It is so high, in fact, that the division may be within the substance of the liver. The right branch of the duct is near the base of the gallbladder bed, where it usually comes off like a crossbar from a T. In anomalous cases, the cystic duct can join the right hepatic duct, and this will have been discovered usually during the cystic duct dissection and ligation. The right hepatic duct is ligated and divided but only after a definite duct that passes into the retained left fragment of the liver has been demonstrated. At this point the hilar dissection of a standard right hepatic lobectomy has been completed. Additional hilar dissection is necessary for right trisegmentectomy.

FIG 28-5

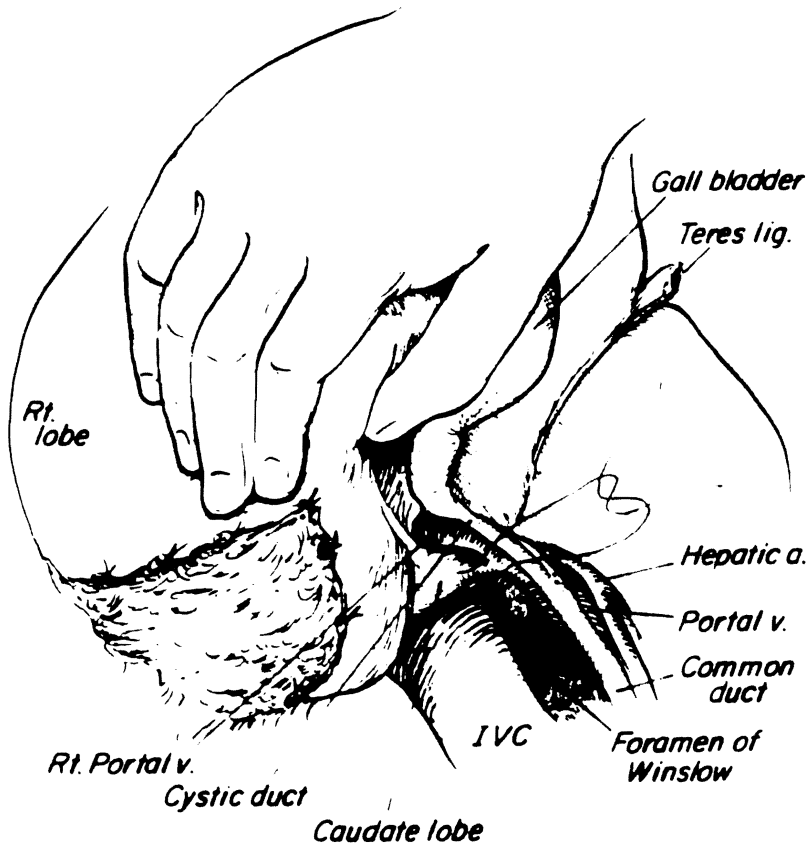


FIG 28-6

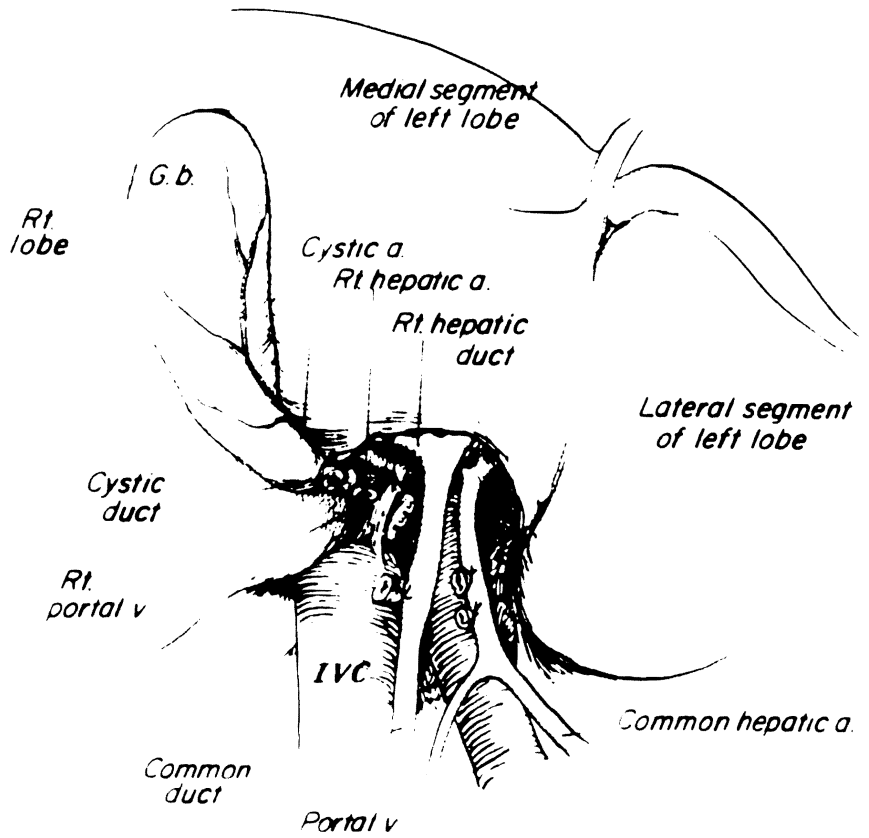


FIG 28-7

Before one proceeds further, the exact location of the umbilical fissure must be identified. In many cases the umbilical fissure is concealed by a fusion of lips between the medial and lateral segments of the left lobe. There is no large structure passing through the fusion, and it can be readily opened.

FIG 28-8

The true umbilical fissure lies in the base of the opened field. The transverse portion (*pars transversus*) of the left portal structures runs at the base of the quadrate lobe from its origin at the main portal bifurcation to the umbilical fissure. The left portal branch is several centimeters long and divides the medial segment of the liver into the quadrate and caudate components. As the left triad structures are mobilized from the base of the quadrate lobe, the first branches pass posteriorly to the left portion of the caudate lobe. If the decision is made to sacrifice these branches (see Fig 28-7), the caudate lobe will be devitalized, and ideally, it should be removed entirely from the wall of the vena cava and from its junction with the lateral segment. If these first posterior branches can be retained, the intrinsic risk of right trisegmentectomy is reduced by preserving a larger hepatic fragment. However, total extirpation of the caudate lobe is unavoidable in some cases if an adequate tumor-free margin is to be obtained.

Except for early branches to the caudate lobe, there are usually a few tiny branches from the triad structures in the course of the *pars transversus*. These must be carefully looked for, meticulously dissected, and ligated and divided. If there is a variant artery arising from the left gastric artery or from the celiac axis (see Fig 28-3) to the entire left lobe or to the left lateral segment, it almost always enters the base of the umbilical fissure, considerably to the left of the field of dissection of the *pars transversus*. This anomaly, if recognized early, is a technical advantage because its presence virtually eliminates the danger of dearterializing the remaining left lateral segment. If the structures of the left portal triad are buried in the hepatic parenchyma, which frequently is the case, the dissection of the *pars transversus* from right to left is stopped short of the umbilical fissure.

However, in some cases, the further division of the triad structures into the medial and lateral segmental branches can be seen easily. If this anatomic advantage is present, cautious dissection, ligation, and division of those branches feeding back to the medial segment can be done now, working from the base of the umbilical fissure. Any difficulty in dissection or ambiguity about what is being freed must prompt immediate discontinuation of such efforts. The safest technique will be to deal with the feedback structures to the medial segment at the time of parenchymal transection.

FIG 28-7

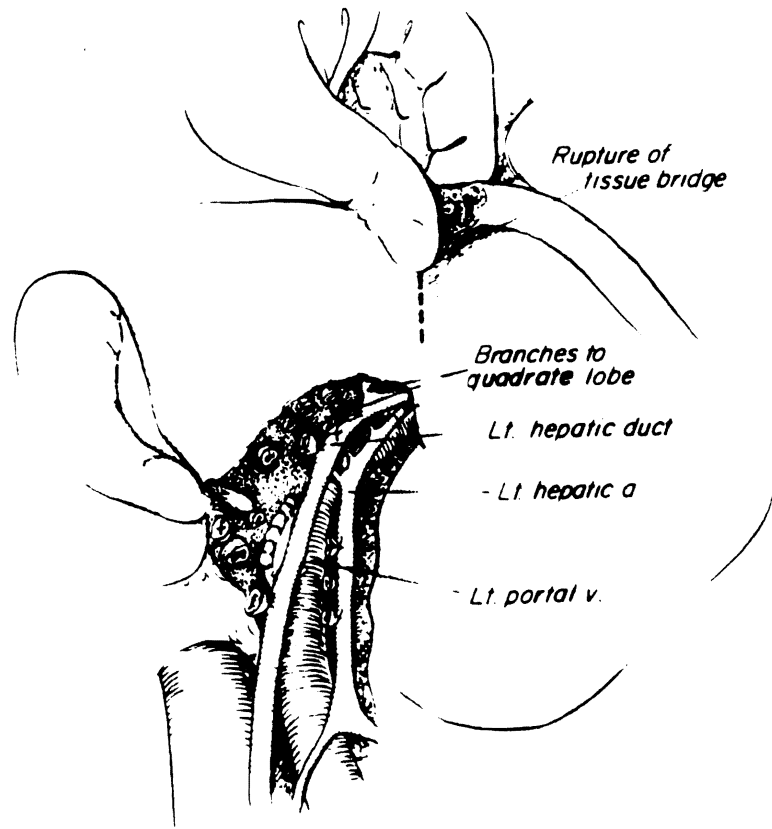
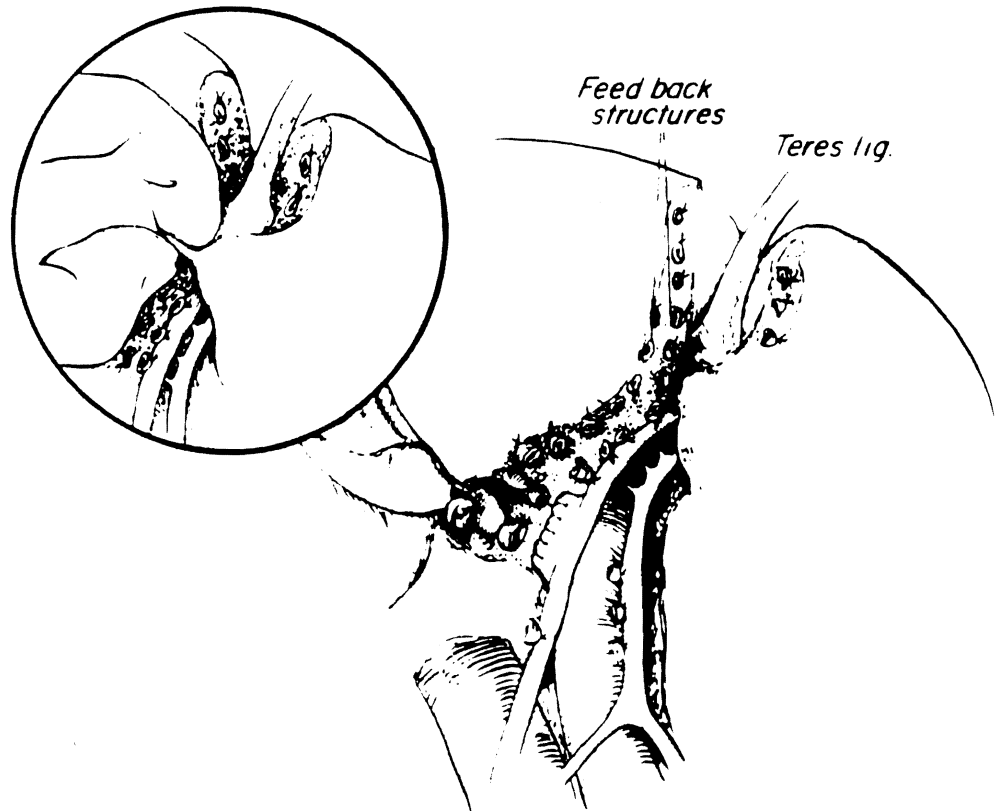


FIG 28-8



In most cases the right lobe of the liver has been freed from the attachments as described earlier.

FIG 28-9

The entire length of the retrohepatic vena cava is exposed by careful dissection while the right lobe is retracted anteriorly and to the left. The right adrenal vein should not be injured. The cavohepatic ligament or sometimes a lip of the right lobe covers the most superior part of the abdominal vena cava. This attachment is incised carefully to expose and encircle the right hepatic vein at its junction to the vena cava. Before the actual encirclement of the right hepatic vein, several small posterior hepatic veins that enter into the anterior surface of the vena cava are doubly ligated and divided, hereby exposing the anterior surface of the vena cava and the right hepatic vein, which is encircled, clamped, and divided.

FIG 28-10

Both ends of the vein are closed with 5-0 Prolene sutures.

When the entire caudate lobe is to be removed, the multiple small- and medium-sized hepatic veins that drain the caudate lobe proper are ligated and divided on the anterior left wall of the vena cava. With this radical step, the left hepatic vein is the sole source of venous drainage of the remaining left lateral segment.

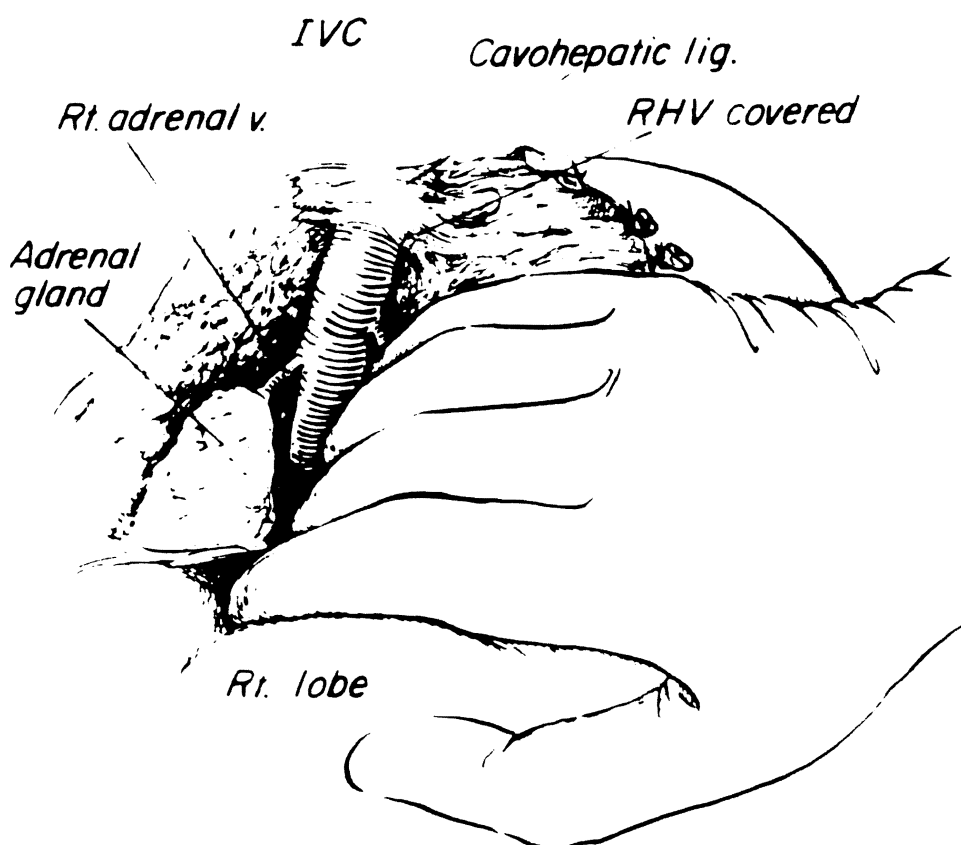


FIG 28-9

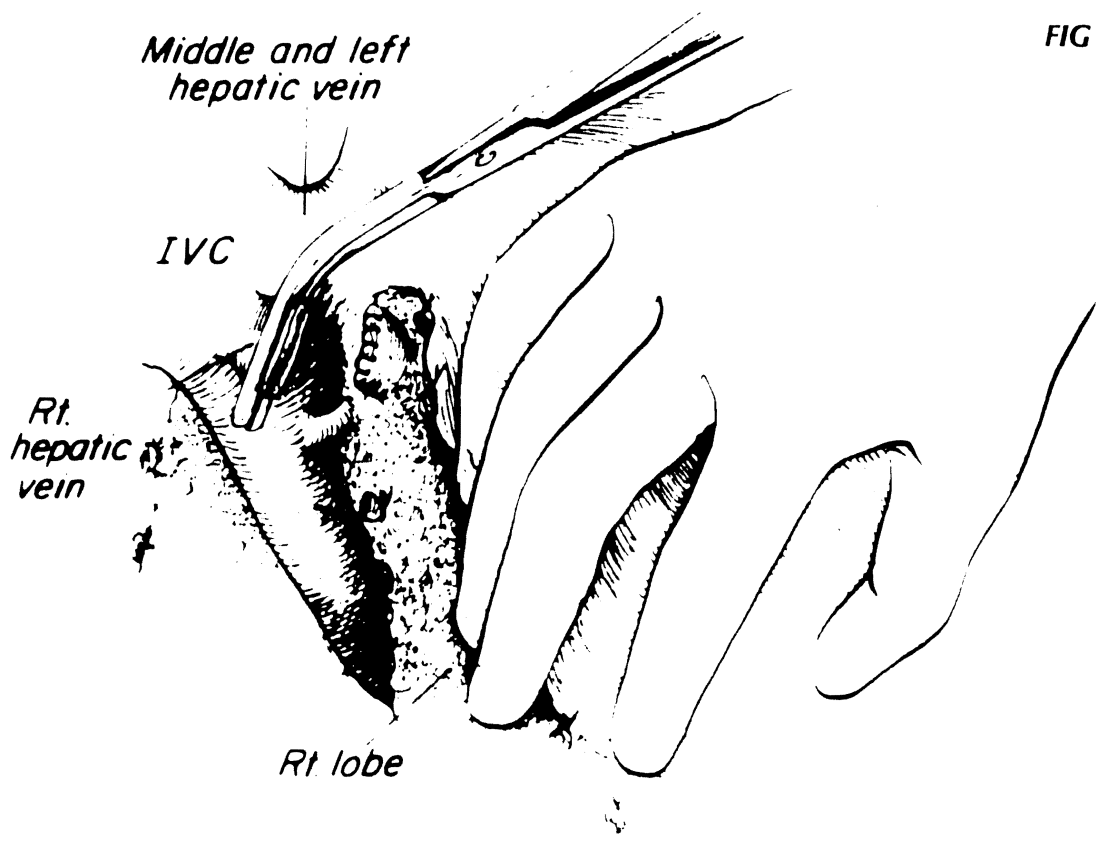


FIG 28-10

FIG 28-11

Parenchymal Transection

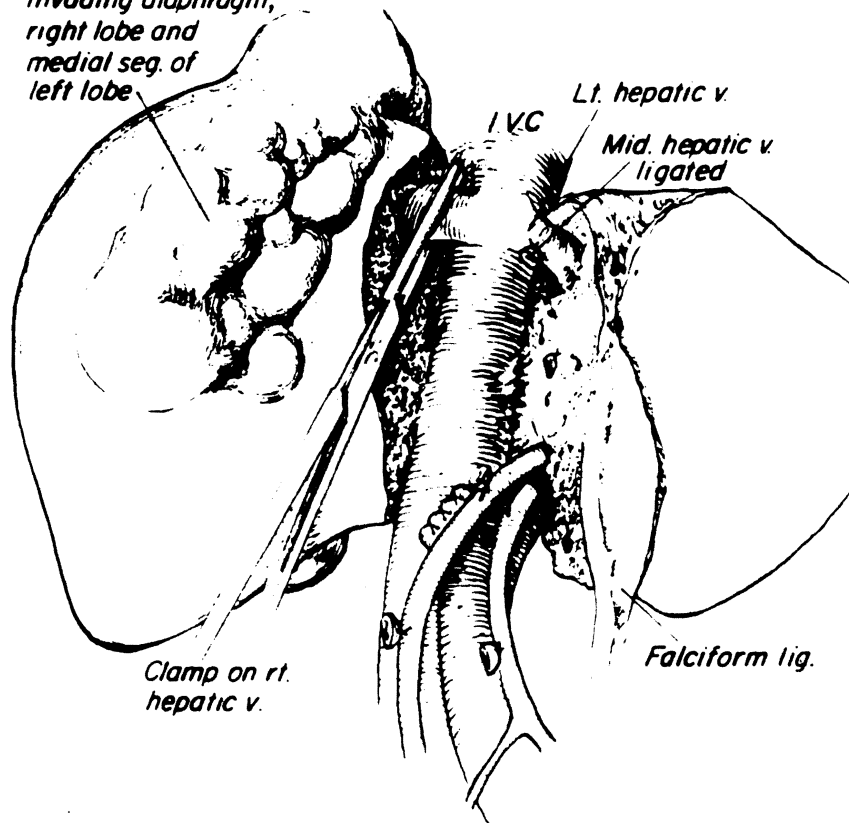
The transection line for right trisegmentectomy is the falciform ligament anteriorly, the umbilical fissure or the round ligament inferiorly, and the anterior surface of the vena cava posteriorly. This transection requires identification, ligation, and division of the feedback triad structures along the right side of the umbilical fissure, as well as the ligation and division of the middle hepatic vein at its junction to the left hepatic vein.

The complex of arterial, portal, and ductal feedback structures originates from the main left branches in the umbilical fissure and comes back into the medial segment. The feedback structures are ordinarily buried in the hepatic parenchyma, and only after they are occluded does the medial segment become cyanotic. As discussed earlier, they are not dissected in the umbilical fissure unless they can be seen clearly. Instead, the medial segmental artery, vein, and duct usually are approached within the substance of the liver, just to the right of the falciform and round ligaments. The parenchyma of the liver can be crushed down to them, either with clamps and ligature or with fingers (see Fig 28-8).

With all three segments devascularized, the liver is transected starting inferiorly and proceeding toward the diaphragm. The transection is facilitated by pushing down the right side of the liver with the left hand of the operator to open the cleavage plane. The middle hepatic vein that drains the medial segment and a part of the right lobe is identified during the transection and is ligated and divided or clamped and oversewed near the diaphragm. Either it enters separately into the vena cava or, more commonly, it joins the left hepatic vein to form a short common trunk. Injury to the left hepatic vein must be prevented by cautious identification of this variable anatomy. Occlusion or stricture of the left hepatic vein will lead to acute Budd-Chiari syndrome and uncontrollable hemorrhage from the cut surface of the liver.

When the right hepatic vein cannot be encircled earlier because of the bulky tumor nearby, its division is carried out from within the liver during the parenchymal transection, usually after the division of middle hepatic vein. This approach is often safer than the earlier encirclement of the right hepatic vein, particularly when the tumor is in close proximity.

*Large tumor
invading diaphragm,
right lobe and
medial seg. of
left lobe*



Lt. hepatic v.

IVC

*Mid. hepatic v.
ligated*

*Clamp on rt.
hepatic v.*

Falciform lig.

Left Trisegmentectomy

The mobilization of the left lobe is begun by division of the round ligament (ligamentum teres hepatis) and incision of the falciform ligament toward the suprahepatic part of the inferior vena cava. After division of the left triangular and coronary ligaments, the left lobe can be lifted anteriorly and retracted to the right. The small left bare area is entered so that the suprahepatic vena cava is exposed and the entrance of the left phrenic vein into the left hepatic vein is visualized.

Hilar Dissection

The hilar dissection is facilitated when the cystic artery and duct are ligated and divided at an earlier time. The left hepatic artery originates in almost all cases from either the common hepatic artery or the left gastric artery. If there is an anomalous artery from left gastric origin or directly from the aorta, it may supply the whole left lobe or only the lateral segment (see Fig 28-3).

FIG 28-12

With the mobilized left lateral segment retracted anteriorly and to the right, the principal left lobe branches of the portal triad structures can be approached safely from their posterolateral aspect. With this maneuver, the posteriorly located portal vein is turned so as to become the most exposed of the portal triad structures. It is dissected, encircled, and divided, followed by similar treatment of the left hepatic artery and left duct. The exact location of the ligations determines whether the caudate lobe process is to be removed because the first branches of the left triad structures go posteriorly to the left portion of the caudate lobe. If the caudate lobe process is to be retained, the ligatures ideally must be placed beyond these branches. When these steps are completed, the devascularized portion of the liver becomes cyanotic. If the main left triad structures have been ligated, the color demarcation is in the middle of the gallbladder bed (see Fig 28-13). So far the preparation is the same as for a standard left hepatic lobectomy.

The left hepatic vein is shorter than the right one whether it drains into the vena cava separately or forms the common trunk joining with the middle hepatic vein. It is often difficult to dissect free, clamp, and close with suture because of posterior tributaries that are easy to injure and difficult to control when this occurs. If the caudate lobe process is to be removed, several branches entering the left or anterior wall of the retrohepatic vena cava must be dissected, doubly ligated, and divided (insert). This opens up the view of the backside of the left hepatic vein. The left hepatic vein or a common trunk with the middle hepatic vein then can be dissected effectively with a combination of an anterior approach and a posterior approach using the obliterated ductus venosus (fissure of obliterated ductus venosus) as a guide. The left and middle hepatic veins (or their common trunk) are now encircled, cross-clamped, incised, and closed with sutures at the vena caval entrance. The area of encirclement of the left and middle hepatic veins is used to begin the parenchymal transection of the left trisegmentectomy.

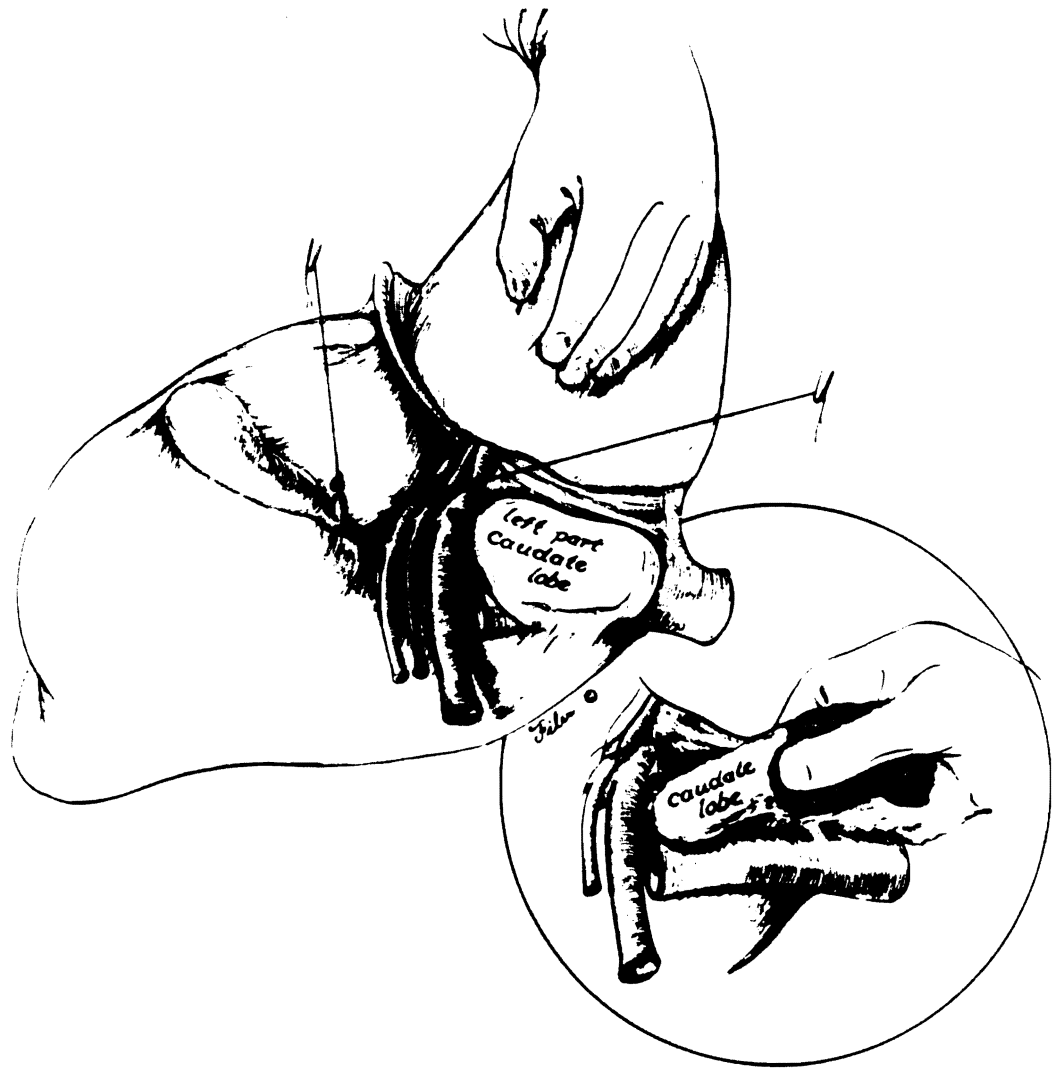


FIG 28–13

Parenchymal Transection

The transection starts just in front of the vena cava along the fissure of the obliterated ductus venosus when the caudate lobe process is to be spared or posterior to the caudate lobe when this structure is to be removed. The left and middle hepatic vein already will have been clamped and suture closed. The left side of the liver is lifted anteriorly and retracted to the right. An intersegmental plane is found between the anterior segment and posterior segments of the right lobe. Because both of these segments still have an intact blood supply, it is advisable to use the Pringle maneuver (temporary clamping of the portal triad structures) during this part of the procedure. The Pringle maneuver not only reduces the blood loss but also facilitates the identification of arterial, portal venous, and biliary branches that are to be preserved.

FIG 28–14

The intersegmental transection plane usually is best located near the diaphragm by sweeping the intraparenchymal finger just in front of the right hepatic vein. Downward traction of the liver being removed is continued, and a resistance-free plane is sought. All strands encountered are clamped or tied.

FIG 28-13

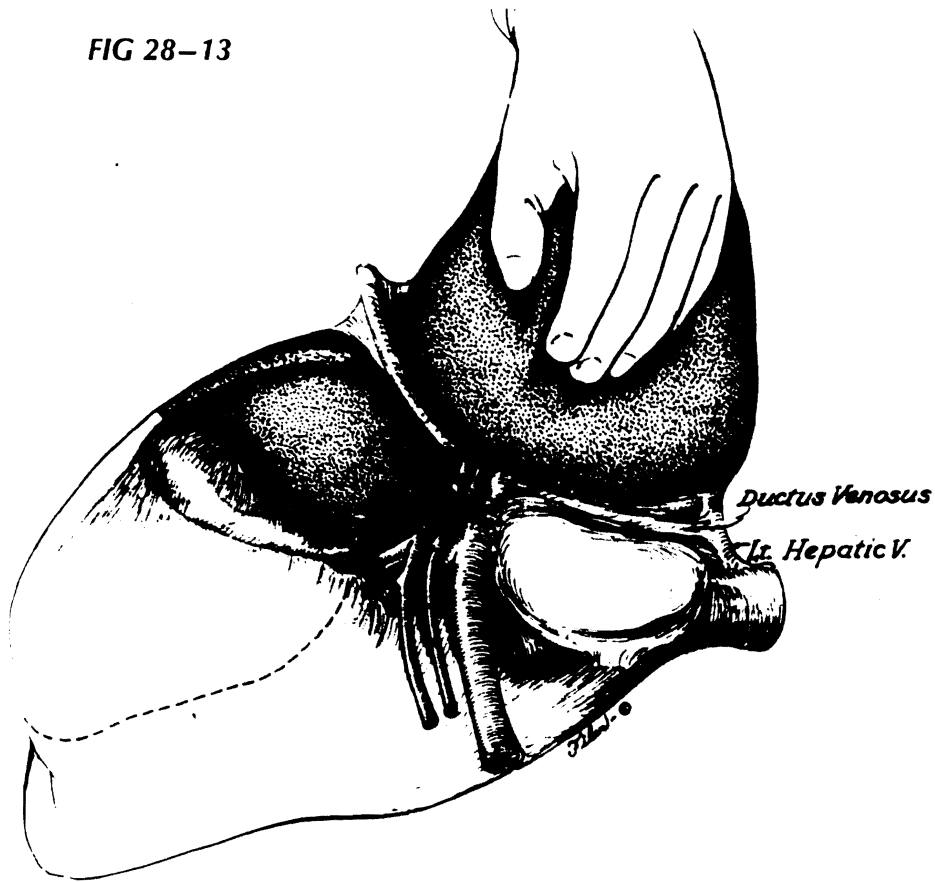


FIG 28-14

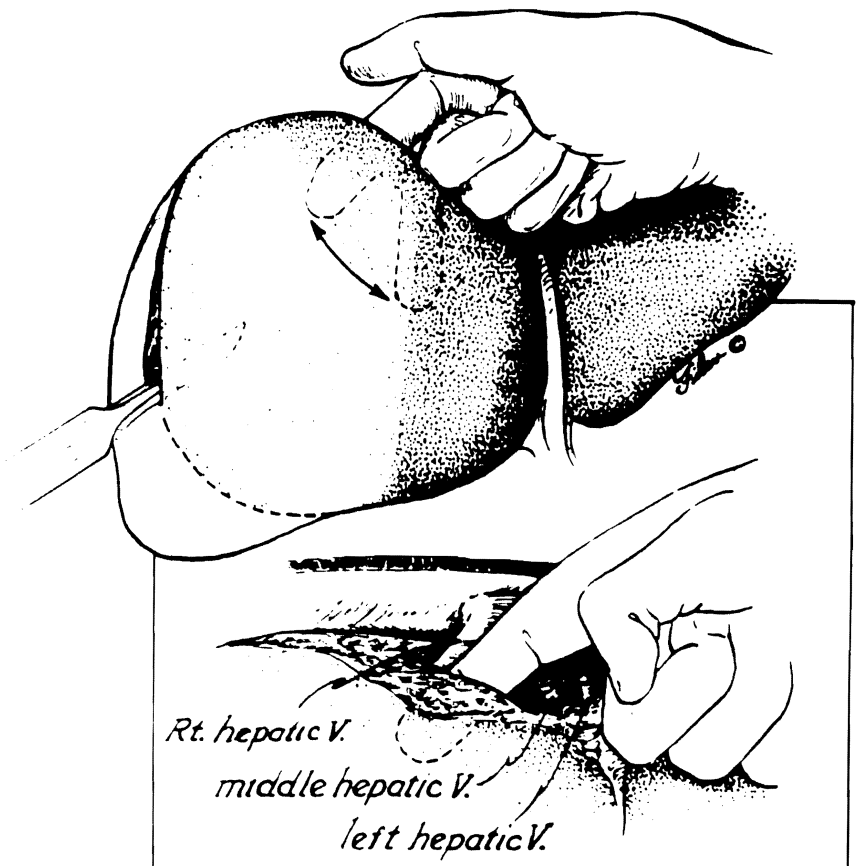


FIG 28-15

Inferiorly the dissecting finger should emerge near the base of and at a right angle to the gallbladder bed. Near the end of transection, anterior segmental branches of the right portal triad structures are encountered near the hilum still inside the substance of liver. These are individually ligated.

In the minority of livers, anterior segmental branches of the right portal triad structures can be dissected out near the porta hepatis. A temporary clamping of the anterior segmental artery and portal vein delineates the transection plane by the development of cyanosis of the anterior segment of the right lobe.

FIG 28-16

Under these circumstances, the transection for the left trisegmentectomy can be conducted from the hilum toward the diaphragm.

FIG 28-15

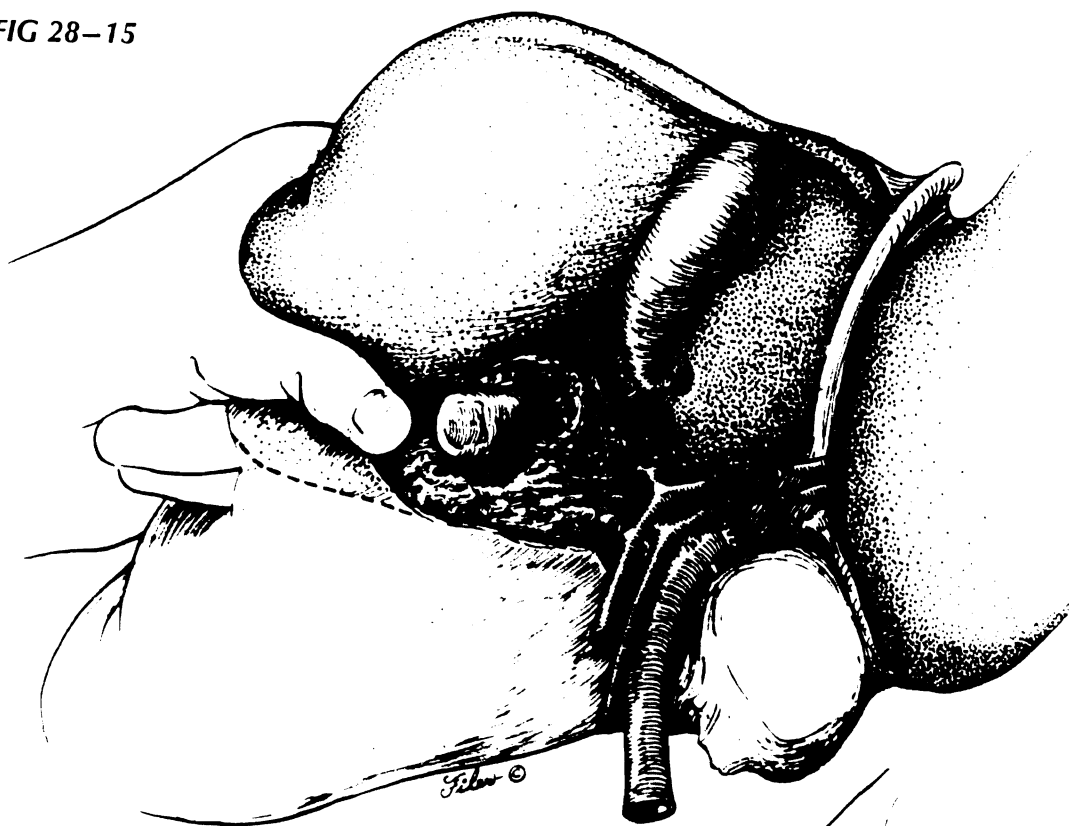
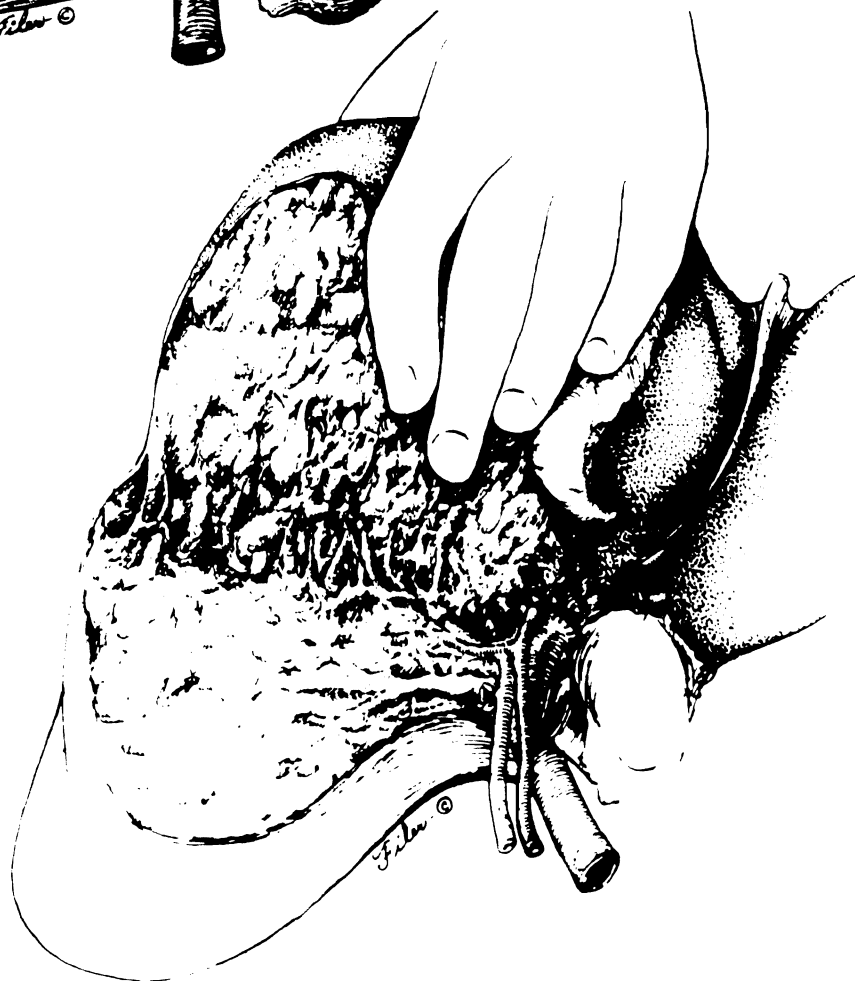


FIG 28-16



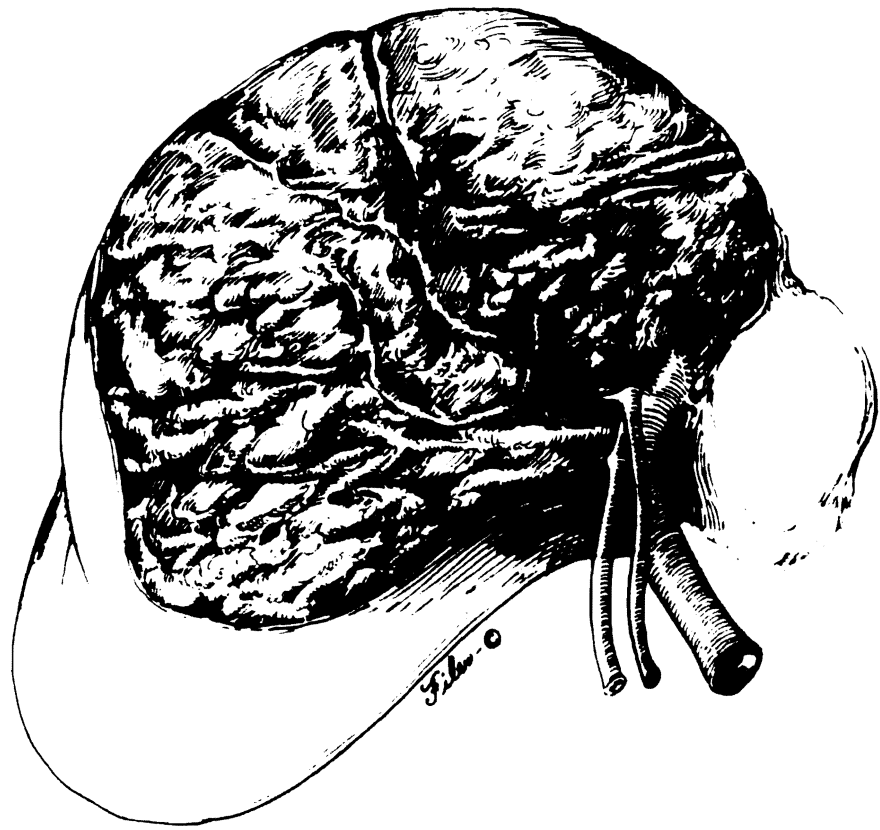
Complete hemostasis is the key in preventing postoperative mortality and morbidity after any type of hepatic resection. Because the transection plane is exactly between the fully vascularized segment and the devitalized segment, the remaining cut surface is pink and well vascularized. The bleeders and bile leaks can be easily identified and suture ligated.

FIG 28-17

The cut surface after the right trisegmentectomy is small and usually remarkably dry. On the other hand, the cut surface after the left trisegmentectomy is broad and presents an unfamiliar sight for most surgeons. After discontinuation of Pringle maneuver, precise visualization of the residual bleeding from this broad surface is still possible. Meticulous hemostasis maneuvers lasting 1 hour or more may be necessary. No effort is made to cover the cut surface with living tissue or prosthetic materials. For capillary bleeders, the argon beam coagulator is helpful in making the cut surface bone dry. The use of large sutures to close the cut surface is avoided because this may obstruct the remaining major vascular and biliary structures.

Unrecognized bile duct injury is a major cause of postoperative mortality and morbidity after hepatic resection. It is wise to obtain intraoperative cholangiography after major hepatic resection. This precautionary step not only confirms the integrity of the duct system but also identifies sites of small biliary leakage. Small leaking points are closed with fine sutures at the same time that small amounts of saline solution or diluted methylene blue solution are injected into the duct. With left trisegmentectomy, the extent to which the remaining ducts are exposed is so much greater than with other kinds of anatomic resections that the risks of bile fistula and duct injury or positional distortion are increased. For this reason, it is advisable to stent the duct and drain it with a long limb of a T tube.

With either right or left trisegmentectomy, one or two Jackson-Pratt closed suction drains are placed near the cut surface in the subphrenic place before closure to prevent bile accumulation or the formation of subphrenic abscesses.



Closing Remarks

This superb chapter by surgeons who have developed and promoted the whole field of extensive hepatic resection and hepatic transplantation has many important lessons for surgeons who do liver surgery. Because the criteria for resection of extensive portions of the liver are quite narrow, the procedures described will be relatively uncommon, especially caudate lobe excision and left trisegmentectomy. The right hepatic trisegmental resection will be performed more frequently at least in part because lesions of the right anterior segment that abut on the medial segment of the left lobe of the liver lend themselves to a trisegmental resection relatively more frequently than large lesions in the left lobe that abut the anterior segment of the right lobe but are still resectable. However, the basic principles of extensive hepatic resections carefully elaborated here are very important. With increasing sophistication of follow-up, sometimes by carcinoembryonic antigen (CEA) screening, and the realization that curative resections are possible, the number of patients who are seen with metastatic liver disease from colorectal cancer with very large metastases will decrease, and the number of patients with smaller metastases will increase. Patients with hepatocellular carcinoma who are noncirrhotic certainly will be a small group of patients suitable for extensive resections, but the majority of patients with hepatocellular carcinoma that arises in the background of cirrhosis do not lend themselves to any major resections. Interestingly, there is no relationship between size and prognosis after resection with metastatic cancer in the liver, so even large solitary cancers can be resected. The whole field of major hepatic resection is expanding rapidly and developing almost year by year, and such extensive procedures certainly should be in the province of every surgical oncologist.

Now that liver transplantation has been found to be a reasonable therapeutic option in young people with hepatocellular carcinoma confined to the liver or in cirrhotic patients who have a relatively small hepatocellular carcinoma, transplantation will be used more frequently than extensive hepatic resection because the long-term results may well be superior.

The major technical criterion for successful resection of metastases in the liver from colorectal carcinoma is a minimum 1-cm surgical margin. We have found in a recent analysis, however, that all of our patients who had more than 1,000 g of hepatic tissue resected, usually by a trisegmentectomy for metastatic colorectal carcinoma, had recurrence. Thus, in the future, smaller rather than larger resections may be preferred for treatment of metastases, with cryotherapy used more extensively, especially with the realization that repeat resections are possible in about 10% to 20% of patients.

Postoperative care has become more simplified as more experience has been achieved with liver resections. Seldom should one drain the common bile duct after any hepatic resection, and only if doubts exist regarding the patency or injury of the ducts is it necessary to do postresection cholangiography or duct drainage. Indeed, a recent controlled trial from France has indicated that even postoperative drainage of the resection margin is not necessary. I personally do not do routine external drainage any more, and only in a few selected cases will I use short-term drains.

This chapter is an excellent contribution to safe hepatic surgery of major extent.
—The Editors