

- specific nonreactivity 27 to 29 years after kidney allotransplantation. *Transplantation* 1993; 55: 1272.
34. Hall BM. Cells mediating allograft rejection. *Transplantation* 1991; 51: 1141.
35. Qin S, Cobbold SP, Pope H, et al. Infectious transplantation tolerance. *Science* 1993; 259: 974.
36. MacLean JA, Su Z, Colvin RB, Wong JT. Anti-CD3:anti-IL-2 receptor-bispecific mAb-mediated immunomodulation. Low systemic toxicity, differential effect on lymphoid tissue, and inhibition of cell-mediated hypersensitivity. *J Immunol* 1995; 155: 3674.
37. Chavin KD, Qin L, Lin J, Kaplan AJ, Bromberg JS. Anti-CD2 and anti-CD3 monoclonal antibodies synergize to prolong allograft survival with decreased side effects. *Transplantation* 1993; 55: 901.
38. Mandel TE, Koulmanda M. Effect of immunosuppression with anti-T-cell monoclonal antibodies on the survival of organ-cultured fetal pig pancreas xenografts in nonobese diabetic mice. *Transplant Proc* 1993; 25: 2926.
39. Mottram PL, Han WR, Purcell LJ, McKenzie IF, Hancock WW. Increased expression of IL-4 and IL-10 and decreased expression of IL-2 and interferon-gamma in long-surviving mouse heart allografts after brief CD4-monoclonal antibody therapy. *Transplantation* 1995; 59: 559.

Received 22 November 1996.

Accepted 3 June 1997.

0041-1337/97/6405-690\$03.00/0
 TRANSPLANTATION
 Copyright © 1997 by Williams & Wilkins

1987
 Vol. 64, 690-695, No. 5, September 15, 1997
 Printed in U.S.A.

ABROGATION OF CHRONIC REJECTION IN A MURINE MODEL OF AORTIC ALLOTRANSPLANTATION BY PRIOR INDUCTION OF DONOR-SPECIFIC TOLERANCE¹

VLADIMIR SUBBOTIN,² HONG SUN,² ABDELOUAHAB AITOUCHE,² LUIS A. VALDIVIA,² JOHN J. FUNG,² THOMAS E. STARZL,² AND ABDUL S. RAO^{2,3,4}

Thomas E. Starzl Transplantation Institute and the Departments of Surgery and Pathology, University of Pittsburgh Medical Center, Pittsburgh, Pennsylvania 15261

Aortic allotransplantation in mice has been well established as a model of choice to study the evolution of chronic rejection, the etiopathology of which is believed to be that of immune origin. This has prompted the postulation that prior induction of donor-specific tolerance would attenuate or abrogate the underlying events that culminate in posttransplant arteriosclerosis. To study the effects of donor-specific tolerance on chronic rejection, we performed orthotopic liver transplantation without immunosuppression in mice 30 days before aortic allotransplantation across C57BL/10J (H2^b)→C3H (H2^k) strain combinations (group III). Aortic allografting in syngeneic (group I; C3H→C3H) and allogeneic (group II, C57BL/10J→C3H) animals served as controls. No morphological changes were evidenced in the transplanted aortas in group I animals. Contrarily, aortic allografts in group II animals underwent a self-limiting acute cellular rejection, which resolved completely and was succeeded by day 30 after transplantation by histopathological changes pathognomonic of chronic rejection. There was evidence for diffuse myointimal thickening, progressive

concentric luminal narrowing, and patchy destruction of internal elastic membranes resulting in massive vascular obliteration by day 120 after transplantation. It was of interest that no arteriosclerotic changes were observed for the duration of follow-up (up to 120 days after transplantation) in transplanted aortas (liver donor-type) harvested from animals in group III. However, vasculopathy was prominent in third-party aortic grafts transplanted into tolerant recipients. Taken together, these data suggest that prior induction of tolerance abrogates the development of chronic rejection; this protection seems to be donor specific.

The most common cause for late organ allograft failure is chronic rejection (CR*); its incidence in organs surviving more than 5 years is up to 43%, 50%, and 60% for transplanted kidneys (1), lungs (2), and hearts (3), respectively. Conversely, its prevalence is much lower (3.6–16.8%) in long-surviving liver allografts (4). Although the factors underlying the changes pathognomonic of posttransplant obliterative vasculopathy are poorly understood, they nevertheless seem to be multifactorial (5–7). In addition to ischemia-reperfusion, allogeneic immune responses have been postulated to play a role in the pathophysiology of delayed graft failure (8–10).

¹ This work was aided by project grant DK 29961 from the National Institutes of Health, Bethesda, MD.

² Thomas E. Starzl Transplantation Institute and the Department of Surgery, University of Pittsburgh Medical Center.

³ Thomas E. Starzl Transplantation Institute and the Department of Pathology, University of Pittsburgh Medical Center.

⁴ Address correspondence to: Abdul S. Rao, MD, Thomas E. Starzl Transplantation Institute, E1545 Biomedical Science Tower, 200 Lothrop Street, Pittsburgh, PA 15261.

* Abbreviations: ACR, acute cellular rejection; AO, aorta; AOTx, aortic transplantation; CR, chronic rejection; DST, donor-specific tolerance; Ig, immunoglobulin; OB, obliterative bronchiolitis; OLTx, orthotopic liver transplantation; Tx, transplantation; α -sma, α -smooth muscle actin.

Of greater significance is the observation that once established, histopathological changes characteristic of CR are irreversible and somewhat refractory to exogenous intervention. This has necessitated the development of therapeutic strategies for its attenuation or abrogation. Given its immune etiopathology, it has been argued that prior induction of donor-specific tolerance (DST) in organ transplant recipients may mitigate the evolution of CR. This postulation has been verified experimentally in rats (11–15) and in a mouse model of cardiac allotransplantation (16). Similar observations have also been made in long-surviving human lung (17, 18) and renal (19) allograft recipients.

Given the availability of cellular and molecular probes in mice, we have elected to develop further a murine model of posttransplant arteriosclerosis. In this study, we report the progressive evolution of CR in a mouse model of aortic allotransplantation (20, 21). Immune modulation and its effect on the development of vasculopathy was examined by prior orthotopic liver transplantation (OLT_x), a procedure invariably associated with spontaneous allograft acceptance, establishment of microchimerism, and the induction of DST (22).

MATERIALS AND METHODS

Animals

Inbred male mice of the C57Bl/10J (B10; H2^b), BALB/cByJ (H2^d), and C3H (H2^k) strains were purchased from Jackson Laboratory (Bar Harbor, ME) and housed in a pathogen-free facility, provided with Purina rodent chow and tap water ad libitum, and used at 10–12 weeks of age.

Surgical Procedures

Operative procedures were executed under inhalation anesthesia (Metofane; Methoxyflurane, Pitman-Moore, Inc., Mundelein, IL) using a dissection microscope (M-32, Leica, Switzerland).

Aortic transplantation (AOT_x) was performed by a method described previously (20). A segment (0.6 cm) of donor thoracic aorta (AO) was anastomosed (end-to-side) to the infrarenal portion of the recipient abdominal AO. The section of the recipient AO between the anastomotic sites was ligated and severed, converting the anastomosis into a quasi end-to-end.

Using a combination suture and cuff technique, the liver was orthotopically transplanted using a method described elsewhere (22, 23). The hepatic artery was not reconstructed, and cholecystectomy was performed with bile duct patency assured using a polyethylene tube stent.

Experimental Groups

The recipients of AOT_x were divided into three groups (n=5/group; Fig. 1): group I (syngeneic), C3H→C3H without prior OLT_x; group II (allogeneic), B10→C3H without prior OLT_x; and group III, OLT_x across B10→C3H strain combination, followed 30 days later by AOT_x from either B10 (liver donor-strain) or BALB/cByJ (third party). The experiments in each group were repeated 2–3 times to corroborate these findings. The recipients were not immunosuppressed.

Tissue Procurement and Processing

At a predetermined interval after AOT_x (day 0, 6, 10, 20, 30, or >50 after Tx) and under inhalation anesthesia, the abdominal cavity was exposed. The entire segment of the grafted AO was harvested, fixed for 2–3 days in 10% neutral buffered formalin (VWR, Cleveland, OH), and processed for embedment into paraffin (Sherwood Medical, St. Louis, MO). For histopathological analysis, sections (4

Group I: (Syngeneic)



Group II: (Allogeneic)



Group III: (Prior OLT_x)

Allogeneic



Third Party control

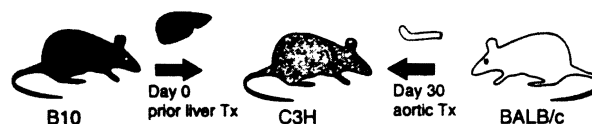

FIGURE 1. Schematic representation of various experimental groups used in this study. B10: C57Bl/10J.

μm thick) were obtained, mounted onto precleaned slides, and stained with hematoxylin and eosin (Surgipath, Richmond, IL). For detection of elastic fibers and collagen, Verhoeff-van-Gieson's and Mason's trichrome staining, respectively, were performed (25).

Immunohistochemical Staining

For detection of α -smooth muscle actin (α -sma) mouse anti-human monoclonal antibody (immunoglobulin [Ig]G_{2a}; DAKO Corp., Carpinteria, CA) was used (26, 27). Given the highly conserved sequence of its target antigen, this antibody has been shown to cross-react with α -sma from various species. The primary antibody was identified by biotinylated horse anti-mouse IgG (Vector Laboratories Inc., Burlingame, CA). For visualization of secondary antibody, the ABC (VECTASTIN; Vector Laboratories) immunoperoxidase system was used with coloration being developed using chromogen 3-amino-9-ethyl-carbazol (ScyTek Laboratories Inc., Logan, UT). Sections were counterstained with hematoxylin for light microscopy.

RESULTS

Graft Outcome

For the establishment of this technique and subsequently for the completion of this study, we have performed over 300 aortic transplants (allogeneic, n=275; syngeneic, n=25) using the quasi end-to-end procedure (20). With the exception of initial failures, which were largely a result of technical problems, the survival has been >98% (reproducible), thrombosis being the most frequent cause of graft loss.

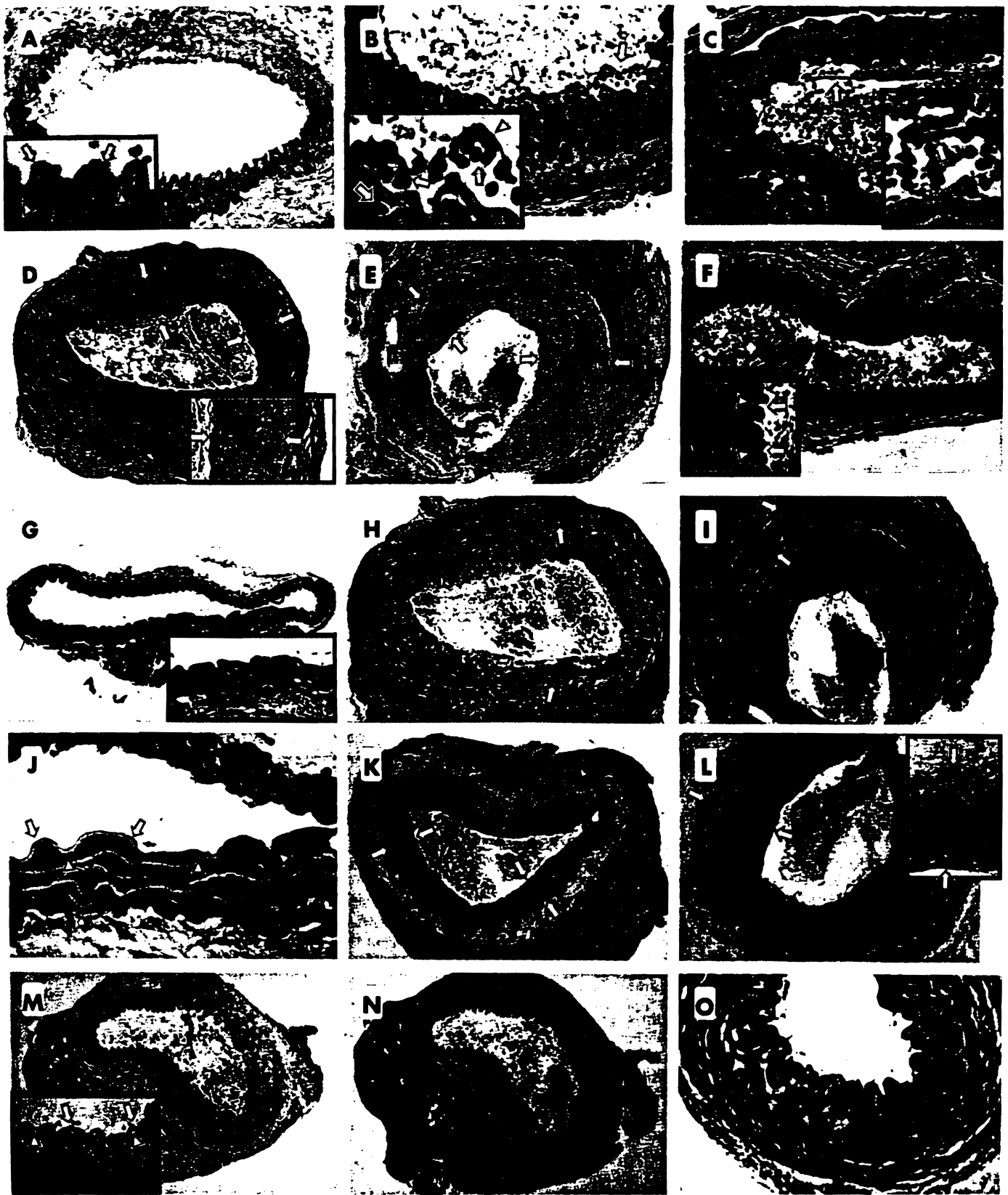


FIGURE 2. Cross-sections of aortic grafts harvested at various times after Tx across syngeneic (C57Bl/10→C57Bl/10) and allogeneic (C57Bl/10→C3H) mouse strain combinations. Hematoxylin and eosin-stained sections of transplanted allogeneic aortas (without prior OLTx) at days 0 (A), 6 (B), 10 (C), 30 (D), and 50 (E) after Tx. The onset (B) and resolution (C) of ACR, followed by the development of progressively worsening CR (D and E), is distinct. Contrarily, hematoxylin and eosin-stained sections of syngeneic grafts at day 50 after Tx (F) display normal vascular morphology. Verhoeff-van Gieson stained (for elastic membranes) sections of allogeneic aortas (without prior OLTx) at days 0 (G), 30 (H), and 60 (I) after Tx. Note the intact internal elastic limiting membrane on day 0 (G) with its progressive

Histopathological and Immunohistochemical Analysis

Syngeneic (C3H→C3H) AOTx. Grafts were harvested at various times after Tx for ascertainment of histopathological abnormalities. Although most of the samples obtained at days 4, 6, and 10 exhibited minimal edema of the media, this resolved by day 20 after Tx. However, despite these changes in the media, the integrity of the intima and the overlying endothelium (Fig. 2F) were preserved in grafts harvested at various times after Tx. More important, cellular infiltration was not discerned in any of the sections examined, and α -sMA⁺ cells were not visualized in the intima of the syngeneic grafts, a finding comparable with that observed in native aortas.

Allogeneic (C57Bl/10→C3H) AOTx without prior OLTx. To rule out abnormalities uniquely associated with postsurgical ischemia, aortic allografts were harvested immediately after revascularization (day 0), and their morphology was compared with that of native aortas. No microscopic aberration was evidenced in the endothelium (Fig. 2A, inset, arrows), which rested on an unaltered layer of the internal elastic limiting membranes. Staining for elastic fibers (by Verhoeff van Gieson's stain) demonstrated the presence of an intact internal elastic limiting membrane (Fig. 2G). More important, unlike that in the media, no α -sMA⁺ cells were observed in the intima (Fig. 2J), a finding consistent with that in the native aorta.

However, by day 6 after Tx, there was incontrovertible evidence for cellular rejection underscored by massive intimal infiltration of mononuclear cells (Fig. 2B, inset) with minimal invasion of the media and adventitia. Without exogenous immunosuppression, cellular infiltration underwent self-resolution such that by day 10 after Tx, the presence of mononuclear cells was barely discernible in the intima of the vessel (Fig. 2C). There was, nevertheless, evidence for minor residual damage as a result of acute cellular rejection (ACR) indicated by patchy endothelial cell denudation and necrosis (Fig. 2C, inset).

Over the next few days, histopathological abnormalities pathognomonic of ACR abated only to be supplanted by day 30 with changes characteristic of posttransplant arteriosclerosis (Fig. 2, D, H, and K). There was evidence for diffuse and concentric intimal thickening (Fig. 2D, inset), primarily a result of marked proliferation of α -sMA⁺ cells (Fig. 2K). Additionally, patchy destruction of the internal elastic limiting membrane (Fig. 2H) and initiation of intimal deposition of fibrous tissue and collagen was evident. It is noteworthy that this progressively worsening lesion resulted in gradual occlusion of the vascular lumen (Fig. 2, I and L), which was primarily a result of incessant proliferation of α -sMA⁺ cells and collagen deposition in the intima (Fig. 2, I and L).

Allogeneic (C57Bl/10→C3H) AOTx with prior OLTx. To ascertain whether prior induction of DST would attenuate

the development of posttransplant vasculopathy, we performed an orthotopic transplant of an allogeneic (B10) liver 30 days before AOTx. This decision was based on our previous demonstration that across virtually all MHC-disparate mouse strain combinations, orthotopically transplanted livers were spontaneously accepted without the need for exogenous immunosuppression (22). More important, this phenomenon was associated universally with stable long-term establishment of multilineage donor cell chimerism and induction of DST. Similar to that observed in syngeneic but unlike that in allogeneic grafts, the morphology of the transplanted aorta obtained from the liver donor (B10) strain animals when harvested at days 4, 6, and 10 after Tx exhibited no evidence of mononuclear cell infiltration and endothelial cell denudation and necrosis. Furthermore, there was no evidence of histopathological changes distinctive of CR in aortic allografts procured at up to 60 days after Tx (or 90 days after OLTx; Figure 2, M, N, and O). To ascertain whether this liver-induced protection is indeed donor specific, we transplanted third party (BALBc/ByJ) aortic allografts, all of which underwent self-limiting acute cellular crisis, which preceded the development of changes characteristically witnessed in posttransplant arteriopathy (data not shown).

DISCUSSION

Despite the advent of potent immunosuppressive agents, the development of posttransplant arteriosclerosis still remains a significant cause for delayed organ allograft dysfunction (1-3, 6, 7). Although the etiopathology of CR has not yet been fully elucidated, it is believed to be multifactorial (5-7); ischemia-reperfusion injury (28), donor age, histoincompatibility (29), and cytomegalovirus infection (30) have been implicated. Additionally, the intensity and frequency of ACR have also been shown to be directly correlated to the severity of posttransplant vasculopathy, suggesting an immune etiology (8, 9, 31, 32). The latter argument has been substantiated further by observations in rodents, in whom prior induction of DST has been shown to mitigate the subsequent development of CR (11-16).

Studies in humans have also yielded similar observations. Keenan et al. (17) have reported that the presence of microchimerism and the establishment of donor-specific hyporesponsiveness was associated with lower incidence of obliterative bronchiolitis (OB) in lung allotransplant recipients. These findings have been corroborated by Reinsmoen et al. (18), who showed that in lung allograft recipients exhibiting donor-specific hyporesponsiveness who were 2-8.5 years after Tx, no OB was in evidence. On the contrary, 9 of 17 (53%) patients who were responsive to donor antigens in *in vitro* proliferative assays developed OB (18). Similar observations have also been made in long-term renal allograft recipients (19). In our prospective clinical trial of concomitant donor

thickening (arrows) and destruction by day 60 after Tx (I). The progressive intimal thickening evidenced in previous images was largely a result of proliferation of α -sMA⁺ cells as can be distinguished by immunohistochemical staining of cross-sections of allogeneic aorta (without prior OLTx) at days 30 (K) and 50 (L) after implantation. No α -sMA⁺ structures were evident in aortas obtained immediately after Tx (J). When aortic allografts from C57Bl/10 mice were transplanted into C3H recipients that had previously (30 days earlier) received OLTx of a donor-strain type, no evidence of CR was witnessed as is depicted in hematoxylin and eosin (M)- and Verhoeff-van Gieson (N and O)-stained sections obtained at days 20 (M), 30 (N), and 60 (O) after AOTx. Magnification, $\times 100$ (A, D, E, F, G, H, I, K, L, M, and N); > 200 (B and C); $\times 400$ (O); $\times 1000$ (J). Inset, $\times 1000$ except in D and L ($\times 400$). Please note that these are original magnification; any variations introduced by photo processing have been disregarded.

bone marrow infusion and organ allotransplantation, we have also documented increased incidence of CR in contemporaneously accrued non-marrow-augmented lung transplant recipients as compared with that of the study (marrow-augmented) patients (33).

Although these foregoing observations have underscored the pivotal role for allogeneic immune responses (among others) in the development of CR, the cellular and molecular events responsible for this ominous outcome have not, however, been precisely elucidated. This latter fact, combined with the unavailability of an effective therapeutic regimen, has compounded clinical management of organ allograft recipients, in whom the diagnosis of CR is associated frequently with an undesirable outcome.

The relative paucity of cellular and molecular probes in rats limits the utility of this species for more explicit studies. It is for this reason that murine models of posttransplant arteriosclerosis, in whom this limitation does not exist, be considered for such analyses. Heterotopic cardiac allotransplantation in mice is perhaps an appropriate model to study the evolution of CR (16). However, the perioperative use in this model of immunosuppressive therapy to promote graft acceptance greatly restricts the ability to study acute phase events, which are generally considered to predispose to the eventual development of posttransplant arteriosclerosis (31). In a similar manner, morphological changes in the mouse model of heterotopic respiratory airways allotransplantation are quite divergent from those observed in human lung transplant recipients, thus greatly limiting its usefulness (34).

We report here the evolution of CR in a mouse model of aortic allotransplantation, which similar to that in rats (35), undergoes spontaneously resolving ACR. Lymphocytic infiltration in the subendothelial space of the intima and the media was observed during the first week after Tx. However, by days 8–10 after Tx, infiltration markedly decreased such that by day 20, there was little or no evidence for residual postinflammatory tissue damage. In addition, at this stage, no endothelial denudation but minimal myointimal proliferation was discernible. It was of interest that no immunosuppressive therapy was required for resolution of ACR and subsequent allograft acceptance.

However, by day 30 after Tx, morphological features of CR indistinguishable from those in humans were evident. These included diffuse and concentric luminal narrowing, patchy destruction of internal elastic limiting membrane, and extensive intimal thickening as a result of marked proliferation of α -sMA⁺ smooth muscle cells. It was of interest that, at this stage, no fibrous tissue and/or collagen deposition was noticeable in the thickened intima. This progressively worsening lesion resulted in massive occlusion of the vessel by day 120 after Tx. No morphological aberrations developed in syngeneic grafts during the course of follow-up, further substantiating the hypothesis that allogeneic immune responses play a seminal role in the development of CR.

Having verified that the histopathological changes in allotransplanted mouse aortas are in consonance with those witnessed in clinical posttransplant vasculopathy, we proceeded to ascertain the effect of prior induction of DST on the subsequent development of CR. For this purpose, we elected to perform OLTx, which in addition to being spontaneously accepted has also been shown to impart to the recipient a

state of DST (22). Thirty days after OLTx, when DST has been established, the recipients were challenged with either donor (B10) or third-party (BALBc/ByJ) aortic allografts. Although third-party grafts developed (by day 30 after implantation) changes reminiscent of CR, aortic allografts from donor-strain animals were morphologically indistinguishable from syngeneic grafts or normal aortas when examined during the course of follow-up (up to 120 days after Tx). In conclusion, given its morphological and developmental similarities to posttransplant vasculopathy in clinical organ allograft recipients, we strongly advocate the use of aortic allotransplantation in mice as a model of choice for detailed study of the pathogenesis of CR.

Acknowledgments. The authors acknowledge the assistance of Jo Harnaha and Margie Sigafos for the preparation of the manuscript.

REFERENCES

1. Kirkman RL, Strom TB, Weir MR, Tilney NL. Late mortality and morbidity in recipients of long-term renal allografts. *Transplantation* 1982; 34: 347.
2. Kramer MR. Bronchiolitis obliterans following heart-lung transplantation. *Respir Med* 1994; 88: 9.
3. Paul LC, Häyry P, Foegh M, Dennis MJ, Mihatsch M, Larsson E, Fellström B. Diagnostic criteria for chronic rejection/accelerated graft atherosclerosis in heart and kidney transplants: joint proposal from the fourth Alexis Carrel Conference on chronic rejection and accelerated arteriosclerosis in transplanted organs. *Transplant Proc* 1993; 25: 2022.
4. Wiesner RH, Ludwig J, Van Hoek B. In: Paul LC, Solez K, eds. *Organ transplantation: long-term results*. New York: Marcel Dekker, 1992: 197.
5. Paul LC, Fellström B. Chronic vascular rejection of the heart and kidney: have rational treatment options emerged? *Transplantation* 1992; 53: 1169.
6. Häyry P, Isoniemi H, Yilmaz S. Chronic allograft rejection. *Immunol Rev* 1993; 134: 33.
7. Paul LC. Immunobiology of chronic renal transplant rejection (Review). *Blood Purif* 1995; 13: 206.
8. Tilney NL, Whitley WD, Diamond JR, Jupiec-Weglinski JW, Adams DH. Chronic rejection: an undefined conundrum. *Transplantation* 1991; 52: 389.
9. Foegh ML. Chronic rejection: graft arteriosclerosis. *Transplant Proc* 1990; 22: 119.
10. Cramer DV, Chapman FA, Wu GD, Harnaha JB, Qian S, Makowka L. Cardiac transplantation in the rat. II. Alteration of the severity of donor graft arteriosclerosis by modulation of the host immune response. *Transplantation* 1990; 50: 554.
11. Shin YT, Adams DH, Wyner LR, Akalin E, Sayegh MH, Karnovsky MJ. Intrathymic tolerance in the Lewis-to-F344 chronic cardiac allograft rejection model. *Transplantation* 1995; 59: 1647.
12. Demetris AJ, Murase N, Ye Q, Falvo FHF, Richert C, Saad R, Pham S, Duquesnoy RJ, Zeevi A, Fung JJ, Starzl TE. Analysis of chronic rejection and obliterative arteriopathy: possible contributions of donor antigen presenting cells and lymphatic disruption. *Am J Pathol* 1996; 150: 563.
13. Orloff M, DeMara EM, Coppage ML, Leong N, Fallon MA, Sickel J, Suo XJ, Prehn Jordan SC. Prevention of chronic rejection and graft arteriosclerosis by tolerance induction. *Transplantation* 1995; 59: 282.
14. Murase N, Starzl TE, Tanabe M, Fujisaki S, Miyazawa H, Ye Q, Delaney CP, Fung JJ, Demetris AJ. Variable chimerism, graft-versus-host disease, and tolerance after different kinds of cell and whole organ transplantation from Lewis to Brown Norway rats. *Transplantation* 1995; 60: 158.

15. Matsumura Y, Marchevsky A, Zuo XJ, Kass RM, Matloff JM, Jordan SC. Assessment of pathological changes associated with chronic allograft rejection and tolerance in two experimental models of rat lung transplantation. *Transplantation* 1995; 59: 1509.
16. Larsen CP, Elwood ET, Alexander DZ, Ritchie SC, Hendrix R, C Tucker-Burden C, Cho HR, Aruffo A, Hollenbaugh D, Linsley PS, Winn KJ, Pearson TC. Long-term acceptance of skin and cardiac allografts after blocking CD40 and CD28 pathways. *Nature* 1996; 381: 434.
17. Keenan RJ, Zeevi A, Banas R, Sommers E, Spichty K, Yousem S, Kocova M, Trucco M, Starzl TE, Griffith B. Microchimerism is associated with a lower incidence of chronic rejection after lung transplantation. *J Heart Lung Transplant* 1994; 13: A9.
18. Reinsmoen NL, Jackson A, McSherry C, Ninova D, Wiesner R, Kondo M., Krom RAF, Hertz MI, Bolmoan RM III, Matas AJ. Organ-specific patterns of donor antigen-specific hyporeactivity and peripheral blood allogeneic microchimerism in lung, kidney, and liver transplant recipients. *Transplantation* 1995; 60: 1546.
19. Reinsmoen NL, Matas AJ. Evidence that improved late renal transplant outcome correlates with the development of in vitro donor antigen-specific hyporeactivity. *Transplantation* 1993; 55: 1017.
20. Sun H, Valdivia LA, Subbotin V, Aitouche A, Fung JJ, Starzl TE, Rao AS. An improved surgical technique for the establishment of a murine model of aortic transplantation. *Microsurgery* (in press).
21. Koulack J, McAlister VC, Giacomantonio CA, Bitter-Suermann H, MacDonald AS, Lee TD. Development of a mouse aortic transplant model of chronic rejection. *Microsurgery* 1996; 16: 110.
22. Qian S, Demetris AJ, Murase N, Rao AS, Fung JJ, Starzl TE. Murine liver allograft transplantation: tolerance and donor cell chimerism. *Hepatology* 1994; 19: 916.
23. Qian S, Fung JJ, Demetris AJ, Ildstad ST, Starzl TE. Orthotopic liver transplantation in the mouse. *Transplantation* 1991; 52: 562.
24. Billingham RE, Brent L, Medwar PB. Actively acquired tolerance of foreign cells. *Nature* 1953; 172: 603.
25. Bradbury R, Gordon KC. Connective tissue and stain. In: Bancroft JD, Stevens A, eds. *Theory and practice of histological techniques*. New York: Churchill Livingstone Press, 1990: 119.
26. Skalli O, Ropraz P, Trzeciak A, Benzouana G, Gillessen D, Gabbiani G. A monoclonal antibody against a smooth muscle actin: a new probe for smooth muscle differentiation. *J Cell Biol* 1986; 103: 2787.
27. Skalli O, Pelte MF, Pecllet MC, Gabbiani G, Gugliotta P, Bussolati G, Ravazzola M, Orci L. α -smooth muscle actin, a differentiation marker of smooth muscle cells, is present in microfilamentous bundles of pericytes. *J Histochem Cytochem* 1989; 37: 315.
28. Yilmaz S, Paavonen T, Häyry P. Chronic rejection of rat renal allografts. II. The impact of prolonged ischemia time on transplant histology. *Transplantation* 1992; 53: 823.
29. Pirsch JD, D'Alessandro AM, Sollinger HW, Hoffman RM, Roeder E, Voss BJ, Lorentzen D, Knechtle SJ, Reed A, Kayayoglu M. The effect of donor age, recipient age and HLA match on immunologic graft survival in cadaver renal transplant recipients. *Transplantation* 1992; 53: 55.
30. Keenan RJ, Lega ME, Dummer JS, Paradis IL, Dauber JH, Rabinowich H, Yousem SA, Hardesty RL, Griffith BP, Duquesnoy RJ. Cytomegalovirus serologic status and post-operative infections correlated with risk of developing chronic rejection after pulmonary transplantation. *Transplantation* 1991; 51: 433.
31. Basadonna GP, Matas AJ, Gillingham KJ, Payne WD, Dunn DL, Sutherland DE, Gores PF, Gruessner RW, Najarian JS. Early versus late acute renal allograft rejection: impact on chronic rejection. *Transplantation* 1993; 55: 993.
32. van Sasse JL, van der Woude FJ, Thorogood J. The relation between acute vascular and interstitial renal allograft rejection and subsequent chronic rejection. *Transplantation* 1995; 59: 1280.
33. Rao AS, Fontes P, Iyengar A, Shapiro R, Dodson F, Corry R, Pham S, Jordan M, Zeevi A, Rastellini C, Aitouche A, Egidi F, Gritsch HA, Reyes J, Fung JJ, Starzl TE. Augmentation of chimerism with perioperative donor bone marrow infusion in organ transplant recipients: a forty-four month follow-up. *Transplant Proc* 1996; 29: 1184.
34. Hertz MI, Jessurun J, King MB, Savik SK, Murray JJ. Reproduction of the obliterative bronchiolitis lesion after heterotopic transplantation of mouse airways. *Am J Pathol* 1993; 142: 1945.
35. Mennander A, Paavonen T, Häyry P. Intimal thickening and medial necrosis in allograft arteriosclerosis (chronic rejection) are independently regulated. *Arterioscler Thromb* 1993; 13: 1019.

Received 14 April 1997.

Accepted 26 June 1997.