

2223

# Textbook of **CRITICAL CARE**

FIFTH  
EDITION

2005

## **Mitchell P. Fink, MD**

Professor and Chair  
Department of Critical Care Medicine  
Watson Professor of Surgery  
University of Pittsburgh School of Medicine  
Pittsburgh, Pennsylvania

## **Edward Abraham, MD**


Roger Sherman Mitchell Professor of Pulmonary and Critical Care Medicine  
Vice Chair, Department of Medicine  
Head, Division of Pulmonary Sciences and Critical Care Medicine  
University of Colorado Health Sciences Center  
Denver, Colorado

## **Jean-Louis Vincent, MD, PhD**

Professor of Intensive Care  
Faculty of Medicine  
Free University of Brussels  
Head, Department of Intensive Care  
Erasmé University Hospital  
Brussels, Belgium

## **Patrick M. Kochanek, MD**

Director, Safar Center for Resuscitation Research  
Professor and Vice Chairman, Department of Critical Care Medicine  
Professor of Pediatrics and Anesthesiology  
University of Pittsburgh School of Medicine and  
Children's Hospital of Pittsburgh  
Pittsburgh, Pennsylvania



## Chapter 236

# INTESTINAL AND MULTIPLE ORGAN TRANSPLANTATION

George Mazariegos • Jorge Reyes • Kareem Abu-Elmagd • Thomas E. Starzl

### KEY POINTS

1. Causes of short gut syndrome involve both surgical causes (e.g., volvulus, necrotizing enterocolitis, mesenteric thrombosis) or functional causes such as motility disorders (e.g., intestinal pseudo-obstruction) and absorptive insufficiencies such as microvillous inclusion disease.
2. Indications for intestinal transplantation approved by Medicare in 2000 include (1) evidence of liver dysfunction or failure; (2) loss of major venous access; (3) frequent central line–related sepsis; (4) recurrent episodes of severe dehydration despite intravenous fluid management.
3. Recipient operations should be tailored to the specific indications of each patient and include isolated intestinal transplantation, combined liver-intestinal transplantation, and multivisceral transplantation, including the stomach.
4. Immunosuppression for intestinal transplantation is based on tacrolimus and steroids. Current modifications in intestinal transplantation include pretreatment of the recipient with antilymphocyte antibody such as antithymocyte antibody to allow for the elimination of maintenance steroid use postoperatively.
5. Sepsis after intestinal transplantation should prompt a rapid examination for technical reasons (e.g., intra-abdominal abscess, anastomotic dehiscence), immunologic events (rejection may lead to bacterial translocation), or Epstein Barr virus–mediated viremia or post-transplant lymphoproliferative disease.

The evolution of intestinal transplantation has distantly paralleled that of kidney and liver transplantation. Although the introduction of cyclosporin A made other organ transplants a clinical reality, success with intestinal transplantation remained almost nonexistent due to a high incidence of graft loss from rejection, infection, and technical complications.<sup>1</sup>

The experimental studies on intestinal transplantation reported by Lillehei and colleagues in 1959 as an isolated organ graft in dogs,<sup>2</sup> and subsequently by Starzl and colleagues with the multivisceral graft in dogs (liver, stomach, pancreaticoduodenal complex, small and large intestine)<sup>3</sup> supported a

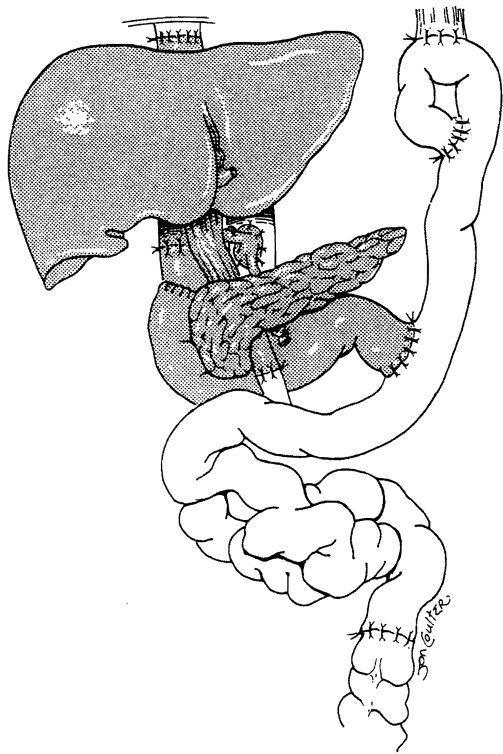
unidirectional paradigm of transplantation and immunology similar to that found after bone marrow transplantation.<sup>4</sup> These experiments predicted that graft-versus-host disease would be precipitated by immunocytes in lymphoid cell–rich intestinal allografts differing from the recipient across a major histocompatibility complex barrier.<sup>5</sup>

Numerous attempts at clinical intestinal transplantation performed after 1964 under azathioprine/steroid and subsequently cyclosporine immunosuppression were largely unsuccessful. In 1987, a 3-year-old girl received a multivisceral abdominal graft that included the stomach, duodenum, pancreas, small bowel, colon, and liver; she survived for 6 months with good intestinal graft function.<sup>6</sup> A modified application of this operation was the transplantation of a “cluster” of organs in 1989.<sup>7</sup> The allograft consisted of the liver and the pancreaticoduodenal complex (Fig. 236-1). Viability of varying lengths of intestine with these clusters was proven, as was evidence of regeneration after severe rejection-induced injury. The inclusion of the liver in this type of graft was believed to protect the other transplanted organs from the same donor against rejection.<sup>8,9</sup> A recipient of a liver and small bowel graft treated by Grant and associates survived for more than 1 year.<sup>10</sup> Until 1990, there were only two survivors of isolated cadaveric intestinal grafts.<sup>11,12</sup>

The new immunosuppressant, tacrolimus (FK506, Prograf), permitted successful transplantation of human intestinal grafts (alone or as part of a multivisceral graft).<sup>13,14</sup> Successful intestinal transplantation then led to appreciation of the two-way paradigm of transplantation immunology<sup>15</sup>; it was postulated that two cell populations (one of recipient and the other of donor origin) reciprocally modulate immune responsiveness (host-versus-graft and graft-versus-host), including the induction of mutual nonreactivity with consequent organ allograft acceptance.<sup>16</sup>

### INDICATIONS

Causes of loss of intestinal function may be acute (e.g., necrotizing enterocolitis, volvulus, mesenteric thrombosis) or chronic (e.g., Crohn’s disease, radiation enteritis). Diseases associated with loss of intestinal function also can be divided into surgical (short gut) and nonsurgical causes. Patients with surgical causes generally suffer from loss of bowel length after resections for atresia, infarction (e.g., due to volvulus, vascular catastrophes, necrotizing enterocolitis), or strictures and fistulas as with Crohn’s disease. With nonsurgical causes of intestinal failure, the anatomic length and gross morphology of the intestine may be normal.



**FIGURE 236-1.** Cluster allograft (shaded portion), including the liver, pancreas, and duodenal segment of small intestine. (From Starzl TE, Todo S, Tzakis A, et al: Abdominal organ cluster transplantation for the treatment of upper abdominal malignancies. *Ann Surg* 1989;210:374-386.)

XIV  
2002

Nonsurgical causes of intestinal failure include motility disorders (e.g., intestinal pseudo-obstruction, Hirschsprung's disease), absorptive problems (e.g., microvillus inclusion disease), polyposis syndromes, and "incarcerating" desmoid tumors. Table 236-1 lists the indications for transplantation in the case experience at the University of Pittsburgh.

Total parenteral nutrition (TPN) is the standard of care for patients who are unable to maintain a normal nutritional state by use of the gastrointestinal tract alone (intestinal failure).<sup>17</sup> Transplantation of the intestine either alone or accompanied by other intra-abdominal organs (liver, stomach, pancreas) may be beneficial in patients who fail this therapy. The stability and duration of TPN support is variable, and

failure of TPN can be manifested by complications such as infection, metabolic disorders, difficulty with vascular access (from extensive venous thrombosis), and liver cirrhosis with end-stage liver disease.

The decision regarding allograft composition focuses on the integrity of the remaining gut and other abdominal organs, both functionally and anatomically. Guidelines used in substantiating the need for concomitant liver replacement in these intestinal transplantation candidates are biochemical dysfunction (hyperbilirubinemia, transaminase abnormalities, hypoalbuminemia, and coagulopathy), pathologic processes (fibrosis or cirrhosis on liver biopsy), and the clinical presence of portal hypertension as manifested by hepatosplenomegaly, ascites, or esophageal varices and portal hypertensive gastroenteropathy. Patients deficient in protein S, protein C, and antithrombin III (liver-derived anticoagulation proteins) may be candidates for a combined liver–small intestine allograft in the absence of clinical liver disease.<sup>18</sup> Recipients lacking these substances develop diffuse thromboses within the splanchnic system and undergo transplantation for mesenteric venous hypertension rather than for intestinal failure. Patients with motility disorders or neoplasms that involve extensive lengths of the gastrointestinal tract are also candidates for replacement of this entire system (see Table 236-1).

In October 2000, the Center for Medicare and Medicaid Services approved intestinal, combined liver-intestine, and multivisceral transplantation as a standard of care for patients with irreversible intestinal failure who could no longer be maintained with total parenteral nutrition. Based on the available data, the approved indications for intestinal transplantation included (1) impending liver failure, as manifested by elevated circulating levels of liver enzymes, clinical findings (splenomegaly, varices, coagulopathy), history of stomal bleeding, or hepatic cirrhosis on biopsy; (2) loss of major venous access defined as more than two thromboses in the great vessels (subclavian, jugular, and femoral veins); (3) frequent central line–related sepsis consisting of more than two episodes of systemic sepsis per year, or one episode of line-related fungemia associated with septic shock or acute respiratory distress syndrome; (4) recurrent episodes of severe dehydration despite intravenous fluid management.<sup>19,20</sup>

**ABDOMINAL VISCERAL PROCUREMENT**

The safe procurement of multiple visceral organs, either en bloc or as separate components, hinges on a few fundamental precepts. Conceptually, the focus is to isolate and cool the organs, thus preserving their vascular and parenchymal anatomy and function. Multivisceral en bloc retrieval, including the stomach, duodenum, pancreas, liver, and small intestine, is the parent operation, and the assembled components have been likened by Starzl and colleagues to a large clump of individual grapes from the whole.<sup>21</sup> An appreciation of the fundamental strategy of multivisceral organ retrieval leads to an understanding of the lesser variant operations<sup>22</sup>—that is, procurement of the liver, small intestine, and the liver and small intestine together.

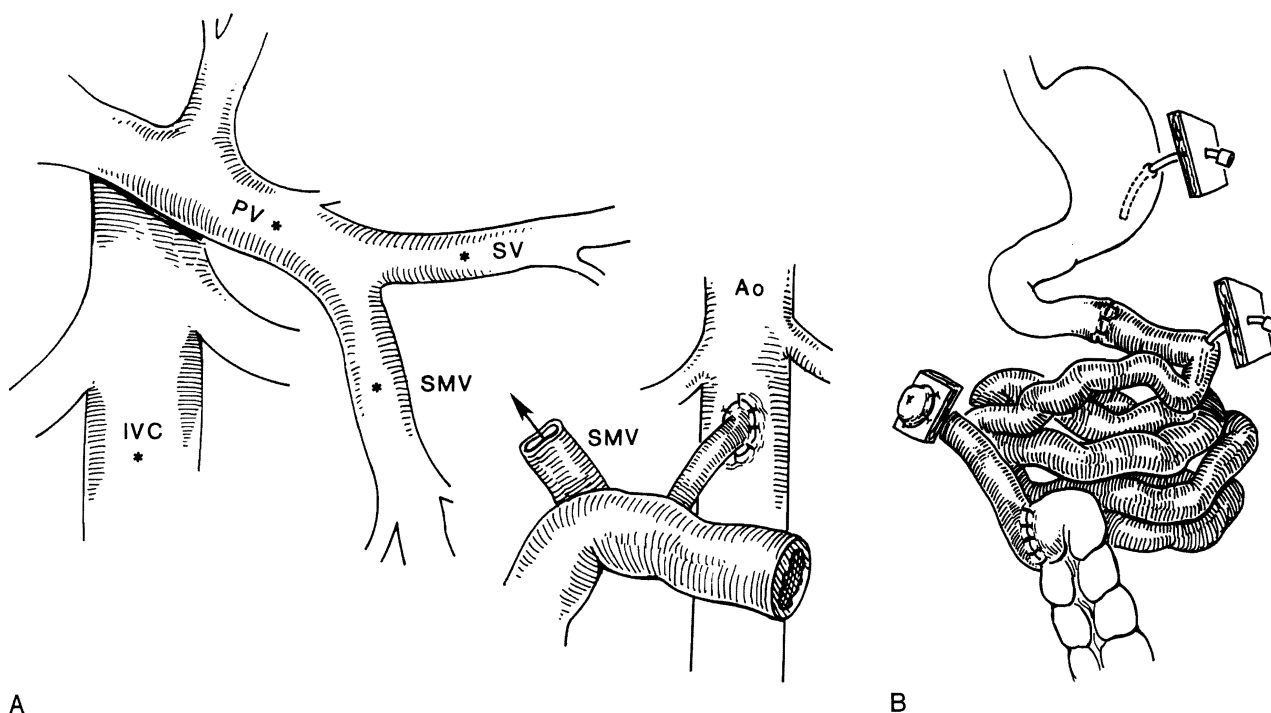
**RECIPIENT OPERATIONS**

Most patients who need intestinal or multiorgan replacements have had multiple forays into the abdominal cavity

**TABLE 236-1. INDICATIONS FOR COMPOSITE AND ISOLATED INTESTINAL TRANSPLANTATION AT THE UNIVERSITY OF PITTSBURGH AND CHILDREN'S HOSPITAL OF PITTSBURGH**

Pediatric Patients	Adult Patients
Volvulus	Trauma
Gastroschisis	Superior mesenteric artery thrombosis
Necrotizing enterocolitis	Crohn's disease
Intestinal atresia	Desmoid tumor
Pseudo-obstruction	Volvulus
Microvillus inclusion disease	Familial polyposis
Intestinal polyposis	Gastrinoma
Hirschsprung's disease	Budd-Chiari disease
Trauma	Intestinal adhesions
	Pseudo-obstruction
	Inflammatory bowel disease
	Radiation enteritis

A  
FIG  
bow  
veir  
  
for  
me  
the  
the  
of t  
  
abc  
pla  
tion  
Seq  
tra:  
11  
anc  
Rec  
17  
has  
2.2  
res:  
has  
lar:  
  
rec  
or  
cor  
ope  
the  
fin:  
of  
  
ISC  
  
In  
nar  
dis  
is



**FIGURE 236-2.** (A) Arterialization and potential venous drainage options of the isolated small intestine allograft. (B) Illustration of an isolated small bowel graft; the distal ileal chimney allows easy access to bowel mucosa. Ao, aorta; IVC, inferior vena cava; PV, portal vein; SMV, superior mesenteric vein; SV, splenic vein. (From Reyes J, Bueno J, Kocoshis S, et al: Current status of intestinal transplantation in children. *J Pediatric Surg* 1998;33:243-254.)

for intestinal resections, lengthening procedures, and treatment of complications. This results in volume contraction of the abdominal cavity and severe adhesions. Consequently, the organs of the donor usually need to be smaller than those of the recipient to ensure proper abdominal closure.

In an effort to maximize organ utilization and improve abdominal closure in children undergoing intestinal transplantation, intestinal reduction with or without liver reduction has been used. For example, between July 2002 and September 2003, 31 children received consecutive intestinal transplants consisting of 14 isolated intestinal transplants, 11 liver/intestinal transplants, 4 multivisceral transplants, and 2 modified multivisceral transplants without liver. Reduction of the liver and intestine has been carried out in 17 of 31 cases (55%). A mean length of 1.3 meters of bowel has been reduced in these children, leaving a mean of 2.2 meters (range: 1.1 to 3 meters). Based on these initial results, a donor weight to recipient weight ratio of up to 4:1 has been a practical guideline to use in selection of donors larger than recipients.

Previous operations may complicate the removal of the recipient's organs, especially if cirrhosis, portal hypertension, or inferior vena caval thromboses are present. All of these conditions can be sequelae of the original disease or of prior operations. The recipient operation consists of removal of the failed organs with exposure of the vascular anatomy and, finally, allograft implantation. Following is a brief description of the salient features of the recipient operations.

### ISOLATED SMALL BOWEL

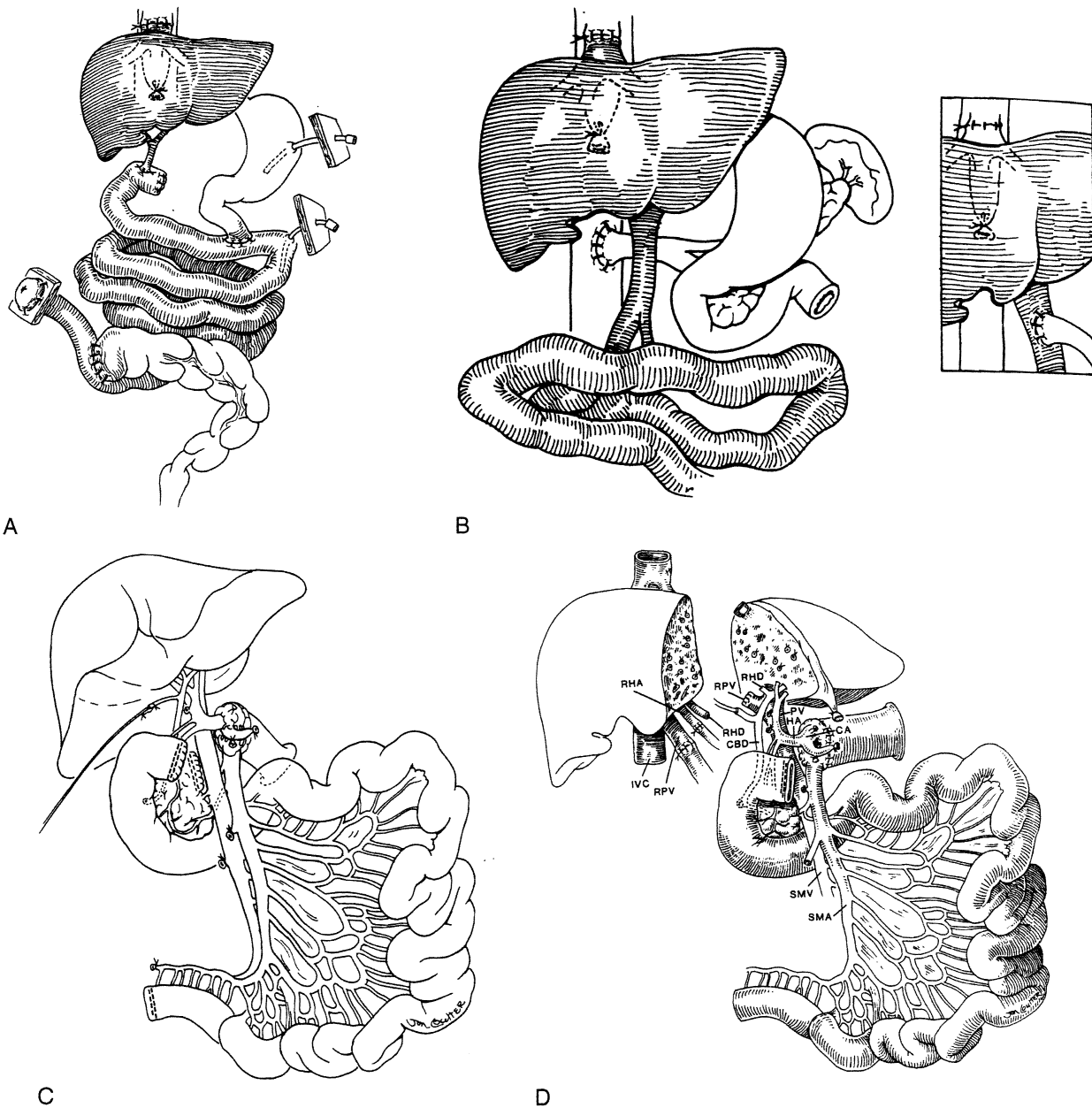
In cases of surgical short gut, the proximal and distal remnants of the intestine are identified; when there is functional disease or neoplasm, the recipient's diseased small intestine is removed. The superior mesenteric artery of the donor

bowel is sewn to the infrarenal aorta, and the donor superior mesenteric vein is anastomosed to the recipient portal vein, superior mesenteric vein, splenic vein, or inferior vena cava (Fig. 236-2A). The anastomosis can be facilitated by the use of an interposition venous graft. Reperfusion of the intestinal graft is effected after the vascular anastomoses. Intestinal continuity is completed with proximal and distal anastomoses, and access to the ileum for endoscopic examination is provided by a temporary chimney ileostomy (Fig. 236-2B).<sup>23</sup>

*Cold ischemia time* refers to the time between procurement and implantation of the allograft and should be less than 10 hours. *Warm ischemic time* for the allograft (sewing-in time) is about 30 minutes and is also a determinant of preservation injury to the intestine. In an attempt to reduce graft dysmotility, a segment of large intestine was included in 32 allografts. This practice was abandoned after 1994.

### LIVER-SMALL BOWEL

Liver and small intestine are removed in these patients, but the remainder of the foregut (stomach, duodenum, pancreas) is retained. When possible, the liver is removed with the retrohepatic vena cava preserved in situ ("piggyback").<sup>24</sup> After the enterectomy, the composite allograft is implanted by anastomosing the suprahepatic vena cava of the donor (including the hepatic veins) end-to-side to the recipient's vena cava. The donor infrahepatic vena cava can then be ligated (Fig. 236-3A). The double arterial stem of the celiac and superior mesenteric arteries (using the Carrel patch technique) are connected to the infrarenal aorta (using an aortic conduit or iliac artery homograft), followed by graft reperfusion. Since the axial stem of the portal vein between the donor organs is removed intact, all that is required for the completion of portal flow is attachment of the portal vein of the remnant foregut in the recipient to the intact portal stem



**FIGURE 236-3.** (A) Modification of the liver/small intestinal allograft. (B) Combined liver-small intestinal allograft. Systemic portacaval shunt, or recipient portal vein to donor portal vein shunt (inset) allows venous outflow of retained pancreas and stomach from recipient. (C) Composite liver and intestine graft with preservation of the duodenum in continuity with the graft jejunum and hepatic biliary system. The allograft pancreas is transected to the right of the portal vein. (D) In situ split liver graft, maintaining the left lateral segment in continuity with the hepatic hilus and duodenum, with transection of allograft pancreas. (B, from Reyes J, Bueno J, Kocoshis S, et al: Current status of intestinal transplantation in children, *J Pediatric Surg* 1998;33:243-254; C, from Abu-Elmagd K, Reyes J, Todo S, et al: Clinical intestinal transplantation: New perspectives and immunologic considerations. *J Am Coll Surg* 1998;186:512-527; D, from Reyes J, Fishbein T, Bueno J, et al: Reduced sized orthotopic composite liver-Intestinal allograft: Rationale and in situ split technique in an initial experience. *Transplantation* 1998;66:489-492.)

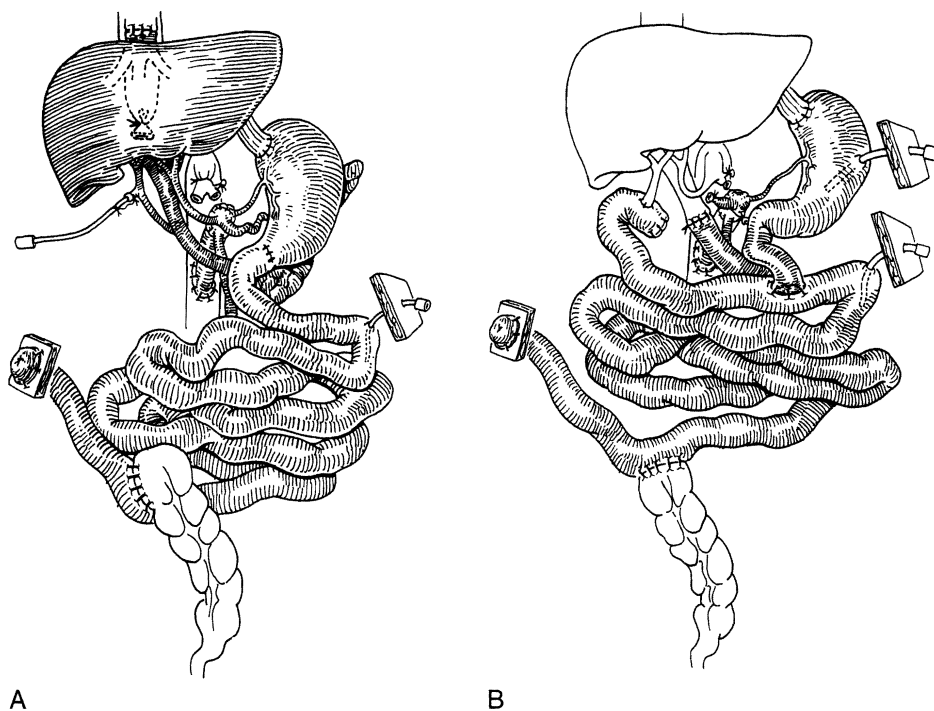
of the donor. This may not be possible, however, because of a size discrepancy or difficult anatomic relationships between donor and recipient portal veins. In this case, a permanent portacaval shunt is performed (Fig. 236-3B). The intestinal anastomoses are then completed with a proximal jejunojunction, ileocolostomy, a temporary distal ileostomy, and a Roux-en-Y biliary anastomosis. To avoid a biliary anastomosis (with its potential for complications), a modification of the original "cluster" allograft, as depicted in Figure 236-1, has been applied to the liver-small bowel allografts.<sup>25</sup> In the modification, the allograft duodenum remains in continuity with the allograft biliary system and

varying lengths of allograft jejunum/ileum (Fig. 236-3C). In one such graft, a reduced segment of allograft liver (the left lateral segment) was successfully used after an in situ split was performed to overcome a donor-recipient size mismatch in a critically ill pediatric recipient (Fig. 236-3D).

#### MULTIVISCERAL TRANSPLANTATION

After abdominal exenteration and exposure of the retroperitoneal aorta and inferior vena cava, the multivisceral graft (Fig. 236-4A) is connected by its vascular attachments. First, the suprahepatic attachment is completed, then the

**FIGURE 236-4.** Diagrams of multivisceral donor organs: complete multivisceral (A), modified multivisceral (B). (From Reyes J, Bueno J, Kocoshis S, et al: Current status of intestinal transplantation in children. *J Pediatr Surg* 1998;33:243-254.)



infrahepatic vena caval connections (or “piggyback” to the skeletonized recipient vena cava) are performed. Finally, the arterioaortic anastomosis (using an aortic interposition homograft) is completed. The recipient’s portal vein and its inflow organs (gastrointestinal tract, pancreas, and liver) are removed with the enterectomy. The donor portal vein retains its continuity via the liver in the procurement of the allograft; thus, no portal vein anastomosis is required in this procedure. Patients with a normal native liver can receive a modified multivisceral procedure that excludes the allograft liver as part of the composite of organs. In this modification, portal venous return is directed into the recipient’s portal vein (Fig. 236-4B).

Restoration of intestinal continuity requires an esophago-gastric anastomosis and a coloenteric anastomosis with the distal ileum allograft. Initially, the patient also receives an ileostomy. Takedown of the ileostomy can be performed after several months, when oral nutrition is consistently adequate, a stable immunosuppressant regimen has been achieved, and there is no further need for frequent endoscopic surveillance.

**IMMUNOSUPPRESSION**

Traditionally, immunosuppression for intestinal transplantation has been based on tacrolimus and corticosteroids. Over time, however, the immunosuppressive regimen has evolved. From 1990 to 1995, the regimen used tacrolimus and corticosteroids for induction and maintenance. Induction therapy with cyclophosphamide was used from 1995 through 1997. Daclizumab was used for induction from 1998 through 2001. Preconditioning with Thymoglobulin during induction therapy and tacrolimus monotherapy (without steroids) after transplantation have been in use since 2001 (Table 236-2). The therapeutic principles of the current immunosuppression regimen are pretreatment of the recipient with a lymphocyte-depleting agent to precondition the recipient, and then use

of the lowest possible amount of post-transplant immunosuppression to prevent frequent rejection episodes yet allow for the tolerogenic effect of the preconditioning to occur.<sup>26</sup>

In this management strategy, Thymoglobulin is given as an initial one-time dose of 5 to 10 mg/kg intravenously in adults or as 5 to 10 mg/kg in divided doses of 3 mg/kg pre-perfusion and 2 mg/kg post-perfusion in children. Subsequent to preconditioning, administration of tacrolimus is begun, using the enteral route. The target steady-state whole blood level of tacrolimus is between 15 and 20 ng/mL. Using the preconditioning regimen as outlined above has allowed the elimination of routine steroid use. Methylprednisolone is given as a bolus at perfusion and as premedication for the lymphocyte-depleting agent, but this drug is not used routinely. The dose is 1 g for adults and 10 mg/kg for children. The goal of tacrolimus monotherapy has been achieved without an increase in rejection rates and with the resulting ability to achieve spaced dosing of tacrolimus to once a day, or even every other day. Prostaglandin E<sub>1</sub> (Prostin) is administered at 0.003 to 0.009 µg/kg/min for the first 5 postoperative days. This drug is given for its beneficial effects on renal perfusion as well as its

**TABLE 236-2. INTESTINAL TRANSPLANTATION: IMMUNOSUPPRESSION BY ERA**

Years	Drug	Cases, n
1990-1995	Tacrolimus/steroids	70
1995-1997	Tacrolimus/steroids /cyclophosphamide	24
1997-1998	Tacrolimus/steroids	13
1998-2001	Tacrolimus/steroids /daclizumab	62
2002-2003	Thymoglobulin preconditioning protocol	81
TOTAL		250

Pre 2002 Base-line Immunosuppression = tacrolimus + prednisone + azathioprine (n = 16), mycophenolate mofetil (n = 2), or sirolimus (n = 16)

prevention of microvascular thrombosis, a key pathophysiologic event in acute cellular rejection and procurement injury. Rejection is treated with optimization of tacrolimus levels, supplemental corticosteroids, and, if necessary, OKT3.

## POSTOPERATIVE CARE

Recipients of multivisceral, liver–small bowel, or cluster grafts commonly suffer from severe liver failure. Therefore, the care with respect to pulmonary function, infection surveillance, and liver graft function is similar to that provided for routine liver transplant recipients. Recipients of isolated small bowel transplants who have stable liver function have a lesser preoperative medical acuity.

## VENTILATORY MANAGEMENT

Extubation often can be accomplished within 48 hours of transplantation. Unusual circumstances, such as graft malfunction, sepsis, inability to close the abdominal wall, or severe preoperative hepatic failure, may prevent early extubation. Since the operation may be long (8 to 18 hours) and the patients are often in a weakened nutritional state preoperatively, a careful assessment of weaning parameters is required. Incisional pain, ascites, and pleural effusions may compromise ventilation and the ability to cough. Other factors that can contribute to respiratory dysfunction include muscle wasting and malnutrition, partial or complete paralysis of the right hemidiaphragm,<sup>27</sup> and increased intra-abdominal volume with compression of the thoracic cavity due to a discrepancy between the size of the donor and the recipient. These patients often require low doses of intravenous narcotics, repeated thoracentesis and paracentesis, and supplemental extensive respiratory therapy if they are to avoid the need for reintubation. Patients may require tracheostomy, because of the need for prolonged ventilatory support, although this is unusual in children. Rarely, severe rejection of an isolated small intestine allograft with systemic venous drainage into the inferior vena cava is heralded by respiratory insufficiency and a clinical picture consistent with acute respiratory distress syndrome.

## RENAL FUNCTION

Most intestinal transplant candidates have some degree of renal dysfunction due to multiple episodes of infection, the toxic effects of antibiotics, and hepatic dysfunction. Early after transplantation, there is significant accumulation of interstitial fluid into the graft, lungs, and peripheral tissues; this accumulation peaks at 48 to 72 hours. Extensive volume shifts into the transplanted bowel (related to preservation injury) and marked ascites production (related to mesenteric lymphatic leakage) lead to intravascular volume depletion that can exacerbate the nephrotoxicity of tacrolimus and certain antibiotics. Continuous central venous pressure measurement, often for weeks after transplantation, provides important information for maximizing graft perfusion and preserving the integrity of the kidneys. Two children have had inclusion of an allograft kidney with their primary intestine transplant, and one long-term pediatric survivor required sequential kidney transplantation.

## INFECTION CONTROL

Recipients of isolated or composite small bowel grafts receive prophylactic, broad-spectrum intravenous antibiotics. Any history of recent nosocomial infections before transplantation should be addressed with the administration of appropriate specific antibiotics. Colonizing organisms growing from enterocutaneous fistulous tracts should be treated perioperatively.

All recipients are given a pre- and postoperative “cocktail” of oral nonabsorbable antibiotics every 6 hours for 2 weeks; the mixture includes amphotericin B, gentamicin, and polymyxin E and is intended to achieve selective bowel decontamination.<sup>28</sup> Surveillance stool cultures are performed weekly. When organisms grow in quantitative cultures to greater than  $10^8$  colony-forming units/mL in the presence of signs of systemic sepsis or ongoing acute cellular rejection of the allograft, specifically directed intravenous antibiotics are added to the regimen to treat the presumed translocating organisms. Evidence of translocation most commonly occurs during episodes of acute rejection, when the mucosal barrier of the allograft has been immunologically damaged; however, it also can be seen with enteritis associated with Epstein-Barr virus infection.<sup>29</sup>

The antiviral prophylactic strategy has evolved during the past several years. The currently recommended regimen includes a 2-week course of intravenous ganciclovir with concomitant administration of cytomegalovirus-specific hyperimmune globulin (Cytogam).<sup>30</sup> The dose for ganciclovir is 5 mg/kg twice daily i.v. The dose for Cytogam is 150 mg/kg i.v. in donor CMV (+) to recipient CMV (–) mismatch 2, 4, 6, and 8 weeks after transplant and 100 mg/kg/dose i.v. at 12 and 16 weeks after transplant. Oral administration of trimethoprim-sulfamethoxazole (80 mg p.o. three times weekly) is used for the lifetime of the patient as prophylaxis against *Pneumocystis carinii* pneumonia.

## NUTRITIONAL SUPPORT

Full nutritional support is initially provided via standard total parenteral nutrition. This is tapered gradually as oral or enteral feedings (via gastric or jejunal tube) are advanced. Tube feedings are initiated with isotonic formulas tailored to meet specific patient requirements. Most patients do not voluntarily eat adequate amounts early after the operation. Resistance to resumption of oral feedings is particularly notable in pediatric recipients.<sup>31</sup> Therefore, enteral supplementation is required when the intestinal tract becomes functional. This management must be individualized, since the simplicity of an uneventful post-transplant course may suddenly change with any surgical or immunologic complication.

## ASSESSMENT OF GRAFT STATUS

A judgment of the anatomic and functional integrity of the graft begins in the operating room. The normal intestine is pink and nonedematous and occasionally demonstrates contractions. Alterations from this appearance can be observed in the operating room and in the ileal stoma postoperatively.

Surveillance for intestinal graft rejection focuses on clinical evaluation and gross morphologic examination of

the stoma and the distal ileum. Frequent routine enteroscopic surveillance has been shown to be the most reliable tool for the early diagnosis of intestinal rejection.<sup>32</sup> Endoscopic evaluations are performed routinely twice a week through the allograft ileostomy; upper endoscopy is performed when clinical changes are not elucidated by distal allograft evaluation. Grossly, the bowel reacts to insults in nonspecific ways with edema, cyanosis, congestion, and increased stomal output; these alterations should signal a broad differential diagnosis that includes preservation injury, systemic sepsis, rejection, and enteritis.

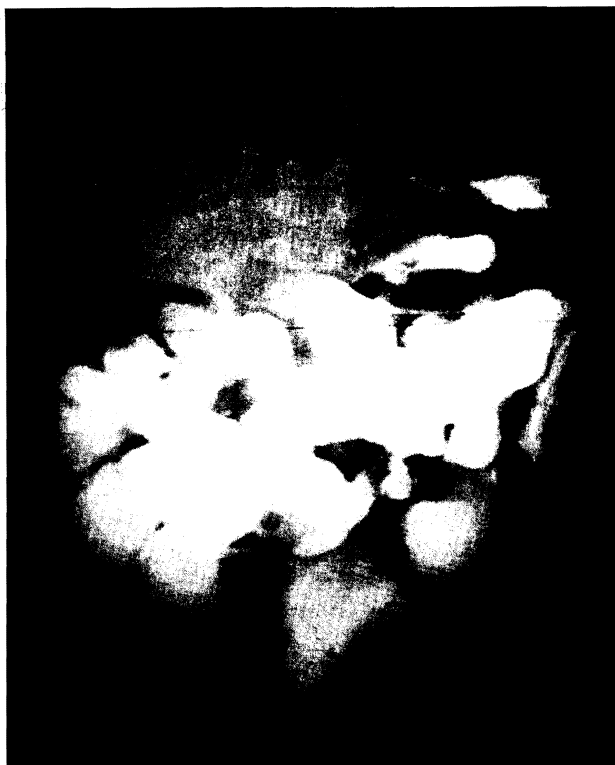The stomal output is assessed for volume, consistency, and the presence of reducing substances, which can be seen in the event of rejection, bacterial overgrowth, or malabsorption. Typically, within the first week of implantation, stomal output is 1 to 2 L/day (for adults) or 40 to 60 mL/kg/day (for children) of clear, watery effluent. If these volumes are exceeded and no significant pathology is present, paregoric, loperamide, pectin, somatostatin, or oral antibiotics can be used singly or in combination to control the diarrhea. The presence of blood in the stool is always an ominous sign and indicates rejection until proven otherwise.

Serum tests are important in assessing injury to the liver (bilirubin concentration, aspartate aminotransferase concentration, and alanine aminotransferase concentration), but no such tests exist for intestinal grafts. Serum markers for nutritional adequacy and anabolic status (circulating levels of transferrin, albumin, and retinoic acid) are of limited value, whereas specific tests of the absorptive ability of the graft are good measures of overall function. Assessment of small bowel function relies on absorption studies of D-xylose and tacrolimus and on the quantitation of fat in the stool. Most patients develop satisfactory absorption curves for D-xylose within the first postoperative month, and absorption continues to improve over time. Abnormal results obtained after 1 month always should prompt an aggressive search for underlying pathology, especially rejection. The maintenance of satisfactory tacrolimus whole blood trough levels of 15 to 20 ng/mL on oral therapy alone is a good indicator of adequate absorption. In our patients, evidence of good absorptive function occurs at a mean of 28 days after transplantation and tends to be delayed longer in recipients of multivisceral grafts.<sup>33</sup> The excretion of fat in the stool has been abnormal in almost all patients. However, clinical steatorrhea has not been a problem.

Radiologic evaluations by standard barium gastrointestinal examination are valuable in assessing mucosal pattern and motility and are performed routinely after the first postoperative week. A normal mucosal pattern is expected. Intestinal transit time is around 2 hours. Intestinal graft rejection, when mild, can be suspected when evidence of mucosal edema exists. Severe rejection, with exfoliation of the mucosa, ablates the normal mucosal pattern and can be seen as segments of "tubulized" intestine and strictures (Fig. 236-5).

## COMPLICATIONS

Before a description of the variety of potential complications, it is important to have a general perspective on the care of these patients. Comprehensive management of intestinal recipients requires a multidisciplinary approach by surgeons, anesthesiologists, nurses, critical care physicians, pathologists, and a host of internal medicine subspecialists. Easy access to diagnostic and therapeutic modalities, including mechanical



**FIGURE 236-5.** Severely damaged allograft intestine in a recipient of a liver-small bowel after multiple episodes of rejection. Diffuse tubulized gut, strictures, and significant distention of the native duodenum are seen.

ventilation, hemodialysis, bronchoscopy, gastrointestinal endoscopy, thromboelastography, percutaneous cholangiography, ultrasonography, invasive and noninvasive contrast radiography, and sophisticated hemodynamic monitoring systems is paramount.

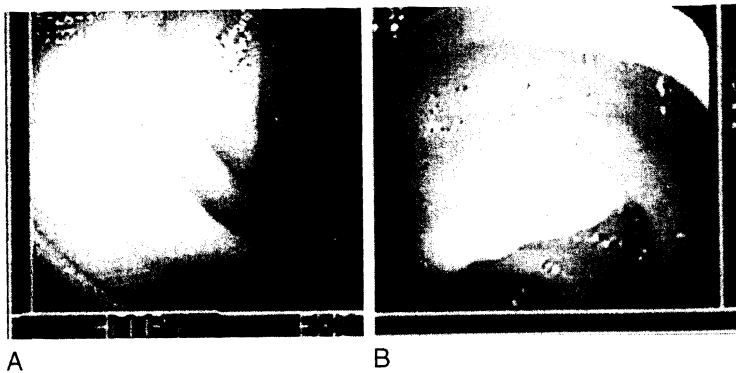
More important than the above, however, is vigilance about patient care and attention to detail, on the part of both physicians and nurses. Problems in these patients can originate from a multiplicity of sources. Several assumptions can be made in these patients based on our experience:

1. Preoperative deterioration of physical performance status predisposes to various organ system failures that persist in the postoperative period even though allograft function may be acceptable.
2. Transplant cases are labor-intensive and patients require aggressive respiratory therapy, nutritional and antibiotic support, fluid management, and nursing care, often for prolonged periods in the intensive care unit.
3. Immunotherapy doses in patients with multivisceral transplants tend to be higher than in patients with single organ transplants.
4. The majority of patients develop episodes of infection and rejection after transplantation, often concomitantly. Any subjective complaints or objective abnormalities should be vigorously pursued until a cause is found or until the symptoms resolve.

## GRAFT REJECTION

Intestinal allograft rejection can manifest as an array of symptoms that include fever, abdominal pain, distention,





**FIGURE 236-6.** (A) Normal endoscopic appearance of transplanted small intestine. (B) Moderate acute cellular rejection of an intestinal allograft demonstrating diffuse edema and focal erythema.

nausea, vomiting, and a sudden increase in stomal output. The stoma may become edematous, erythematous, and friable. Gastrointestinal bleeding can occur in cases of severe uncontrollable rejection in which ulcerations and sloughing of the intestinal mucosa occur. Septic shock or acute respiratory distress syndrome may develop. Bacterial or fungal translocation can occur during intestinal allograft rejection due to disruption of the intestinal mucosal barrier. Gut decontamination must be instituted during these episodes.<sup>34</sup>

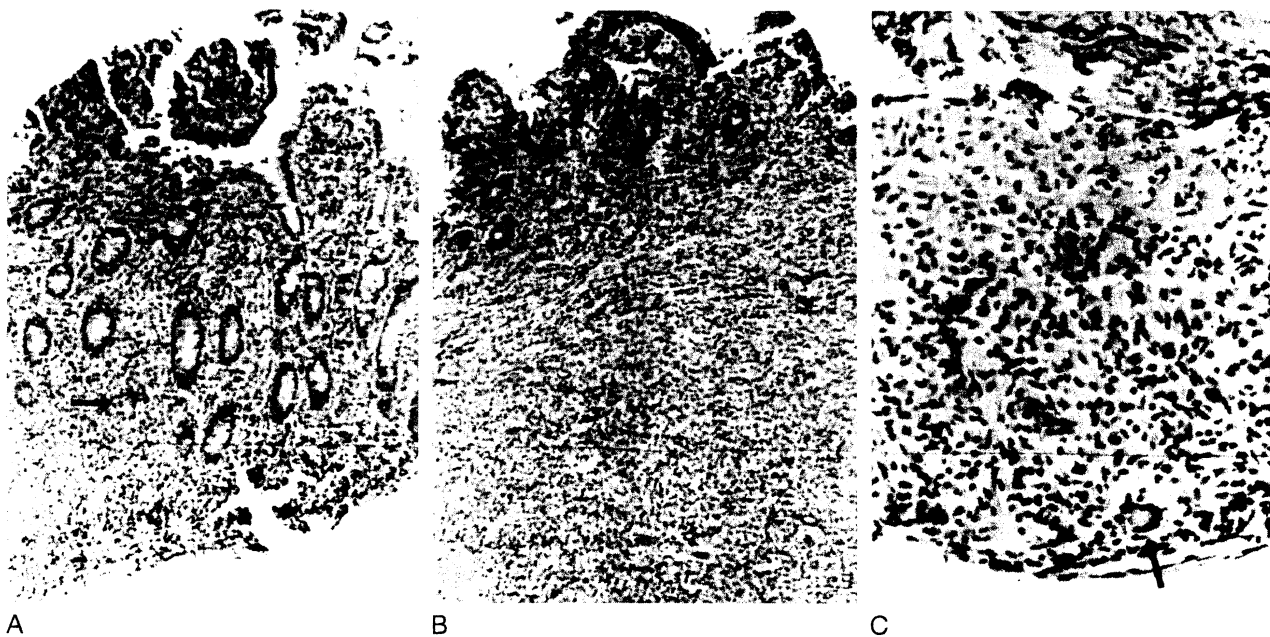
Endoscopically, the transplanted intestinal mucosa loses its velvety appearance. It may become hyperemic or dusky as well as hypoperistaltic. Erythema may be focal or diffuse. The mucosa becomes friable, and diffuse ulcerations appear (Fig. 236-6).

Histologically, there is variable presence of edema in the lamina propria and villous blunting. However, the presence of mononuclear cell infiltrates and cryptitis with apoptosis and regeneration are necessary for establishing the diagnosis of rejection. Neutrophils, eosinophils, and macrophages may be seen traversing the muscularis mucosa.<sup>35,36</sup> The degree of epithelial and crypt cell damage varies. Complete mucosal sloughing and crypt destruction are seen in grafts with

severe rejection. The mucosal surface is partially replaced by inflammatory pseudomembranes and granulation tissue (Fig. 236-7). This may precipitate continuous blood loss as well as intermittent septic episodes from the damaged intestine.

Chronic rejection has been observed in patients with persistent intractable rejection episodes. Clinically progressive weight loss, chronic diarrhea, intermittent fever, and gastrointestinal bleeding dominate the presentation. Histologically, villous blunting, focal ulcerations, epithelial metaplasia, and scant cellular infiltrate are present on endoscopic mucosal biopsy specimens. Full-thickness intestinal biopsies show obliterative thickening of intestinal arterioles.

Historically, the incidence of acute intestinal allograft rejection during the first 90 days after transplantation was 92% in isolated small bowel recipients and 66% in recipients of composite grafts, suggesting that the liver is "protective" for the intestine, as is seen experimentally.<sup>37,38</sup> Interestingly, the incidence of acute liver allograft rejection in recipients of composite grafts is 43%, which is similar to that seen after isolated liver transplantation.<sup>30</sup> However, the rate of acute rejection has steadily decreased to current levels of approximately 30% with the use of a preconditioning protocol.



**FIGURE 236-7.** Acute cellular rejection. (A) Endoscopic biopsy sample obtained 14 days after transplantation showed widening of the lamina propria with increased mononuclear cells, which were often cuffed around small vessels and infiltrating the crypt epithelium (*arrow*; hematoxylin and eosin, original magnification  $\times 140$ ). (B) The reaction was more intense in biopsies that contained lymphoid nodules and where blastogenesis, focal ulcerations, congestion, and neutrophil plugging of capillaries were also seen (moderate acute cellular rejection; hematoxylin and eosin, original magnification  $\times 140$ ). (C) Uncontrolled acute rejection eventually resulted in widespread mucosal destruction; the mucosa was replaced by granulation tissue. Note the overlying inflammatory pseudomembrane (*arrow*; hematoxylin and eosin, original magnification  $\times 350$ ).

Lower overall immunosuppression has subsequently allowed a concomitant reduction in Epstein-Barr virus and cytomegalovirus disease, especially in pediatric recipients.

Mild graft rejection is treated initially with intravenous methylprednisolone, and with a methylprednisolone taper in cases of moderate rejection. The tacrolimus trough levels in whole blood should reach 15 to 25 ng/mL, with the drug administered by either the oral or the intravenous route. OKT3 is used when rejection has progressed with a steroid taper; however, it should be entertained as the initial therapeutic agent in cases of severe mucosal injury and crypt damage. The use of cyclophosphamide/mycophenolate mofetil induction therapy or bone marrow augmentation had no beneficial effect on the frequency of rejection.<sup>30,36</sup>

## POSTOPERATIVE HEMORRHAGE

Coagulopathy is more often an intraoperative problem that relates to liver dysfunction, qualitative and quantitative platelet defects, and fibrinolysis.<sup>38</sup> Intraoperative bleeding is further promoted by vascularized adhesions due to previous surgery and portal hypertension. Temporary graft reperfusion coagulopathy mediated by plasminogen activators from the graft may occur.<sup>39</sup> Efforts are made to normalize these global aspects of coagulation by the end of the operative procedure so that in the absence of liver dysfunction, the coagulopathy is usually minor in the postoperative period. Postoperative intra-abdominal bleeding is most often a technical problem, arising from vascular anastomoses or extensive, raw peritoneal surfaces. Certainly, coagulation parameters should be normalized, if postoperative bleeding occurs; if bleeding is proved, the origin should be presumed to be surgical and managed as such by early reexploration.

## BILIARY COMPLICATIONS

Continuity of the biliary axis is surgically re-established in multivisceral grafts. Correspondingly, these grafts can develop biliary system-related surgical complications (i.e., leaks and obstructions).

Biliary leaks usually occur within the first 2 weeks after transplantation and may herald their presence with bilious drainage from the abdominal wound or drains or merely with unexplained sepsis. The response to external bilious drainage should be immediate exploration with surgical revision of the biliary dehiscence. In the case of unexplained sepsis in any intestinal transplant recipient, all surgical anastomoses should be radiographically inspected (with percutaneous cholangiography), and if leakage is suspected, they should be revised. There is no place for percutaneous diversion of biliary or intestinal leakage in these patients, since both wound healing and antimicrobial immunity are impaired by multimodal immunotherapy.

Biliary obstruction generally follows an anastomotic stricture and is a delayed complication, but any clinical picture that resembles cholangitis or biliary obstruction should be followed with cholangiography to prove patency of the biliary tree, regardless of the timing after transplantation.

## VASCULAR COMPLICATIONS

Major arterial thrombosis is a disastrous complication that leads to massive necrosis of the organs correspondingly

supplied. Elevation of hepatic enzymes and pallor of the intestinal stoma are accompanied by clinical deterioration, fulminant sepsis, and hepatic coma. Isolated small bowel grafts can be removed with the expectation of patient recovery, but in patients with composite grafts, the event is usually fatal unless early retransplantation can be performed. Patency of the arteries can be rapidly confirmed with Doppler ultrasonographic examination.

Since the superior mesenteric vein-portal vein axis is preserved in the composite grafts, venous outflow thrombosis is less likely to occur in these recipients. Isolated small bowel grafts have an anastomosis of these veins that can occlude. Ascites, stomal congestion, and mesenteric infarction are the ultimate result.

Neither of these problems is associated with subtle clinical signs; diagnosis should be prompt and obvious. In our series, isolated thrombosis of the hepatic artery has occurred in a pediatric recipient of a liver-small bowel graft, with consequent hepatic gangrene. This patient required retransplantation of the liver component of the graft, even though a full liver-small bowel graft was desirable.

Incomplete obstruction of major inflow or outflow vessels may be suspected on biopsy or based on clinical and laboratory evidence of organ dysfunction. Contrast vascular radiographic studies are confirmatory, and the correction is surgical or, in some cases, with balloon dilatation.

## GASTROINTESTINAL COMPLICATIONS

Gastrointestinal bleeding after intestinal transplantation is an ominous sign that requires prompt attention. Rejection or infection are the most probable causes and should be immediately diagnosed or ruled out on the basis of enteroscopic biopsy results. The diagnosis of rejection relies not only on histologic evidence but also on the endoscopic appearance of the mucosa (Figs. 236-6 and 236-7). Bleeding from ulcerated Epstein-Barr virus- or cytomegalovirus-induced lesions can be easily differentiated by gross endoscopic examination. Empiric therapy for rejection is not acceptable.

Leakage of either the proximal or the distal gastrointestinal anastomosis can occur in any recipient, but it is more common in pediatric patients than in adults. Any fresh surgical margin, including the native duodenal and colonic stumps and gastrostomy sites, are vulnerable to poor wound healing and subsequent leakage. Presentation is often dramatic (florid sepsis), and confirmation is with radiologic contrast imaging. Surg revision, evacuation of peritoneal soilage, and often reexploration are required to eliminate the contamination effectively. Again, sepsis without an obvious source should prompt the performance of contrast studies to document the integrity of all gastrointestinal anastomoses; if the findings are inconclusive, diagnostic laparotomy is indicated.

Atony of the native stomach and pylorospasm that produce early satiety or vomiting are common and self-limiting. The evolution of motility patterns in the denervated allograft intestine is not fully understood. Hypermotility of the allograft intestine occurs early after transplantation; in the absence of rejection or bacterial overgrowth, it can be controlled with agents such as paregoric, loperamide, or pectin. Sudden changes in intestinal motility, particularly when accompanied by abdominal distention and vomiting in the case of decreased motility, should initiate a search for rejection.

## INFECTIONS

Historically, frequency of infectious complications has been high and was responsible for the significant morbidity and mortality initially reported after intestinal transplantation. The high incidence of serious infectious complications was due in part to the relatively high level of immunosuppression required to maintain the graft in these intestinal recipients. Other predisposing factors include the severity of the preoperative liver failure as well as the presence of intra-abdominal, pulmonary, or intravenous line-induced sepsis before transplantation. Also, technically more difficult transplantation procedures with increased operative time, transfusion requirements, and likelihood of reexploration reflect the advanced disease of these patients. Recipients of small bowel grafts have the lowest incidence of complications because of the more elective nature of their operations.

Although current immunosuppressive modifications have decreased the incidence of life-threatening septic complications, the recognition and management of infection is still an important component of the care of these patients. Infectious pathogens include bacteria, fungi, and viruses. Infections are related (in order of frequency) to intravenous lines, the abdominal wound, deep abdominal abscesses, peritonitis, and pneumonia. Bacterial translocation in grafts damaged by rejection illustrates the need for concomitant antirejection and antimicrobial therapy and is a frequent source of infection.

Of the bacterial pathogens, staphylococcal and enterococcal species are common, whereas gram-negative rods usually accompany polymicrobial infections. Not uncommonly, separate sources of infection occur simultaneously, or mixed infections from the same source are present. This leads to multiple antibiotic regimens and sets the stage for the development of resistant organisms. Panresistant enterococcal isolates are an increasing problem. Persistence of a physiologic hyperdynamic state in a patient being treated for proven infection should raise the suspicion of retained phlegmonous material in the abdomen or the possibility of rejection.<sup>40,41</sup>

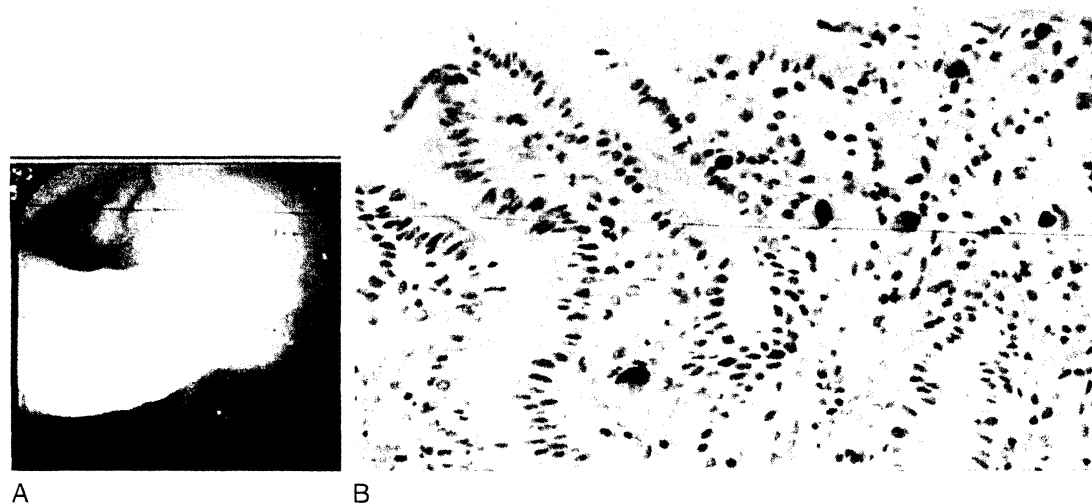
Fungal infections become problematic after heavy treatment for rejection, massive antibiotic usage, intestinal leaks, and multiple surgical explorations. The authors routinely

**TABLE 236-3. PEDIATRIC INTESTINAL TRANSPLANTATION: CYTOMEGALOVIRUS DISEASE BY ERA**

Year	Drug	Rate, %
1990-1995	Tacrolimus/steroids	23
1995-1997	Cyclophosphamide	56
1997-1998	Tacrolimus/steroids	11
1998-2001	Daclizumab	4
2002-2003	Thymoglobulin preconditioning protocol	5

employ low-dose amphotericin B prophylaxis in patients with these complications. Established fungal infections require long-term, full-dose antibiotic therapy and reduction of immunotherapy. All persistently septic recipients are potential candidates for moderation of immunosuppressant dosages, if no coexistent cellular rejection is present. However, complete withdrawal of immunosuppression has been impossible in this recipient population owing to a high incidence of rebound rejection, which then mandates augmentation of immunotherapy.

Historically, clinical cytomegalovirus infection has occurred in 36% of intestinal graft recipients and often involves the allograft intestine. The current incidence of cytomegalovirus disease is approximately 5% (Table 236-3). Although the incidence and distribution of disease according to donor and recipient cytomegalovirus serologic status is similar in adults (44%) and children (31%), the clinical course is dramatically better in children. Successful clinical management has been accomplished in 88% of episodes using ganciclovir alone or ganciclovir in combination with cytomegalovirus-specific hyperimmunoglobulin. Immunosuppression is maintained at baseline and reduced only in the face of deteriorating clinical disease, thus decreasing the risk of rebound rejection.<sup>29</sup> A cytomegalovirus-positive donor graft transplanted into a cytomegalovirus-negative recipient is a significant risk factor for cytomegalovirus disease, but monitoring for pp65 antigenemia and preemptive therapy allow the successful use of cytomegalovirus-mismatched organs. Clinical presentation is generally enteritis of variable severity with focal ulcerations and bleeding (Fig. 236-8).



**FIGURE 236-8.** (A) Endoscopic appearance of cytomegaloviral enteritis is characterized by hyperemic erosions. (B) The diagnosis was confirmed histologically by the presence of characteristic inclusions, by staining for viral antigens, or both. Note the focal neutrophilic inflammation (immunoperoxidase for cytomegalovirus antigens, original magnification  $\times 350$ ).

**TABLE 236-4. PEDIATRIC INTESTINAL TRANSPLANTATION: PTLD BY ERA**

Year	Drug	Rate, %
1990-1995	Tacrolimus/steroids	44
1995-1997	Cyclophosphamide	19
1997-1998	Tacrolimus/steroids	33
1998-2001	Daclizumab	17
2002-2003	Thymoglobulin preconditioning protocol	5

Less commonly, respiratory syncytial virus, adenovirus, and parainfluenza virus infections occur in the pediatric population. All viral infections are opportunistic and have as a common denominator the need for aggressive treatment of rejection episodes in complicated patients with high Acute Physiologic and Chronic Health Evaluation (APACHE) scores.

Post-transplantation lymphoproliferative disease associated with Epstein-Barr virus occurs in 20% of patients, and children (27%) have traditionally been at a significantly higher risk than adults (11%). Presentation varies from totally asymptomatic observations at routine endoscopy to nonspecific intestinal and systemic symptoms to bleeding, lymphadenopathy, and tumors to fulminant disease. Risk factors other than age include the type of graft, splenectomy, and the use of OKT3. Therapy includes the reduction and withdrawal of immunosuppression, antiviral therapy using ganciclovir, acyclovir, and/or hyperimmunoglobulin, rituximab (anti-CD 20 monoclonal antibody), and chemotherapy. Rebound rejection is a significant contributor to mortality.<sup>31,37,42</sup> With current immunosuppressive practice, the post-transplant lymphoproliferative disease rate has decreased to less than 10% (Table 236-4).

**GRAFT-VERSUS-HOST DISEASE**

Skin changes consistent with graft-versus-host disease were diagnosed by histopathologic criteria and confirmed

by immunohistochemical studies visualizing donor cell infiltration into the lesions on two occasions or by flow cytometry detecting elevated donor cell chimerism in peripheral blood. One child died with hereditary IgG and IgM deficiency,<sup>43</sup> and one adult developed a complex chronic graft-versus-host disease in association with post-transplant lymphoproliferative disease. All other cases have been treated with optimization of immunosuppression and limited steroid therapy, if necessary.

**PRESENT STATUS AND FUTURE**

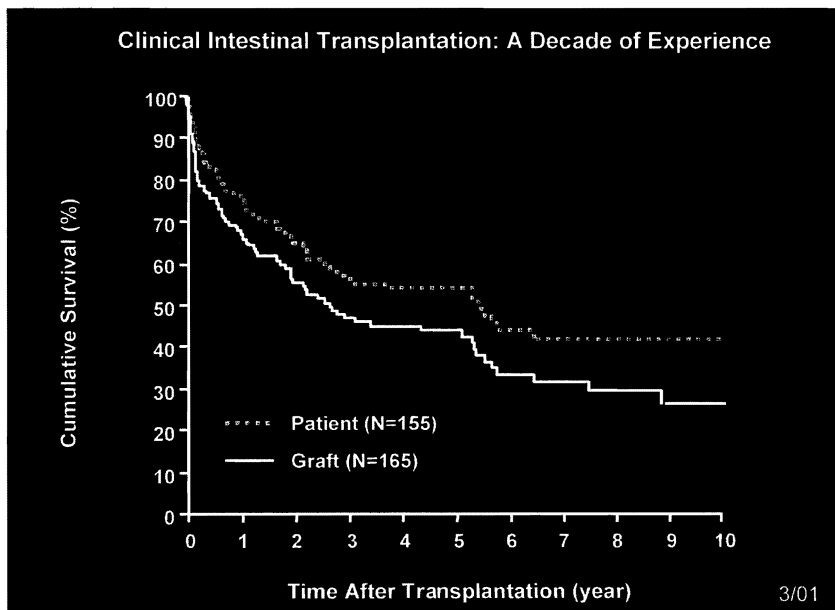
The causes of graft and patient loss are invariably multifactorial and complex. The evolution of technical and clinical management factors have improved outcome (Fig. 236-9). However, the interplay between the need for high levels of immunosuppression, the high incidence of rejection, and the opportunistic infections consequent to this remain the major stumbling block to further progress.

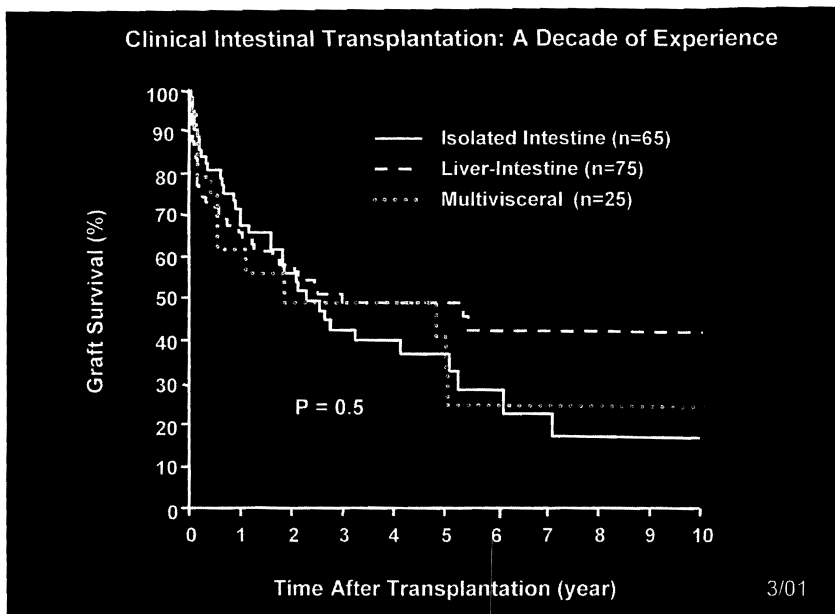
Accumulated experience has allowed the development of clinical and surgical strategies that benefit a very complex group of patients. Reserved optimism is taken in light of previous experience with intestinal transplantation, as well as the grim outcome for patients not transplanted. Nonetheless, the overall actuarial survival rate at 1 and 5 years is 72% and 48%, respectively, and full nutritional support has been achieved in 91% of surviving patients (see Fig. 236-5). Improved results have been achieved in the pediatric population between 2 and 18 years of age (65% at 5 years).<sup>37</sup>

The transplantation of the isolated intestinal graft provides better patient survival at all follow-up times (see Fig. 236-6). However, because of the higher incidence of rejection with this type of graft, the long-term outcome of all types of grafts (isolated intestine or composite grafts) is similar (Fig. 236-10) and is estimated to be about 50% at 5 years.<sup>31,37</sup>

Improved strategies for immunosuppression have lowered the morbidity rate of transplantation and the concurrent infection rate and may allow for improved survival in the current era of preconditioning with Thymoglobulin.

**FIGURE 236-9.** Patient and graft survival. (From Abu-Elmagd K, Reyes J, Bond G, et al: Clinical intestinal transplantation: A decade of experience at a single center. *Ann Surg* 2001;234:404-417.)





**FIGURE 236-10.** Kaplan-Meier survival of the three different types of intestinal allografts. (From Abu-Elmagd K, Reyes J, Bond G, et al: Clinical intestinal transplantation: A decade of a single center experience. *Ann Surg* 2001;234:404-417.)

Under the best of circumstances, the outlay of financial and time expenditures in composite and isolated small bowel transplant recipients is impressive. For best possible results, candidates who are nutritionally optimal and free of active infection should be selected. Donor organs should be discarded if they are less than perfect. Even with technically perfect operations, the managing physicians should expect a host of postoperative difficulties and be prepared to support these patients fully for an indefinite period of time. Managing the balance between excessive and inadequate immunosuppression in the face of potentially virulent infections, the pursuit of rejection and sources of infection, and maintenance of comprehensive critical care support are the most challenging tasks.

### ANNOTATED REFERENCES

Abu-Elmagd K, Bond G, Reyes J, Fung J: Intestinal transplantation: A coming of age. *Adv Surg* 2002;36:65.

*The development of intestinal transplantation, surgical techniques, and management are reviewed. Current results in adult intestinal transplantation are presented.*

Abu-Elmagd K, Fung J, Bueno J, et al: Logistics and technique for procurement of intestinal, pancreatic, and hepatic grafts from the same donor. *Ann Surg* 2000;232:680.

*Successful procurement of multiple organs from cadaveric donors cared for in the ICU is described. Increased utility of intestinal grafts is important to decrease waiting list time.*

Bueno J, Ohwada S, Kocoshis S, et al: Factors impacting the survival of children with intestinal failure referred for intestinal transplantation. *J Pediatr Surg* 1999;34:27.

*Timely referral of patients for consideration for intestinal transplantation is crucial for success. For example, this review documents the impact of jaundice at the time of presentation on mortality prior to transplantation.*

Reyes J, Mazariegos GV, Bond GM, et al: Pediatric intestinal transplantation: Historical notes, principles and controversies. *Pediatr Transplant* 2002;6:193.

*Although historical long-term survival is approximately 50%, advances in surgical, clinical, and immunosuppressive management since 1995 have improved pediatric patient survival to more than 70% in experienced centers.*

Starzl TE, Murase N, Abu-Elmagd K, et al: Tolerogenic immunosuppression for organ transplantation. *Lancet* 2003;361:1502.

*Recipient preconditioning with antithymocyte antibody and minimization of post-transplant immunosuppression are described as key principles in current management of a cohort of transplanted patients. Routine use of maintenance steroids has been eliminated in intestinal recipients using this approach.*

Tzakis AG, Kato T, Nishida S, et al: Preliminary experience with campath 1H (ClH) in intestinal and liver transplantation. *Transplantation* 2003;75:1227.

*Campath 1H in combination with low-dose tacrolimus immunosuppression was utilized for intestinal, multivisceral, and liver transplantation and allowed the avoidance of maintenance adjuvant-steroid treatment in the majority of patients.*